

Good Outcomes with the Intraventricular Vancomycin Therapy in a Patient with Ruptured Brain Abscesses

Abstract

Brain abscesses are associated with high morbidity and mortality rates. In particular, patients with intraventricular rupture of brain abscess (IVROBA) exhibit mortality rates up to 85%. Treatment options are lacking for IVROBA, once patients become refractory to intravenous antibiotics and surgical drainage. Limited data exist regarding the risks and benefits of intraventricular therapy in such a scenario. We report a patient with IVROBA, who deteriorated while on systemic antibiotics; once intraventricular vancomycin was employed, the patient demonstrated remarkable improvement without perceivable side effects. This case suggests that intraventricular vancomycin may be a safe, effective, and viable option for the treatment of IVROBA, especially for patients becoming refractory to systemic antibiotics.

Keywords: Brain abscess, intracerebral rupture of brain abscess, intraventricular vancomycin, ventriculitis

Introduction

Brain abscesses are associated with high morbidity and mortality rates.^[1] In particular, patients with intraventricular rupture of brain abscess (IVROBA) exhibit mortality rates up to 85%.^[1-6] Currently, standard treatment involves surgical drainage and intravenous (IV) antibiotics.^[1,4-6] Sparse articles have documented good outcomes associated with intraventricular antibiotics for patients refractory to systematic treatment;^[6-9] trialed antibiotics have included gentamicin, colistin, tobramycin, and ampicillin.^[6,7,9] In general, intraventricular vancomycin has predominantly been directed at ventriculitis and shunt infections;^[10-13] its use appears safe and effective.^[10,11] Only one article has described the administration of intraventricular vancomycin as a treatment for IVROBA.^[14] Given the paucity of literature, skepticism persists regarding the employment of intraventricular antibiotics specifically for the treatment of IVROBA. To our knowledge, this is the second report involving intraventricular vancomycin for the treatment of IVROBA in a patient persistently having positive cerebrospinal fluid (CSF) cultures despite prolonged use of IV antibiotics; once intraventricular vancomycin was employed, the patient

demonstrated remarkable improvement without perceivable side effects.

Case Report

A 64-year-old male, with a history of poorly controlled Type II diabetes mellitus (HbA1c = 16), presented with right arm weakness, visual disturbance, expressive aphasia, and confusion. Magnetic resonance imaging (MRI) of the brain revealed multifocal brain abscesses (right frontal lobe, right occipital lobe, and left parietal lobe) [Figure 1]. The patient was started on IV vancomycin, ceftriaxone, and metronidazole on the day of admission. The right occipital abscess was needle-tapped the next day, which grew *Streptococcus intermedius*; unfortunately, antibiotic susceptibilities could not be extracted due to inadequate growth. Despite treatment with systemic, broad-spectrum antibiotics for more than a month, the patient deteriorated into a comatose state, requiring intubation for airway protection. A repeat MRI of the brain showed IVROBA and associated ventriculitis [Figure 2]. An external ventricular drain was placed [Figure 3]. The patient underwent further needle drainage of the right frontal and left parietal abscesses. Daily CSF Gram-stain remained positive

**Ninh Doan,
Ha Nguyen,
Li Luyuan¹,
Saman Shabani,
Michael Gelsomino,
Vijay Johnson²**

*Departments of Neurosurgery,
²Neurology, ¹Medical College
of Wisconsin, Milwaukee,
Wisconsin, 53226, USA*

Address for correspondence:

*Dr. Ninh Doan,
Department of Neurosurgery,
Medical College of Wisconsin,
9200 W. Wisconsin Avenue,
Milwaukee, Wisconsin, 53226,
USA.*

E-mail: ndoan@mcw.edu

Access this article online

Website: www.asianjns.org

DOI: 10.4103/1793-5482.185065

Quick Response Code:



How to cite this article: Doan N, Nguyen H, Luyuan L, Shabani S, Gelsomino M, Johnson V. Good outcomes with the intraventricular vancomycin therapy in a patient with ruptured brain abscesses. *Asian J Neurosurg* 2018;13:396-9.

This is an open access journal, and articles are distributed under the terms of the Creative Commons Attribution-NonCommercial-ShareAlike 4.0 License, which allows others to remix, tweak, and build upon the work non-commercially, as long as appropriate credit is given and the new creations are licensed under the identical terms.

For reprints contact: reprints@medknow.com

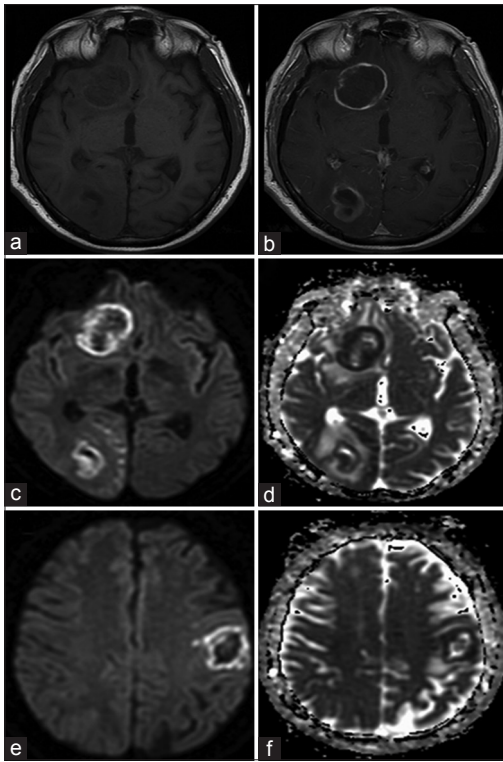


Figure 1: Initial magnetic resonance image of the brain shows T1 without contrast, (a) T1 with contrast, (b) diffusion-weighted imaging sequence, (c) apparent diffusion coefficient sequence, (d) diffusion-weighted imaging sequence, (e) apparent diffusion coefficient sequence, and (f) magnetic resonance image reveals ring enhancement lesions with bright diffusion-weighted imaging and dark apparent diffusion coefficient signals, suggesting intraparenchymal abscesses

for Gram-positive cocci despite prolonged treatment with IV antibiotics. Due to continual clinical decline, intraventricular vancomycin therapy was initiated. The patient was given 10–20 mg of intraventricular vancomycin daily, through the external ventricular drain; dosages were adjusted to achieve the CSF vancomycin therapeutic trough level of 20–25 mg/L.^[15-17] A week later, IV rifampin was added to the antibiotic regimen and ceftriaxone was switched to cefotaxime 2 g every 4 h. The CSF Gram-stain turned negative after 11 days of intraventricular therapy, and 5 days after the CSF, vancomycin level became therapeutic. On the same day, the patient gradually became more alert. The patient received intraventricular vancomycin for a total of 30 days. He was discharged on 2 months after his initial presentation. At discharge, the patient could follow simple commands, exhibit a steady gait, and demonstrate full strength in all extremities; although he still had expressive aphasia, his speech was improving. More recently, the patient was employed at a rehabilitation facility.

Discussion

The overall morbidity and mortality rates from brain abscess have progressively improved over the last several decades.^[6] However, the most feared sequela of brain abscess is IVROBA, which can rapidly lead to death

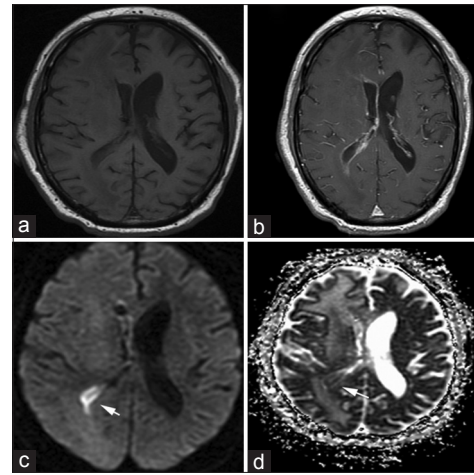


Figure 2: Magnetic resonance image of the brain shows T1 without contrast, (a) T1 with contrast, (b) diffusion-weighted imaging sequence, (c) apparent diffusion coefficient sequence, and (d) magnetic resonance image reveals ventricular wall enhancement with bright diffusion-weighted imaging signals and dark apparent diffusion coefficient signals, indicating the presence of intraventricular purulence materials from the ruptured abscess denoted by the arrows

without an aggressive therapy. Successful treatments of IVROBA with systemic therapies have been reported, albeit with small sample sizes.^[2,18-20] It has been suggested that there is a higher chance for success in the treatment of IVROBA with systemic therapy if patients had been receiving antibiotics prior to the intraventricular rupture;^[7] this may be due to the excellent vancomycin penetration of the brain abscess with systemic treatment, as abscess levels can reach up to 86% of serum levels.^[21] In fact, CNS infection may facilitate vancomycin CSF penetration, as a higher level of CSF vancomycin was achieved in patients with meningitis compared to those without meningitis.^[22]

Kao *et al.* identified diabetes mellitus as the leading, underlying comorbidity associated with brain abscess in their series of 53 patients.^[23] As such, our patient had a significant risk factor given his high HgbA1c. Although *S. intermedius* was identified from the initial biopsy, the susceptibility study was not achievable due to the lack of bacterial growth. This finding is not uncommon; the incidence of a sterile biopsy from a brain abscess ranges from 0% to 43%.^[24-26] Antibiotic administration before biopsy is known to decrease the yield of laboratory cultures;^[24] our patient received broad-spectrum antibiotics a day before the biopsy, and this may have suppressed the bacterial growth required for the susceptibility study.

Despite treatment with broad-spectrum IV antibiotics for over a month, our patient demonstrated disease progression, as he exhibited clinical decline associated with IVROBA and persistently having positive CSF cultures. In comparison, negative CSF cultures were noted 11 days after initiation of intraventricular vancomycin therapy. Once purulent material occupies the ventricular system, diffuse inflammation can follow, leading to ventricular

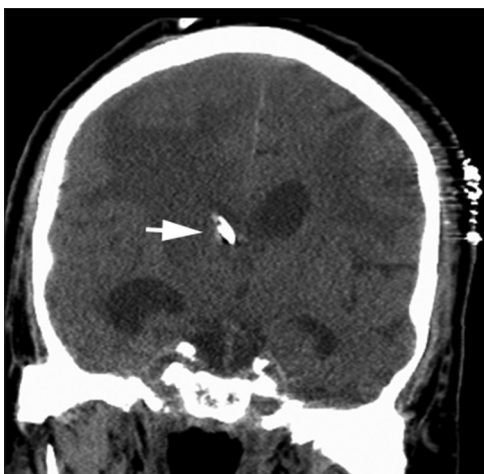

Figure 3: Computed tomography of head without contrast coronal view shows location of the catheter tip within the ventricle, denoted by the arrow

septation and organized debris; this cascade elicits barriers that impede the penetration of IV antibiotics to the ventricular system, where infectious nidus may exist.^[27] This may explain the persistently positive CSF cultures despite prolonged IV antibiotics. With intraventricular vancomycin, the antibiotic comes into direct contact with the intraventricular infection [Figures 2 and 3]. The administration of intraventricular antibiotics can control infection, reduce inflammation, and prevent ventricular septation.^[8] Clinically, our patient improved gradually with the commencement of intraventricular therapy, and the infection was eventually eradicated.

Conclusion

IVROBA is unlikely to be effectively treated without intraventricular antibiotics. The intraventricular infection creates barriers that prevent the penetration of IV antibiotics to the ventricular system, where infectious nidus may exist. This case suggests that intraventricular vancomycin may be a safe, effective, and viable option for the treatment of IVROBA, especially for patients becoming refractory to systemic antibiotics.

Financial support and sponsorship

Nil.

Conflicts of interest

There are no conflicts of interest.

References

1. Ballantine HT Jr., WHITE JC. Brain abscess; influence of the antibiotics on therapy and mortality. *N Engl J Med* 1953;248:14-9.
2. Yang SY, Zhao CS. Review of 140 patients with brain abscess. *Surg Neurol* 1993;39:290-6.
3. Schliamser SE, Bäckman K, Norrby SR. Intracranial abscesses in adults: An analysis of 54 consecutive cases. *Scand J Infect Dis* 1988;20:1-9.

4. Nielsen H, Gyldensted C, Harmsen A. Cerebral abscess. Aetiology and pathogenesis, symptoms, diagnosis and treatment. A review of 200 cases from 1935-1976. *Acta Neurol Scand* 1982;65:609-22.
5. Ballantine HT Jr., Shealy CN. The role of radical surgery in the treatment of abscess of the brain. *Surg Gynecol Obstet* 1959;109:370-4.
6. Zeidman SM, Geisler FH, Olivi A. Intraventricular rupture of a purulent brain abscess: Case report. *Neurosurgery* 1995;36:189-93.
7. Isono M, Wakabayashi Y, Nakano T, Fujiki M, Mori T, Hori S. Treatment of brain abscess associated with ventricular rupture – Three case reports. *Neurol Med Chir (Tokyo)* 1997;37:630-6.
8. Whang CJ, Cauthen JC, Garcia-Bengochea F. Successful treatment of ventriculitis by continuous intraventricular irrigation with gentamicin solution. *Surg Neurol* 1974;2:91-4.
9. Patel JA, Pacheco SM, Postelnick M, Sutton S. Prolonged triple therapy for persistent multidrug-resistant *Acinetobacter baumannii* ventriculitis. *Am J Health Syst Pharm* 2011;68:1527-31.
10. Ng K, Mabasa VH, Chow I, Ensom MH. Systematic review of efficacy, pharmacokinetics, and administration of intraventricular vancomycin in adults. *Neurocrit Care* 2014;20:158-71.
11. Wen DY, Bottini AG, Hall WA, Haines SJ. Infections in neurologic surgery. The intraventricular use of antibiotics. *Neurosurg Clin N Am* 1992;3:343-54.
12. Hayashi K, Fukuda T, Endo K, Goto J. A 46-year-old man with meningitis caused by *Diplococcus pneumoniae* and a lesion in the corpus callosum splenium. *Brain Nerve* 2011;63:271-81.
13. Shen MC, Lee SS, Chen YS, Yen MY, Liu YC. Liver abscess caused by an infected ventriculoperitoneal shunt. *J Formos Med Assoc* 2003;102:113-6.
14. Inamasu J, Kuramae T, Tomiyasu K, Nakatsukasa M. Fulminant ependymitis following intraventricular rupture of brain abscess. *J Infect Chemother* 2011;17:534-7.
15. Rybak MJ, Lomaestro BM, Rotschafer JC, Moellering RC, Craig WA, Billeter M, et al. Vancomycin therapeutic guidelines: A summary of consensus recommendations from the infectious diseases society of America, the American Society of Health-System Pharmacists, and the Society of Infectious Diseases Pharmacists. *Clin Infect Dis* 2009;49:325-7.
16. Ricard JD, Wolff M, Lacherade JC, Mourvillier B, Hidri N, Barnaud G, et al. Levels of vancomycin in cerebrospinal fluid of adult patients receiving adjunctive corticosteroids to treat pneumococcal meningitis: A prospective multicenter observational study. *Clin Infect Dis* 2007;44:250-5.
17. Nagl M, Neher C, Hager J, Pfausler B, Schmutzhard E, Allerberger F. Bactericidal activity of vancomycin in cerebrospinal fluid. *Antimicrob Agents Chemother* 1999;43:1932-4.
18. Black PM, Levine BW, Picard EH, Nirmel K. Asymmetrical hydrocephalus following ventriculitis from rupture of a thalamic abscess. *Surg Neurol* 1983;19:524-7.
19. Dawes JD, Marshall HF, Robson FC. Ventricle rupture of temporal lobe abscess. *J Laryngol Otol* 1969;83:981-90.
20. Hayashi A, Hosoda H, Sekino T, Tokoro K. Rupture of brain abscess into the lateral ventricle. Case report. *Neurol Med Chir (Tokyo)* 1984;24:217-20.
21. Levy RM, Gutin PH, Baskin DS, Pons VG. Vancomycin penetration of a brain abscess: Case report and review of the literature. *Neurosurgery* 1986;18:632-6.
22. Albanèse J, Léone M, Bruguerolle B, Ayem ML, Lacarelle B,

- Martin C. Cerebrospinal fluid penetration and pharmacokinetics of vancomycin administered by continuous infusion to mechanically ventilated patients in an intensive care unit. *Antimicrob Agents Chemother* 2000;44:1356-8.
23. Kao PT, Tseng HK, Liu CP, Su SC, Lee CM. Brain abscess: Clinical analysis of 53 cases. *J Microbiol Immunol Infect* 2003;36:129-36.
 24. Lakshmi V, Umabala P, Anuradha K, Padmaja K, Padmasree C, Rajesh A, *et al.* Microbiological spectrum of brain abscess at a tertiary care hospital in South India: 24-year data and review. *Patholog Res Int* 2011;2011:583139.
 25. Menon S, Bharadwaj R, Chowdhary A, Kaundinya DV, Palande DA. Current epidemiology of intracranial abscesses: A prospective 5 year study. *J Med Microbiol* 2008;57(Pt 10):1259-68.
 26. Prasad KN, Mishra AM, Gupta D, Husain N, Husain M, Gupta RK. Analysis of microbial etiology and mortality in patients with brain abscess. *J Infect* 2006;53:221-7.
 27. Schultz P, Leeds NE. Intraventricular septations complicating neonatal meningitis. *J Neurosurg* 1973;38:620-6.