Article published online: 2022-09-20

Case Report

Endoscopic Three-surgeon Six-handed Transorbital Transnasal Technique for Excision of Juvenile Nasopharygeal Angiofibroma: New Frontier Explored

Abstract

Endoscopic endonasal transorbital approach has been described for the removal of orbital lesions located anteromedially in temporal fossa. The same has been observed to be a versatile approach to the anterior and middle cranial fossa only in laboratory studies. This is the first clinical report of combined transorbital transnasal endoscopic approach to the cavernous sinus, superior orbital fissure, and middle cranial fossa in a case of recurrent nasopharyngeal angiofibroma using the three-surgeon six-handed technique.

Keywords: *Combined transorbital transnasal approach, middle cranial fossa, nasopharyngeal angiofibroma*

Trichy Narayanan Janakiram, Palak Parekh, Hanish Haneefa, Sivaswamy Karthik Prasad

Department of Otorhinolaryngology, Royal Pearl Hospital, Tiruchirapally, Tamil Nadu, India

Introduction

The advent of the endoscope followed by breakthrough innovations in instrumentation, improved technical infrastructure such as navigation, increasing number of published anatomical studies coupled with experience in performing endoscopic skull base surgeries has considerably increased the indications for endoscopic endonasal approaches to diseases of the skull base. This has enabled greater access to deep-seated lesions with improved visualization as well as reduced manipulation of neurovascular structures and brain parenchyma. Endoscopic endonasal transorbital procedures were found to be effective for removal of orbital lesions located anteromedially in temporal fossa.[1] The combined endoscopic transorbital and transnasal approach has been observed to be a versatile approach to the anterior and middle cranial fossa in laboratory studies.[2]

Case Report

A 17-year-old male presented to the Department of ENT, Royal Pearl Hospital, Trichy, South India, with complaints of intermittent, unprovoked, torrential bleeding from the nose since 1½ years. He had been operated twice in the past at different centers for Juvenile Nasopharyngeal Angiofibroma. Endoscopic excision had been performed 2 years ago. Neurological examination was normal. A year ago, the tumor had been excised by external approach via Weber-Ferguson incision. Diagnostic nasal endoscopy showed reddish globular mass in right nasal cavity and nasopharynx. Contrast-enhanced computerized tomography (CT) of the paranasal sinuses and brain showed an enhancing mass involving the right nasal cavity, sphenoid sinus, pterygopalatine fossa, infra temporal fossa, superior orbital fissure, inferior orbital fissure, cavernous sinus with intracranial extension into anterior part temporal fossa [Figures 1 and 2]. There was widening of the sphenopalatine foramen and pterygopalatine fossa with anterior bowing of posterior wall of maxillary antrum. The mass extended cranially up to intra-axial aspect of middle cranial fossa. The tumor measured 68 mm × 54 mm × 48 mm in size. The patient was otherwise healthy and all laboratory parameters were normal. He was taken up for endoscopic excision of lesion under general anesthesia (GA). Preoperative embolization was not performed as it is not a regular practice in our setup. Under GA, patient was put in supine position, head end elevated (30°) and head turned to right side. A temporary external carotid artery clamping was done and the nasal part of the tumor delineated. Endoscopic-modified

How to cite this article: Janakiram TN, Parekh P, Haneefa H, Prasad SK. Endoscopic three-surgeon six-handed transorbital transnasal technique for excision of Juvenile Nasopharygeal Angiofibroma: New frontier explored. Asian J Neurosurg 2017;12:790-3.

Address for correspondence:
Dr. Trichy Narayanan Janakiram, Department of Otorhinolaryngology, Royal Pearl Hospital, Tiruchirapally, Tamil Nadu, India.
E-mail: research.royalpearl@gmail.com

Access this article online

Website: www.asianjns.org

DOI: 10.4103/1793-5482.181148

Quick Response Code:

Figure 1: Axial contrast-enhanced computerized tomography of the paranasal sinuses and brain showing an enhancing mass involving the right nasal cavity, sphenoid sinus, pterygopalatine fossa, infra temporal fossa, superior orbital fissure, inferior orbital fissure, cavernous sinus with intracranial extension into anterior part temporal fossa

Figure 2: Coronal computerized tomography showing tumor with intracranial extension into the anterior part of the temporal fossa

Denker's technique was used. Posterior wall of maxilla was removed to expose the periosteum and tumor. The rostrum of sphenoid was exposed and the sphenoidal part of tumor was delineated. The nasal, nasopharyngeal, pterygopalatine fossa, infratemporal fossa and sphenoid component of the tumor was removed in one piece to expose the pterygoid wedge. The pterygoid wedge was drilled and tumor was removed from the lateral recess. Tumor was found extending on to inferior temporal surface of greater wing of sphenoid and inferior orbital fissure. Tumor was removed from the same. The principle of not crossing cranial nerves and creating separate trajectories to address tumor on the other side of cranial nerves was followed. We decided to approach the intracranial component lateral to superior orbital fissure using the transorbital endoscopic approach described by Castelnuovo. Three-surgeon six-handed technique was employed considering the complexity of the tumor and need for concomitant use of more instruments. An incision was made below the lateral aspect of the eyebrow. Supraorbital rim was drilled by 4–0 diamond burr. Periosteum was elevated till the level of superior orbital fissure. The lateral part of the orbit adjacent to the superior orbital fissure was drilled to create a corridor bounded anteriorly by temporalis muscle. Dura was found to be intact and on incision, tumor was seen. Using bipolar diathermy, the vessels in the tumor were cauterized. Tumor was excised gently in the extracapsular plane. On excision of tumor, the temporal lobe descended down. Hemostasis was secured using floseal, surgicel, and warm saline irrigation (40°C). The intra-orbital corridor was filled with fat harvested from the thigh. Exposed carotid artery was covered with fascia lata, gel foam, nasopore, merocel and Foley's catheter tamponade was done. The total blood loss during the procedure was 1200 ml, which was replaced by transfusion. Patient was given antibiotics, anticonvulsants and anti-cerebral edema measures were employed. All cranial nerves were intact. Extraocular movements were normal and there was no lateral rectus palsy [Figure 3]. Patient's vision was normal postoperatively. Postoperative magnetic resonance imaging was done after 48 h. It revealed a 5 mm residue on the posterior most part of the temporal lobe [Figure 4]. We are contemplating a gamma knife stereotactic radio-surgery for the same. Histopathological examination of the excised specimen was confirmatory of angiofibroma.

Discussion

Endoscopic excision of Juvenile nasopharyngeal angiofibroma has to be done by a well-trained team while dealing with large tumors. Endoscopic endonasal techniques have expanded indications due to the availability of latest high-definition camera system, navigation systems, carotid Doppler and new hemostatic agents. Expanded endoscopic endonasal approaches have begun to permit access to middle third of the clivus, petrous part of the internal carotid artery, cavernous sinus, and medial infratemporal fossa in cases where lesions are located centrally and neurovascular structures displaced laterally.[3] Parasellar area has been approached without craniotomy either via transethmoid–pterygoid–sphenoid approach or mini open procedures such as lateral orbital wall approach.[4-9] Transorbital endoscopic approaches to cavernous sinus, middle cranial fossa and Meckel cave region are still being investigated. Currently, they are being used for orbital trauma, meningoencephaloceles and repair of cerebrospinal fluid (CSF) leaks.[10-15] Combined transorbital transnasal approach to the anterior and middle cranial fossa has been investigated on cadeveric heads by Castelnuovo *et al*. and has been found to provide greater exposure, better exposure, and significant control of neurovascular structures.[1,2] This is the first clinical report of combined transorbital transnasal endoscopic approach to the cavernous sinus, superior orbital fissure, and middle cranial fossa in a case of recurrent nasopharyngeal

Figure 3: Postoperative image taken with informed consent from patient showing intact lateral rectus

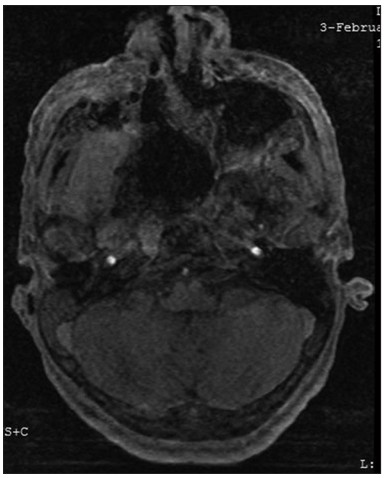

Figure 4: Postoperative magnetic resonance imaging image showing residual tumor of 5 mm size in the posterior part of the temporal lobe

angiofibroma. The binostril, two-surgeon, four-handed dissection technique (University of Pittsburgh Medical Centre Technique) was initially employed. However, due to the need for more instrumentation, given the complexity of tumor we had to switch over to three-surgeon, six-handed dissection technique. The transnasal transorbital route offers superb visualization and direct view of the lesion and surrounding structures. Drilling of posterior medial and lateral orbit allows access to middle fossa floor and parasellar area. In comparison to the transphenoidal approach where, the lateral cavernous sinus is at periphery, here it is in the center of the exposed field and permits greater maneuverability. Further, it avoids brain retraction and manipulation. Almost complete tumor removal could be accomplished in spite of the tumor being an extensive one. This approach also ensures better cosmesis.

In this approach, a corridor bounded medially by the orbit and laterally by the temporalis muscle is used and hence profuse bleeding from ruptured vessels could be a limiting factor.

Further, if the tumor extends on either side of optic nerve or involves the cavernous sinus, this approach may not suffice as a single modality approach. Since the lesion is approached transorbitally, breach of the periorbita and fat prolapsed can lead to difficulty during surgery.

Although we did not encounter any intraoperative or postoperative complications, skin burns from endoscope light is a possible complication and prolonged exposure at high intensity should be avoided. Other possible complications include CSF leak, intraparenchymal injury, arachnoid bleed, injury to contents of superior orbital fissure, orbital injury, and scarring.

Visualization of the anatomy is enhanced by endoscopy in this approach. Endoscopy improves illumination in deep operative surgical site with higher magnification and angled line of sight for hidden areas. Tumors extending lateral to optic nerve along the greater wing of sphenoid towards temporal fossa can be approached through this route after detailed preoperative planning. The simplicity of this procedure could make this as an option to other approaches. However, long-term follow-up and more studies are required to evaluate the effectiveness of this new technique in terms of patient outcome and tumor recurrence rate.

Conclusion

Endoscopic combined transorbital transnasal approach provides a direct route to the lateral cavernous sinus, superior orbital fissure, anterior and middle cranial fossa. It allows for wide exposure with significant control of neurovascular structures and hence reduces morbidity. It enables complete removal of lesions even in extensive cases and ensures cosmetically acceptable outcomes. When performed by a skilled team of surgeons, with sound anatomical basis and surgical rationale, this approach would ensure better postoperative outcome.

Declaration of patient consent

The authors certify that they have obtained all appropriate patient consent forms. In the form the patient(s) has/have given his/her/their consent for his/her/their images and other clinical information to be reported in the journal. The patients understand that their names and initials will not be published and due efforts will be made to conceal their identity, but anonymity cannot be guaranteed.

Financial support and sponsorship

Nil.

Conflicts of interest

There are no conflicts of interest.

References

1. Castelnuovo P, Dallan I, Locatelli D, Battaglia P, Farneti P, Tomazic PV, *et al*. Endoscopic transnasal intraorbital surgery:

Our experience with 16 cases. Eur Arch Otorhinolaryngol 2012;269:1929-35.

2. Alqahtani AA, Dallan I, Castelnuovo P. Transorbital transnasal endoscopic combined approach to anterior and middle skull base: Laboratory investigation. Otolaryngol Head Neck Surg 2014;151 1 Suppl:130.
3. Kassam AB, Gardner P, Snyderman C, Mintz A, Carrau R. Expanded endonasal approach: Fully endoscopic, completely transnasal approach to the middle third of the clivus, petrous bone, middle cranial fossa, and infratemporal fossa. Neurosurg Focus 2005;19:E6.
4. Doglietto F, Lauretti L, Frank G, Pasquini E, Fernandez E, Tschabitscher M, *et al.* Microscopic and endoscopic extracranial approaches to the cavernous sinus: Anatomic study. Neurosurgery 2009;64 5 Suppl 2:413-21.
5. Altay T, Patel BC, Couldwell WT. Lateral orbital wall approach to the cavernous sinus. J Neurosurg 2012;116:755-63.
6. Kassam A, Snyderman CH, Mintz A, Gardner P, Carrau RL. Expanded endonasal approach: The rostrocaudal axis. Part I. Crista galli to the sella turcica. Neurosurg Focus 2005;19:E3.
7. Kassam AB, Vescan AD, Carrau RL, Prevedello DM, Gardner P, Mintz AH, *et al.* Expanded endonasal approach: Vidian canal as a landmark to the petrous internal carotid artery. J Neurosurg 2008;108:177-83.
8. Frank G, Pasquini E. Approach to the cavernous sinus. Vienna, Austria: Springer; 2003. p. 159-75.
9. Frank G, Pasquini E. Endoscopic endonasal cavernous sinus surgery, with special reference to pituitary adenomas. Front Horm Res 2006;34:64-82.
10. Balakrishnan K, Moe KS. Applications and outcomes of orbital and transorbital endoscopic surgery. Otolaryngol Head Neck Surg 2011;144:815-20.
11. Moe KS, Jothi S, Stern R, Gassner HG. Lateral retrocanthal orbitotomy: A minimally invasive, canthus-sparing approach. Arch Facial Plast Surg 2007;9:419-26.
12. Ciporen JN, Moe KS, Ramanathan D, Lopez S, Ledesma E, Rostomily R, *et al.* Multiportal endoscopic approaches to the central skull base: A cadaveric study. World Neurosurg 2010;73:705-12.
13. Moe KS, Bergeron CM, Ellenbogen RG. Transorbital neuroendoscopic surgery. Neurosurgery 2010;67 (3 Suppl Operative):ons16-28.
14. Moe KS, Kim LJ, Bergeron CM. Transorbital endoscopic repair of cerebrospinal fluid leaks. Laryngoscope 2011;121:13-30.
15. Wu W, Cannon PS, Selva D, Tu Y, Wu Q. Endoscopic transorbital approach for repair of cerebrospinal fluid leakage following removal of an orbito-cranial foreign body. Clin Experiment Ophthalmol 2011;39:375-7.