

## CASE REPORT

# Solid cystic trigeminal schwannoma with intraorbital extension causing proptosis and vision loss

Pankaj Gupta, Arvind Sharma, Jitendra Singh

Department of Neurosurgery, Mahatma Gandhi Medical College, Jaipur, Rajasthan, India

## ABSTRACT

Schwannomas are slowly growing, well capsulated, benign tumors. Involvement of vestibular nerve is most commonly followed by trigeminal nerve. Trigeminal schwannoma is rare entity, and cystic degeneration with intraorbital extension of trigeminal schwannoma is even rarer. These tumors occur in fourth and fifth decades of life and patients have variable presentation depending on which cranial compartment is involved. Orbital schwannoma usually presents with proptosis with or without vision loss. We are reporting such a rare case of solid cystic trigeminal schwannoma with intraorbital extension through superior orbital fissure that was removed surgically.

**Key words:** Intraorbital, proptosis, trigeminal schwannoma

## Introduction

Schwannomas are well capsulated, slowly growing benign tumors. These tumors arise from schwann cells that wrap the peripheral or cranial nerves; hence, these tumors are basically peripheral nerve sheath tumors.<sup>[1]</sup> Although trigeminal schwannoma is the second most common schwannoma after acoustic, it is rare intracranial tumor. Trigeminal schwannoma accounts for 0.8–8% to all intracranial schwannomas<sup>[2]</sup> and this corresponds to 0.07–0.36% of all intracranial neoplasm. Intracranial cystic schwannomas are not so common and barring the vestibular nerve; these tumors are rare.<sup>[3]</sup> Intraorbital extension of trigeminal schwannoma is even rarer.<sup>[4]</sup> These patients usually present with painless slowly progressive proptosis with or without vision loss. We are reporting such a rare case of solid cystic trigeminal schwannoma with intraorbital extension.

## Case Report

A 44-year-old female presented to us with complaints of painless, slowly progressive protrusion of left eye with

gradually progressive vision loss since last 2 years. She was operated 1-year back elsewhere for swelling on suprorbital region, and biopsy was taken which was schwannoma. After sometime, again, there is increase in size of swelling and this was significant in last 6 months. General physical examination was unremarkable. On neurological examination, higher mental status was normal. There was restriction of eye movement on looking superolaterally. Her best-corrected visual acuity was 6/6 in the right eye and 6/36 in the left eye. On exophthalmometry, there was 8 mm nonaxial proptosis of the left eye. There was no relationship of proptosis with position of head. It was nonpulsatile and noncompressible. Both eyelids of left eye were normal, and there were no signs of inflammation. Corneal sensation of left eye was diminished. Schirmer's test did not reveal any abnormality as this test may impair in schwannoma of greater superficial petrosal nerve. Fundus examination of the right eye was normal while left side optic disc was swollen. Rest of the cranial nerve examination was normal. There was no sensory or motor deficit. Cerebellar examination was normal. Hematological analysis was within normal range.

Gadolinium-enhanced magnetic resonance imaging (MRI) brain [Figure 1] with orbit showed a moderate size, well

Access this article online	
Quick Response Code:	Website: www.asianjns.org
	DOI: 10.4103/1793-5482.181142

### Address for correspondence:

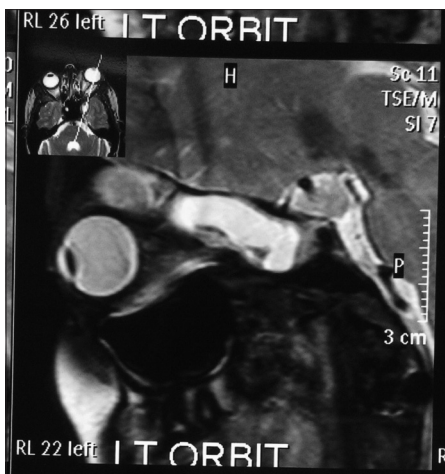Dr. Arvind Sharma, Department of Neurosurgery,  
Mahatma Gandhi Medical College, Jaipur, Rajasthan, India.  
E-mail: dr\_arvindsharma@yahoo.com

This is an open access article distributed under the terms of the Creative Commons Attribution-NonCommercial-ShareAlike 3.0 License, which allows others to remix, tweak, and build upon the work non-commercially, as long as the author is credited and the new creations are licensed under the identical terms.

**For reprints contact:** reprints@medknow.com

**How to cite this article:** Gupta P, Sharma A, Singh J. Solid cystic trigeminal schwannoma with intraorbital extension causing proptosis and vision loss. Asian J Neurosurg 2016;11:456.

defined, solid cystic, contrast enhancing extradural lesion with intraorbital-extraconal extension causing proptosis of left eye. This mass was hypointense on T1-weighted and hyperintense on T2-weighted images. Tumor was extending into orbital extraconal space through superior orbital fissure. On the basis of clinical and radiological finding, a provisional diagnosis of trigeminal schwannoma involving ophthalmic division was made. The patient was taken for surgery, and left frontotemporo-orbitozygomatic craniotomy was performed. Tumor was extradural, solid cystic, mildly vascular with involvement of cavernous sinus. Complete excision of tumor was done. Postoperatively, patient had no complication and her vision improved to 6/9 with resolution of proptosis with normal extraocular movements within 2 weeks. Histopathological analysis was done [Figure 2] and showed spindle-shaped bipolar cells that form fascicles and palisading appearance. Immunohistochemistry of the biopsy specimen was positive S100 [Figure 3], CD34 [Figure 4], and vimentin [Figure 5], hence confirms schwannoma. Postoperative MRI showed complete removal of tumor [Figure 6].

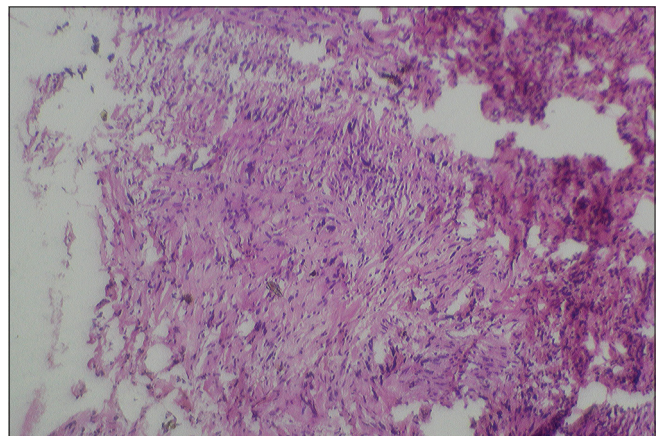


**Figure 1:** Gadolinium-enhanced magnetic resonance imaging brain coronal image showed contrast enhancing solid cystic mass extending into orbit

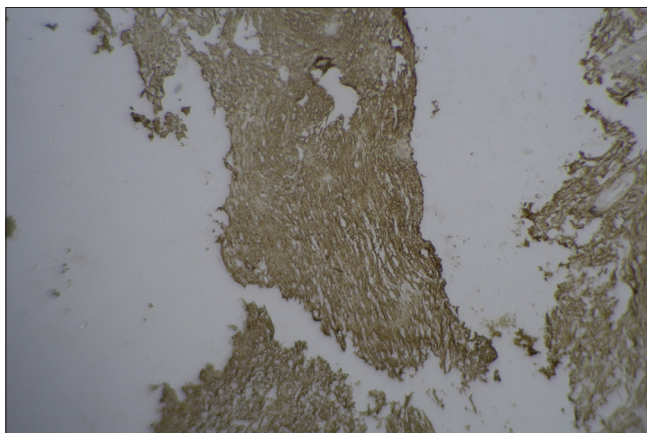
## Discussion

Trigeminal schwannomas are rare intracranial neoplasms.<sup>[1,2]</sup> These tumors are benign, slowly growing, well encapsulated, and classified as WHO Grade 1 neoplasm. Trigeminal schwannoma is more common in females<sup>[5]</sup> and usually involves patients of fourth and fifth decades.<sup>[6]</sup> Dixon and Smith first reported tumors arising from gasserian ganglion in 1846 and 1849, respectively. As the trigeminal nerve traverses all three cranial fossa, these tumors may arise from any part of trigeminal nerve, i.e., from root in posterior fossa, gasserian ganglia in middle cranial fossa, and from nerve division involving other extracranial spaces.<sup>[7]</sup>

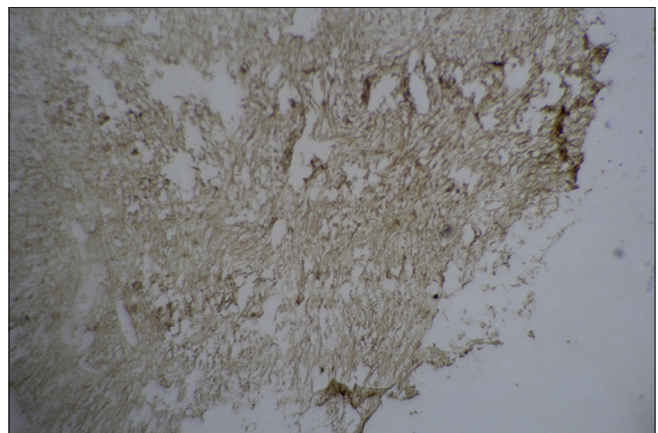
Growth from the root of cranial nerve V in the posterior fossa involves cerebellopontine angle whereas growth occurs epidurally into orbit and infratemporal fossa if there is involvement of extracranial branches. The tumor may extend into the orbit through the superior orbital fissure, in the infratemporal fossa through the foramen ovale or foramen rotundum and in the cavernous sinus through the lateral wall, and in the cerebellopontine angle through the trigeminal pore. There are so many different classifications



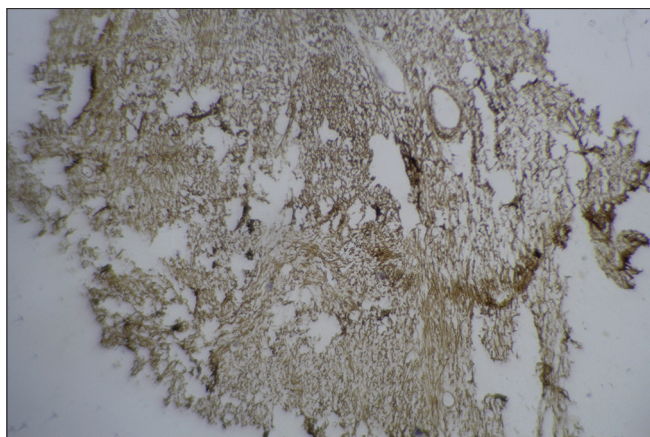
**Figure 2:** Photograph showed spindle-shaped bipolar cells in palisading manner



**Figure 3:** Immunohistochemistry showed cells to positive for s100



**Figure 4:** Immunohistochemistry showed cells positive for CD34



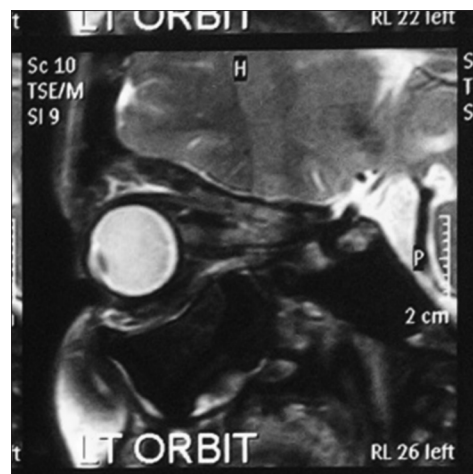**Figure 5:** Immunohistochemistry showed cells positive for vimentin

for trigeminal schwannomas.<sup>[8-10]</sup> Tumors of the neurogenic origin are rare in orbit and account for 1% of all the orbital tumors.<sup>[11,12]</sup> Orbital schwannoma may be associated with Neurofibromatosis Type 1 in 1.5% of the patients. As these tumors are slow growing and subtle in nature, patients usually present with large tumor at the time of diagnosis. Variable location of these tumors can cause variable symptoms and signs.<sup>[7]</sup> Trigeminal nerve-related complaints are the initial one in majority of the patients.<sup>[13]</sup> Facial hypoesthesia is the most common complaint and presents in 60% of the patients.<sup>[8]</sup> There may be involvement of motor part of trigeminal nerve. Corneal reflex may be diminished or absent.

About 24% of the orbital schwannoma arise from first division of trigeminal nerve and rest may be from supra- or infra-orbital nerve. These patients usually present with slowly progressive proptosis, diplopia, decrease extraocular movement, and sometimes with vision loss if the tumor directly compresses the optic nerve or secondarily due to raised intracranial pressure.<sup>[4]</sup>

Gadolinium-enhanced MRI of brain with orbit is the imaging modality of choice to diagnose trigeminal schwannoma. Schwannomas appear as well-circumscribed, heterogeneously enhancing masses that may be iso- or hypo-intense on T1-weighted images and hyperintense on T2-weighted images. Intratumoral hemorrhage may be seen but cystic changes are rare. Computed tomography scan is good to evaluate the accompanied bony changes such as erosion of petrous bone and widening of cranial foramen.

Because trigeminal schwannomas are benign and well-circumscribed tumors with only rare cases demonstrating invasion, complete surgical resection remains the definitive treatment. Selection of the surgical approach is dictated mainly by the location of the tumor. Radiotherapy is indicated in postoperative residual tumor. Incomplete excision of tumor may result in postoperative recurrence.



**Figure 6:** Postoperative magnetic resonance imaging image showing complete removal of tumor

## Conclusion

Trigeminal schwannoma is a rare intracranial neoplasm. Patients usually present with sensory or motor symptoms of trigeminal nerve. In few cases, patients may have involvement of other cranial nerves, features of brainstem or cerebellum compression or raised intracranial pressure. Cystic trigeminal schwannoma is very rare, and even intraorbital extension of cystic schwannoma is rarer. Our case is unique and adds a rich knowledge in existing literature because of cystic nature of trigeminal schwannoma with intraorbital extension.

## Financial support and sponsorship

Nil.

## Conflicts of interest

There are no conflicts of interest.

## References

1. Goel A, Muzumdar D, Raman C. Trigeminal neuroma: Analysis of surgical experience with 73 cases. *Neurosurgery* 2003;52:783-90.
2. Atlas S. *Magnetic Resonance Imaging of the Brain and Spine*. 2<sup>nd</sup> ed. Philadelphia: Lippincott Raven; 1996. p. 781-6.
3. Hasegawa T, Kida Y, Yoshimoto M, Koike J. Trigeminal schwannomas: Results of gamma knife surgery in 37 cases. *J Neurosurg* 2007;106:18-23.
4. Ghosh S, Das D, Varshney R, Nandy S. Orbital extension of trigeminal schwannoma. *J Neurosci Rural Pract* 2015;6:102-4.
5. VandeVyver V, Lemmerling M, Van Hecke W, Verstraete K. MRI findings of the normal and diseased trigeminal nerve ganglion and branches: A pictorial review. *JBR BTR* 2007;90:272-7.
6. McCormick PC, Bello JA, Post KD. Trigeminal schwannoma. Surgical series of 14 cases with review of the literature. *J Neurosurg* 1988;69:850-60.
7. Dolenc VV. Frontotemporal epidural approach to trigeminal neurinomas. *Acta Neurochir (Wien)* 1994;130:55-65.
8. Jefferson G. The trigeminal neurinomas with some remarks on malignant invasion of the gasserian ganglion. *Clin Neurosurg* 1953;1:11-54.
9. Lesoin F, Rousseaux M, Villette L, Autricque A, Dhellemmes P,

- Pellerin P, *et al.* Neurinomas of the trigeminal nerve. Acta Neurochir (Wien) 1986;82:118-22.
10. Yoshida K, Kawase T. Trigeminal neurinomas extending into multiple fossae: Surgical methods and review of the literature. J Neurosurg 1999;91:202-11.
  11. Khetan VD. Giant subperiosteal orbital schwannoma with luxated globe. J Clin Ophthalmol Res 2013;1:159-62.
  12. Arvind K, Mallika K, Chaudhary TS, Anitha C. Plexiform schwannoma of infraorbital nerve – A rare case report. IJB 2013;2:534-6.
  13. Al-Mefty O, Ayoubi S, Gaber E. Trigeminal schwannomas: Removal of dumbbell-shaped tumors through the expanded Meckel cave and outcomes of cranial nerve function. J Neurosurg 2002;96:453-63.

