

CASE REPORT

Spontaneous resolution of colloid cyst of the third ventricle: Implications for management

Mazda Keki Turel, Walter Kucharczyk¹, Fred Gentili

Division of Neurosurgery, Toronto Western Hospital, ¹Department of Medical Imaging and Surgery, University Health Network, Toronto, Ontario, Canada

ABSTRACT

While there is little controversy regarding the treatment of symptomatic colloid cysts, the optimal management of “incidentally” detected and asymptomatic colloid cyst remains unclear. The age of the patient, duration and significance of symptoms related to the cyst, size and radiological characteristics of the cyst and the presence of hydrocephalus are all factors to be considered before considering surgery. While surgery most often provides good results in the majority of patients, complications do occur. Despite growing literature about the natural history of this condition, to date, only three cases of spontaneous resolution of colloid cyst <10 mm have been reported. We report the case of spontaneous resolution of a colloid cyst larger than 10 mm, initially managed with close observation and serial neuroimaging. This case highlights the possible role for a conservative approach even in larger-sized cysts.

Key words: Colloid cyst, natural history, radiology, spontaneous resolution

Introduction

While uncommon, the occasional patient presenting to a physician with headache may on magnetic resonance imaging (MRI) be found to have an “incidental” colloid cyst of the third ventricle. The optimal management of these cysts remains unclear. While there has been an evolution in the management of these lesions from a recommendation of surgery in all patients, often based on early reports of the possibility of sudden death, to more recently some authors proposing that asymptomatic patients with a colloid cyst <7 mm may be managed conservatively.^[1] Others, based on natural history and long-term follow-up studies, have suggested that colloid cysts <10 mm could be managed expectantly.^[2] Many physicians however are often reluctant to offer conservative management to patients with colloid cysts, especially larger than 10 mm in size due to reports of acute neurological deterioration and sudden death.^[3,4] With increasing reports in the literature on

the natural history of colloid cysts, 3 reports of spontaneous resolution^[5-7] and one report of regression following rupture of colloid cysts have been published.^[8] We describe a case of a 45-year-old female with an “incidentally” detected colloid cyst measuring 11 mm that was not operated upon and showed marked partial regression on an 11-month follow-up MRI, followed by complete spontaneous resolution 2 years after initial diagnosis. A subsequent 3.5-year follow-up MRI (after initial diagnosis) showed no recurrence of the lesion. This case highlights the role of an expectant management of colloid cysts that measure >10 mm in size without hydrocephalus in asymptomatic patients that are carefully followed.

Case Report

History and examination

We present the case of a 45-year-old female who presented in 2011 with a 6-month history of new onset, nonspecific holocranial headache, and dizziness. She did not have clinical signs or symptoms of raised intracranial pressure, and neurological and fundoscopic examination was normal.

This is an open access article distributed under the terms of the Creative Commons Attribution-NonCommercial-ShareAlike 3.0 License, which allows others to remix, tweak, and build upon the work non-commercially, as long as the author is credited and the new creations are licensed under the identical terms.

For reprints contact: reprints@medknow.com

Access this article online	
Quick Response Code:	Website: www.asianjns.org
	DOI: 10.4103/1793-5482.181138

Address for correspondence:

Dr. Mazda Keki Turel, Division of Neurosurgery, Toronto Western Hospital, 399 Bathurst St. M5T 2S8 Toronto, Ontario, Canada.
E-mail: mazdaturel@gmail.com

How to cite this article: Turel MK, Kucharczyk W, Gentili F. Spontaneous resolution of colloid cyst of the third ventricle: Implications for management. *Asian J Neurosurg* 2017;12:203-6.

Radiology

The MRI [Figure 1] showed an 11 mm anterior third ventricular lesion at the foramen of Monro that was predominantly hyperintense on T2-weighted imaging with a hypointense focus within it, in keeping with a diagnosis of colloid cyst. The signal intensity pattern was the same on the fluid-attenuated inversion recovery images, likely related to the highly proteinaceous nature of the cyst fluid. There was no evidence of restricted diffusion or hydrocephalus. Gadolinium-enhanced images were not performed. It was felt that the headaches were not related to the lesion and she was treated symptomatically.

Follow-up

The patient was followed up with serial annual MRI imaging, which showed near-total regression of the lesion at 11 months [Figure 2], followed by complete resolution on the MRI done at 2 years [Figure 3]. There was no susceptibility artifact on the gradient echo images to suggest any interval bleed. No cyst remnants were visible on the MRI scan done at 2 years after the initial diagnosis. Ventricular size remained normal. She was asymptomatic at the time of her last follow-up.

Discussion

Colloid cysts of the third ventricle are rare and account for <1% of all primary brain tumors.^[9] Previously, these were believed to be derived from the primitive neuroepithelium of the tela choroidea. However, current studies suggest that the histogenesis may be endodermal.^[10,11]

Surgery versus observation for colloid cysts

Because of early reports in the literature of the occurrence of sudden death, surgery was often recommended in virtually all patients regardless of the size and symptomatic nature of the lesion. While surgery using modern microsurgical or more recently endoscopic techniques for these cysts can result in excellent outcomes in the majority of patients, operative mortality is around 1%, and overall morbidity including seizures, intraventricular/subdural/intracerebral hemorrhage, arterial/venous infarction, and meningitis is reported to be between 10% and 25%.^[12] However, more recently there have been reports and a trend toward a more conservative approach in some patients with small lesions and who are entirely asymptomatic. This is in part due to improved knowledge of the natural history of colloid cysts, especially the knowledge that sudden death is an extremely rare event in asymptomatic patients.^[2] Pollock and Huston^[2] followed up 58 patients with a mean follow-up of 6.5 years who were thought to be asymptomatic and noted that the incidence of symptomatic progression to be 0%, 0%, and 8% at 2, 5, and 10 years, respectively. No patient died suddenly in the follow-up interval.

However, several important factors should be considered before recommending conservative therapy. It should be

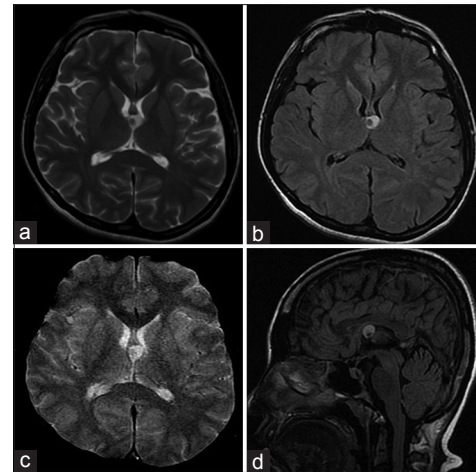


Figure 1: (a) T2-weighted axial magnetic resonance imaging and (b) axial fluid-attenuated inversion recovery images showing a 11 mm anterior third ventricular colloid cyst with mixed signal intensity, predominantly high signal but with a low-signal intracystic nidus. (c) T2*-weighted gradient images show no susceptibility (“blooming”) effects, thereby excluding the possibility of calcium or blood. (d) T1-weighted sagittal images showing a primarily hyperintense cyst with a hypointensity within it

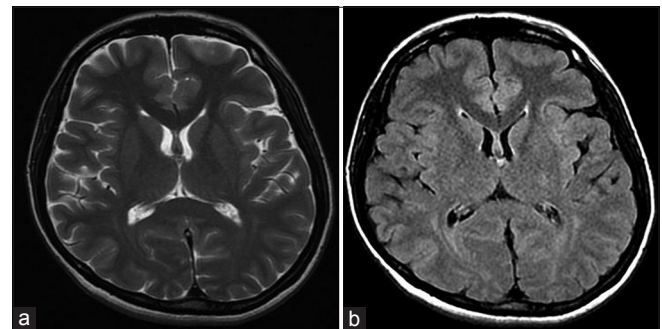


Figure 2: T2-weighted axial (a) and axial fluid-attenuated inversion recovery (b) images showing significant regression of the colloid cyst at 11 months follow-up from the time of initial diagnosis

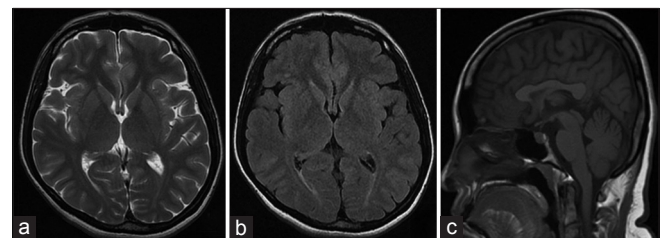


Figure 3: Twenty-four months later. (a) T2-weighted axial (b) axial fluid-attenuated inversion recovery and (c) T1-weighted sagittal magnetic resonance imaging show complete resolution of the cyst with no evidence of hemorrhage and normal-sized ventricles

firmly established that the patient is indeed asymptomatic with regards to their cyst, since up to 28% of “asymptomatic” patients have headache at presentation.^[2] While it has been suggested that colloid cysts smaller than 10 mm in diameter are associated with a minimal risk of acute deterioration, other factors that play a role in deciding an optimal management

strategy are age, duration of symptoms, the presence of hydrocephalus, and the appearance on radiology.^[2,3,13]

Radiological considerations

Colloid cysts have a variable appearance on MRI due to variable protein, water, and ionic content. Most cysts are hyperintense on T1-weighted and isointense on T2-weighted imaging. The hyperintensity on T1-weighted images is thought to be due to T1-shortening caused by highly proteinaceous cyst fluid. Even higher protein concentrations can cause T2-shortening, resulting in dark signal on T2-weighted images, as was apparent in the central nidus in this case. The possibility of calcium causing the low signal on the T2W images was excluded by the lack of susceptibility effects (“blooming”) on the T2*-weighted gradient echo image [Figure 1].

Pollock *et al.*^[13] suggested that an increased signal on T2-weighted imaging is due to the high liquid content and likely to expand with time, requiring surgical intervention. Our patient had mixed signal intensity on T2-weighted imaging. Since we do not have a histological diagnosis and no immunochemical analysis was done, the rare possibility of this representing a neurocysticercal cyst that is known to spontaneously resolve, exists. However, an experienced neuroradiologist reviewed the imaging findings and felt strongly that the imaging features were most consistent with a colloid cyst and the patient did not have a travel history. Other entities in the differential diagnosis such as hamartomas, primary or secondary neoplasms, xanthogranulomas, Rathke’s cleft cyst, and basilar aneurysm were excluded.

Spontaneous resolution of colloid cysts

The details of 3 cases of spontaneous resolution of colloid cyst of published in literature are described in Table 1. Of interest, all three reports are from the United Kingdom. While all had a size of <1 cm and no hydrocephalus, they had variable characteristics on imaging. Two of the three patients had headache at diagnosis and one patient was diagnosed after a fall. Duncan *et al.*^[7] described a 22-year-old patient who presented at 39 weeks of gestation and showed

an initial enlargement of the cyst with a change in imaging characteristics at 31 months after diagnosis followed by a complete resolution at 50 months. Motoyama *et al.*,^[8] from Japan, described a patient with a fairly large colloid cyst (size not reported) with hydrocephalus in whom surgical intervention was planned, but a repeat computed tomography scan done 10 days after the initial diagnosis showed resolution of the cyst with only visible remnant of the wall due to an asymptomatic hemorrhage. However, this was associated with increasing hydrocephalus.

While colloid cyst enlargement on follow-up imaging is well documented, the mechanism of spontaneous resolution remains unclear. Kachhara *et al.*^[14] reported a colloid cyst that increased in density but decreased in size following a cerebrospinal fluid (CSF) diversion procedure. They proposed that the reduction in size could be due to extraction of the cyst following CSF diversion. While spontaneous cyst rupture and resolution is a possible mechanism, none of the cases described had any MRI evidence of the same. It is possible for small cysts to undergo desiccation of its contents, which eventually get resorbed by the CSF. Rupture of larger cysts has been reported to cause asymptomatic aseptic meningitis requiring emergent treatment.^[15]

Conclusions

While the theories of spontaneous resolution remain uncertain, we believe that patients presenting with asymptomatic colloid cysts can be safely managed with careful serial neuroimaging. The first imaging should be done at 6–12 months following initial diagnosis and yearly thereafter. Obviously the patient is carefully instructed to return for repeat assessment at any time there is a change in his/her symptoms. Any evidence of even minimal ventricular enlargement either at presentation or on follow-up is an indication for surgery.

While the precise size above which one would not consider a conservative approach in an asymptomatic patient is not clear, most authors would recommend surgery in a lesion >1 cm. The current case illustrates that lesions >1 cm have the potential of spontaneous resolution.

Table 1: Summary of cases with spontaneous resolution of colloid cyst without any magnetic resonance imaging evidence of rupture

Case/year	Presentation	Size CT (mm)	CT	MRI (T1W)	MRI (T2W)	FLAIR	Hydrocephalus	Resolution (months)
Annamalai <i>et al.</i> (2008)	Fall from stairs	5	Hyper	Hyperintense	Hypointense	NR	Asymmetric ventricles	15
Gbejuade <i>et al.</i> (2011)	Headache	8	Hyper	NR	Hypointense	NR	No	19
Duncan <i>et al.</i> (2014)	Headache	3	Hyper	Hyperintense	NR	NR	No	50
Present case Turel <i>et al.</i> (2015)	Headache	11	NR	Hyperintense	Predominantly hyperintense with a small central hypointense nidus	Predominantly hyperintense with a small central hypointense nidus	No	24

NR – Not reported; CT – Computed tomography; MRI – Magnetic resonance imaging; T1W – T1-weighted; T2W – T2-weighted; FLAIR – Fluid-attenuated inversion recovery

Financial support and sponsorship

Nil.

Conflicts of interest

There are no conflicts of interest.

References

1. Kondziolka D, Lunsford LD. Microsurgical resection of colloid cysts using a stereotactic transventricular approach. *Surg Neurol* 1996;46:485-90.
2. Pollock BE, Huston J 3rd. Natural history of asymptomatic colloid cysts of the third ventricle. *J Neurosurg* 1999;91:364-9.
3. de Witt Hamer PC, Verstegen MJ, De Haan RJ, Vandertop WP, Thomeer RT, Mooij JJ, *et al.* High risk of acute deterioration in patients harboring symptomatic colloid cysts of the third ventricle. *J Neurosurg* 2002;96:1041-5.
4. Hamlat A, Pasqualini E, Askar B. Hypothesis about the physiopathology of acute deterioration and sudden death caused by colloid cysts of the third ventricle. *Med Hypotheses* 2004;63:1014-7.
5. Annamalai G, Lindsay KW, Bhattacharya JJ. Spontaneous resolution of a colloid cyst of the third ventricle. *Br J Radiol* 2008;81:e20-2.
6. Gbejuade H, Plaha P, Porter D. Spontaneous regression of a third ventricle colloid cyst. *Br J Neurosurg* 2011;25:655-7.
7. Duncan G, Kanodia AK, Jamel SE. Spontaneous enlargement then regression of a colloid cyst of the III ventricle. *Int Neuropsychiatr Dis J* 2014;2:28-33.
8. Motoyama Y, Hashimoto H, Ishida Y, Iida J. Spontaneous rupture of a presumed colloid cyst of the third ventricle – Case report. *Neurol Med Chir (Tokyo)* 2002;42:228-31.
9. Little JR, MacCarty CS. Colloid cysts of the third ventricle. *J Neurosurg* 1974;40:230-5.
10. Ho KL, Garcia JH. Colloid cysts of the third ventricle: Ultrastructural features are compatible with endodermal derivation. *Acta Neuropathol* 1992;83:605-12.
11. Kondziolka D, Bilbao JM. An immunohistochemical study of neuroepithelial (colloid) cysts. *J Neurosurg* 1989;71:91-7.
12. Sheikh AB, Mendelson ZS, Liu JK. Endoscopic versus microsurgical resection of colloid cysts: A systematic review and meta-analysis of 1,278 patients. *World Neurosurg* 2014;82:1187-97.
13. Pollock BE, Schreiner SA, Huston J 3rd. A theory on the natural history of colloid cysts of the third ventricle. *Neurosurgery* 2000;46:1077-81.
14. Kachhara R, Das K, Nair S, Gupta AK. Changing characteristics of a colloid cyst of the third ventricle. *Neuroradiology* 1999;41:188-9.
15. Bakhtevari MH, Sharifi G, Jabbari R, Shafizad M, Rezaei M, Samadian M, *et al.* Giant leaking colloid cyst presenting with aseptic meningitis: Review of the literature and report of a case. *World Neurosurg* 2015;84:1997-2001.