

# Spinal epidural angioliipomas: Clinical characteristics, management and outcomes

Sofiene Bouali, Nidhal Maatar, Asma Bouhoula, Khansa Abderrahmen, Imed Ben Said, Adnen Boubaker, Jalel Kallel, Hafedh Jemel

Department of Neurosurgery, National Institute of Neurology "Mongi Ben Hmida", Faculty of Medicine, University of Tunis El Manar, Tunis, Tunisia

## ABSTRACT

**Purpose:** The spinal epidural angioliipomas are rare expansive processes made of mature lipomatous and angiomatous elements. They often have a benign character. Their etiology, pathogenesis remains uncertain, and it is a cause of spinal cord compression. The magnetic resonance imaging is the most important neuroradiological examination. Histological examination is the only examination to confirm the diagnosis. Surgery is the treatment of choice.

**Methods:** A retrospective study of all patients operated on for a spinal epidural angioliipoma at the Department of Neurosurgery at the National Institute of Neurology of Tunis between January 2000 and December 2014 (15 years) was performed. The aim of this study is to describe the clinical, radiological, histological characteristics and the treatment of this tumor.

**Results:** A total of nine patients were operated from January 01, 2000 to November 30, 2014. The average age of our patients was 51 years with ages that ranged from 29 to 65 with a male predominance. The period between onset of symptoms and diagnosis ranged from 24 months with an average 12 months. Posterior localization of the tumor was seen in all patients. Surgical resection was performed for all cases. The postoperative course has been satisfactory, with a complete recovery of neurological functions in all patients.

**Conclusions:** The spinal epidural angioliipomas is rare expansive process causing spinal cord compression. Treatment is exclusively surgical resection. The functional outcome of spinal epidural angioliipomas is particularly favorable with a complete neurological recovery is if the patient was quickly operated.

**Key words:** Angioliipoma, epidural tumor, magnetic resonance imaging, pathology, spinal

## Introduction

Spinal angioliipomas are rare benign tumors containing mature fat cells with an excessive degree of vascular proliferation.<sup>[1-3]</sup> They are estimated to account for between 0.04% and 1.2% of all spinal axis tumors and are predominantly found in the epidural space, where they represent 2–3% of spinal tumors.<sup>[1,4,5]</sup> There have been more than 128 cases reported to

date.<sup>[6]</sup> In this paper, we present our cases of spinal epidural angioliipomas and discuss the relevant literature.

## Methods

A retrospective study of all patients operated on for a spinal epidural angioliipoma at the Department of Neurosurgery at the National Institute of Neurology of Tunis between January 2000 and December 2014 (15 years) was performed.

The purpose of this paper is to report our cases and review the clinical presentation, radiological appearance, pathological

This is an open access article distributed under the terms of the Creative Commons Attribution-NonCommercial-ShareAlike 3.0 License, which allows others to remix, tweak, and build upon the work non-commercially, as long as the author is credited and the new creations are licensed under the identical terms.

**For reprints contact:** reprints@medknow.com

Access this article online	
Quick Response Code:	Website: www.asianjns.org
	DOI: 10.4103/1793-5482.180901

## Address for correspondence:

Dr. Sofiene Bouali, Department of Neurosurgery, Faculty of Medicine, National Institute of Neurology, University of Tunis El Manar, Tunis, Tunisia.  
E-mail: sofienebouali@hotmail.fr

**How to cite this article:** Bouali S, Maatar N, Bouhoula A, Abderrahmen K, Said IB, Boubaker A, *et al.* Spinal epidural angioliipomas: Clinical characteristics, management and outcomes. *Asian J Neurosurg* 2016;11:348-51.

aspects, and treatment of this distinct clinico-pathological entity.

Lipomas and pure angioma were excluded from our study.

Data are collected and analyzed from patient medical files in the hospital archives.

### Results

A total of nine patients were admitted and operated during the period mentioned above.

The average age of our patients was 51 years with ages that ranged from 29 to 65 years. Four women aged 40, 47, 59, and 61, and five men aged 29, 48, 49, 62, and 65 [Table 1].

The diagnosis was established in all cases based on clinical findings, computed tomography (CT) scan, magnetic resonance imaging (MRI), and pathological findings.

The period between onset of symptoms and diagnosis ranged from 24 months with an average of 12 months. Six patients were presented with a progressive neurological deficit in the lower limbs, ranging from a mild deficit to complete motor loss as a consequence of spinal cord compression. A CT scan of the spine was done for one patient.

MRI was performed to the rest of 8 cases and showed homogeneous isointensity on T1-weighted images, which was slightly higher than the spinal cord, and homogeneously slightly high signal on T2-weighted images and homogeneously strongly enhanced. All lesions were noninfiltrating [Figures 1 and 2].

Of the nine patients, the lesions were located at the thoracic segment of the spinal canal in seven cases and a lumbar segment in two cases.

All lesions were resected by open surgery, and pathologic examination was performed for all cases. During surgical

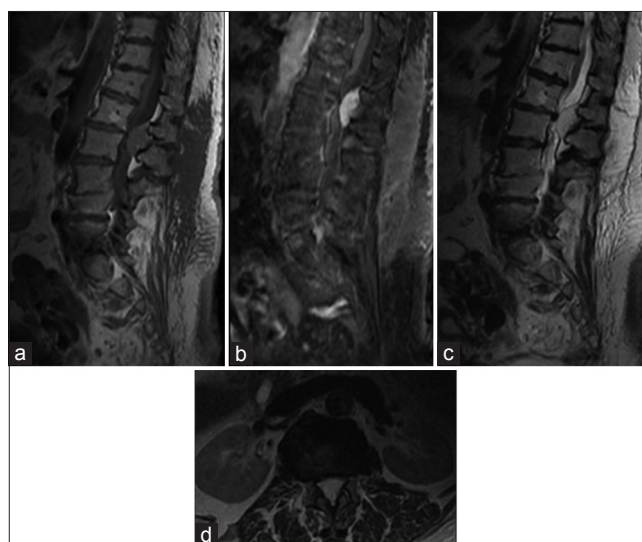
procedures, the lesions showed dark red or purple red color and as an intact capsule.

On histological examination, the tissue consisted mainly of fat cells and some regular vessels. Mature adipocytes and multifocal vascular proliferation, consistent with an angioliopoma [Figure 3].

The postoperative course has been satisfactory, with a complete recovery of neurological functions in all patients [Tables 1 and 2].

### Discussion

Berenbruch first described a case of spinal angioliopoma in 1890.<sup>[7]</sup> In 1960, Howard and Helwig established angioliopoma as a clinicopathological entity containing vascular and



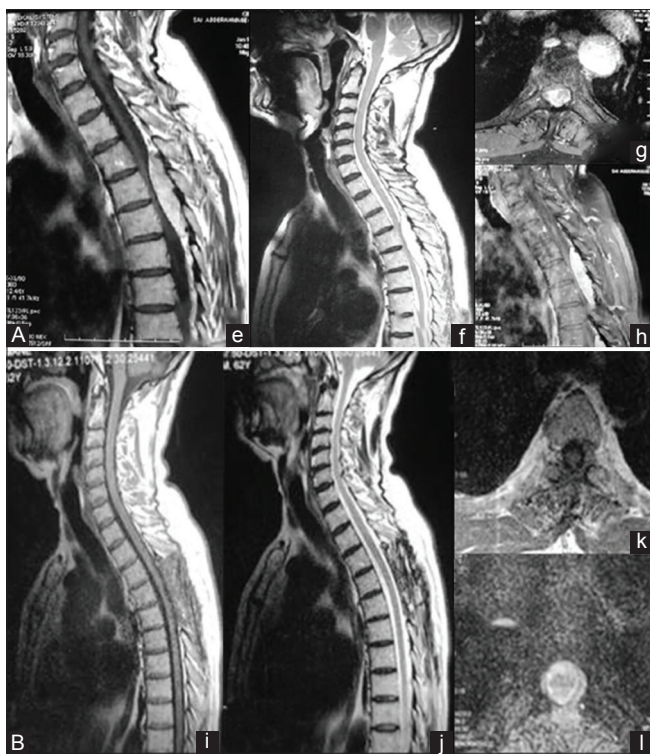
**Figure 1:** Lumbar magnetic resonance imaging of 61-year-old woman, sagittal T1-weighted fast-spin echo (a), sagittal T1-weighted fast-spin echo, fat-saturated images after contrast (b), T2-weighted fast spin-echo (c), and axial T2-weighted (d), showed a L1–L2 posterior epidural lesion with both lipomatous and vascular components and homogeneous contrast enhancement

**Table 1: Summary of clinical characteristics, management, and results of our patients**

Case	1	2	3	4	5	6	7	8	9
Age (years)	59	40	62	49	29	48	61	65	47
Sex	Female	Female	Male	Male	Male	Male	Female	Male	Female
Symptoms	Lower limb monoparesis	Paraplegia	Paraparesis	Paraparesis	Paraparesis	Paraparesis	Lumbosciatalgia	Back pain	Paraplegia
Duration of symptoms (months)	18	1	4	12	10	24	16	12	>1
Site	D5-D8	D4	D4-D6	D4-D6	D1-D8	D4-D10	L1-L2	D3-D5	L1-L4
Axial localization	Posterior	Posterior	Posterior	Posterior	Posterior	Left posterolateral	Posterior	Posterior	Posterior
Treatment	Total surgical removal	Total surgical removal	Total surgical removal	Total surgical removal	Total surgical removal	Total surgical removal	Total surgical removal	Total surgical removal	Total surgical removal
Result	Recovery	Recovery	Recovery	Recovery	Recovery	Recovery	Asymptomatic	Asymptomatic	Recovery

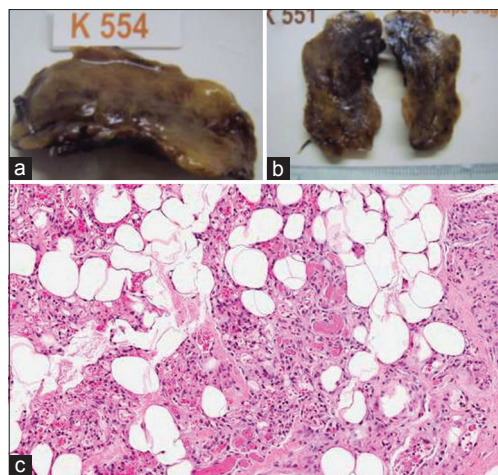
**Table 2: A comparison with published literature reports of spinal epidural angioliopomas**

	Age (years)	Sex ratio	Duration of symptoms (months)	Localization	Site	Surgery treatment	Results
Our study	51 (29-65)	5 male/4 female 1, 2	12 (1-24)	Posterior: All cases	Thoracic: 7/9 cases	100%	Total recovery 100%
Literature Authors	44.03±5.9	1.2 and 1.6	20.2±9.6	Posterior 85%	Thoracic 78%	100%	Total recovery 100%
	Gelabert et al., 2009	Akhaddar et al., 2000 Turgut et al., 1999	Kussel et al., 1989 Fernandez et al., 1994 Anson et al., 1990	Wilts et al., 1993	Akhaddar et al., 2000 Turgut et al., 1999	Howard et al., 1974 Enzinger et al., 1995 Do souto et al., 2002	Preul et al., 1993 Gelabert et al., 2009



**Figure 2:** Spinal magnetic resonance imaging in a 65-year-old woman. (A) sagittal T1-weighted (e), sagittal T2-weighted (f), axial (g), and sagittal (h) T1-weighted, showing posterior spinal epidural mass with inhomogeneous high signal on all sequences, extending from T3 to T4 and causing thecal sac compression. (B) The postoperative spinal magnetic resonance imaging in the same patient, sagittal (i) T1-weighted, sagittal (j) and axial (l) T2-weighted, axial (k) T1-weighted after contrast, showing the disappearance of the lesion

mature adipose elements.<sup>[8]</sup> Various terms including vascular lipoma, hemangioliopoma, and fibromyoliopoma have been used to describe these lesions.<sup>[5]</sup> Spinal epidural angioliopomas commonly occur in adults in the fourth and fifth decades and have female preponderance.<sup>[1,9]</sup> Few cases of pediatric spinal epidural angioliopomas have been reported.<sup>[1]</sup> The histopathogenesis of angioliopomas is unknown. They probably arise from abnormal primitive pluripotential mesenchymal cells that can differentiate into lipomatous, angiomatous, or mixed tissue.<sup>[10]</sup> Spinal angioliopomas are categorized as one of the two types: “Noninfiltrating” and “infiltrating.” In the common type, angioliopoma is encapsulated and noninfiltrating, and shows a benign prognosis. The less



**Figure 3:** (a and b) The cut surface of the tumor (the same patient) is yellowish, in places hemorrhagic, firm, and spongy. (c) Histopathology examination of the tumor. Showing admixture of mature adipose tissue and vascular elements (H and E, x40)

common type is nonencapsulated and infiltrating, showing an unfavorable prognosis.<sup>[11-13]</sup> Almost all noninfiltrating epidural angioliopomas are located in the posterior or posterolateral space of the spinal canal.<sup>[14]</sup> The infiltrating type is intramedullary or intravertebral occurrence.<sup>[13]</sup> They most frequently appear in the thoracic spine where they are called “extradural” angioliopomas since they develop between the encephalic layer of the dura mater which forms the dural sheath of the spinal cord and the osteoperiosteal layer which covers the vertebrae.<sup>[15,16]</sup> This interperiosteal dural space is improperly called the epidural space.<sup>[15,16]</sup> Pure lumbar localization is extremely rare.<sup>[17]</sup> In our cases of thoracic and lumbar angioliopomas, the tumors were in the posterior epidural space but did not show any signs of bone infiltration.

The common clinical presentations of spinal epidural angioliopomas are progressive paraparesis, back pain without radiculopathy, lower extremity sensory changes, and hyperreflexia. Sudden neurological deterioration can occur due to tumor thrombosis or hemorrhage.<sup>[6,18]</sup> Exacerbation of symptoms may occur during pregnancy and in obese patients probably because of hormonal changes and increase in a fatty component within the angioliopoma.<sup>[19]</sup> The CT appearance of spinal angioliopoma is that of a mass that is typically



hypodense relative to the spinal cord and has variable degrees of enhancement after contrast administration.<sup>[20]</sup> MRI is the investigation of choice in diagnosing spinal angiolioma.<sup>[21]</sup>

Angioliomas are composite tumors constituted by mature fat tissue associated with vascular proliferation. These findings help to explain the tumor's appearance when viewed by MRI. The observed hypersignal during T1-weighted magnetic resonance (MR) sequences strongly suggests the diagnosis and enhancement after gadolinium injection confirms the hypervascular nature of these tumors. T1-weighted MR sequences, with suppression of fat tissue, indicate that the tumors were derived from fat tissue.<sup>[21]</sup> Differential diagnoses include lipoma, hemangioma, malignant lymphoma, and nerve sheath tumor.<sup>[2]</sup> The biological behaviors of infiltrating and noninfiltrating spinal epidural angioliomas imply the need for different treatment approaches.

Noninfiltrating spinal epidural angioliomas is often encapsulated, and complete removal of the tumor ensures no recurrence and allows the improvement of neurological symptoms.<sup>[9,22]</sup> In cases of recurring or infiltrative spinal epidural angioliomas, wider resection followed by radiotherapy should be considered.<sup>[13,23]</sup>

Our experience as well as of those in the literature show that total excision of these lesions is often possible and that total recovery after local removal was obtained in all cases.

## Conclusion

The clinical course in our patients was relatively brief compared to other reports, which have described a mean duration of symptoms of 20 months, but the operative results in our cases combined with a review of the published literature leads us to suggest that the functional outcome of spinal epidural angioliomas is particularly favorable with a complete neurological recovery is if the patient was quickly operated.

## Financial support and sponsorship

Nil.

## Conflicts of interest

There are no conflicts of interest.

## References

- Gelabert-González M, Garcia-Allut A. Spinal extradural angiolioma: Report of two cases and review of the literature. *Eur Spine J* 2009;18:324-35.
- Gelabert-González M, Agulleiro-Díaz J, Reyes-Santías RM. Spinal extradural angiolioma, with a literature review. *Childs Nerv Syst* 2002;18:725-8.
- Bucy PC, Ritchey H. Klippel-Feil's syndrome associated with compression of the spinal cord by an extradural hemangiolioma. *J Neurosurg* 1947;4:476-81.
- Preul MC, Leblanc R, Tampieri D, Robitaille Y, Pokrupa R. Spinal angioliomas. Report of three cases. *J Neurosurg* 1993;78:280-6.
- Haddad FS, Abla A, Allam CK. Extradural spinal angiolioma. *Surg Neurol* 1986;26:473-86.
- Ghanta RK, Koti K, Dandamudi S. Spinal epidural angiolioma: A rare cause of spinal cord compression. *J Neurosci Rural Pract* 2012;3:341-3.
- Amlashi SF, Morandi X, Chabert E, Riffaud L, Haegelen C, Rolland Y. Spinal epidural angiolioma. *J Neuroradiol* 2001;28:253-6.
- Howard WR, Helwig EB. Angiolioma. *Arch Dermatol* 1960;82:924-31.
- Hungs M, Paré LS. Spinal angiolioma: Case report and literature review. *J Spinal Cord Med* 2008;31:315-8.
- Ehni G, Love JG. Intraspinal lipomas: Report of cases; review of the literature, and clinical and pathologic study. *Arch Neurol Psychiatry* 1945;53:1-28.
- Turgut M. Spinal angioliomas: Report of a case and review of the cases published since the discovery of the tumour in 1890. *Br J Neurosurg* 1999;13:30-40.
- Pinto-Rafael JJ, Vázquez-Barquero A, Martín-Laez R, García-Valtuille R, Sanz-Alonso F, Figols-Guevara FJ, *et al.* Spinal angiolioma: Case report. *Neurocirugía (Astur)* 2002;13:321-5.
- Lin JJ, Lin F. Two entities in angiolioma. A study of 459 cases of lipoma with review of literature on infiltrating angiolioma. *Cancer* 1974;34:720-7.
- Miyamoto Y, Naka J, Asahi S, Mikami T, Sawada H, Sano K, *et al.* Spinal extradural angiolioma. A report of two cases and review of the literature. *Kanto Seisaishi* 2009;40:420-4.
- Andaluz N, Balko G, Bui H, Zuccarello M. Angioliomas of the central nervous system. *J Neurooncol* 2000;49:219-30.
- Bardosi A, Schaake T, Friede RL, Roessmann U. Extradural spinal angiolioma with secretory activity. An ultrastructural, clinico-pathological study. *Virchows Arch A Pathol Anat Histopathol* 1985;406:253-9.
- Rocchi G, Caroli E, Frati A, Cimatti M, Savlati M. Lumbar spinal angioliomas: Report of two cases and review of the literature. *Spinal Cord* 2004;42:313-6.
- Akhaddar A, Albouzi A, Elmostarchid B, Gazzaz M, Boucetta M. Sudden onset of paraplegia caused by hemorrhagic spinal epidural angiolioma. A case report. *Eur Spine J* 2008;17 Suppl 2:S296-8.
- Diyora B, Nayak N, Kukreja S, Kamble H, Sharma A. Thoracic epidural angiolioma with bilateral multilevel extraspinal extensions: A rare entity. *Neurol India* 2011;59:134-6.
- Matsushima K, Shinohara Y, Yamamoto M, Tanigaki T, Ikeda A, Satoh O. Spinal extradural angiolioma: MR and CT diagnosis. *J Comput Assist Tomogr* 1987;11:1104-6.
- Yamashita K, Fuji T, Nakai T, Hamada H, Kotoh K. Extradural spinal angiolioma: Report of a case studied with MRI. *Surg Neurol* 1993;39:49-52.
- Okuyama K, Watanabe M, Matsumoto M, Maruiwa H, Chiba K, Fujimura S, *et al.* Spinal extradural angiolioma. A report of five cases. *Spine Spinal Cord* 2000;11:196.
- Nagano S, Ijiri Y, Yone K, Aketomi E, Nakahara S, Sako T. Extradural angiolioma with thoracic myelopathy. A case report. *Seikeigeka Saigaigeka* 2000;49:315-6.