

Craniofacial Trauma in Pediatric Patients Following Wincrowing Blade Injury-review of Literature

Abstract

In developing countries, during the harvest season, winnower blade injuries occur very frequently in children and results in lifelong disability. Nine children were managed during 1 month, all resulting due to winnower blade induced craniofacial trauma. PubMed search for “fan blade injury” showed two case series and three case reports. In our study, 88% had compound depressed fracture; brain matter leak in 56%, cerebrospinal fluid (CSF) leak alone in 22%. 66.7% had injury involving the frontal bone. Two patients had eye injury with visual loss. Seven underwent debridement craniectomy, five augmentation duroplasty and three contusectomy. All had vegetable material, sand particles. Complications in 66.6% with two cases of CSF leak settled with lumbar drain, one case of CSF otorrhea, 22.2% of wound infection, 44.4% wound dehiscence requiring redebridement and suturing in five patients. Two patients had postoperative seizures, two patients had hemiparesis both improved. Two low Glasgow Coma Scale remained so on postoperative period. One case of subdural empyema needed debridement and duroplasty with glue. No mortality noted. These findings were consistent with previous reports. Follow-up at 1.5 months showed good functional recovery. Early surgery debridement, steps to minimize postoperative infections, identifying putative risk factors early in the management are the principles of a successful treatment regimen.

Keywords: *Craniofacial injury, debridement craniectomy, complications, winnower fan blade injury*

Introduction

Wincrowing machines are a part of any farmer’s armamentarium during the harvest season. In developing countries, including India, many farmers plagued by poverty, illiteracy, cannot afford mechanized machines and hence are left with hand operated machines with no regulatory standards during its production by a blacksmith. Usage of these machines increases during the harvest season and hence an exponentially increased risk of injury to craniofacial regions. Children are the common victim of this pattern of injury as these machines are kept unprotected by many ignorant farmers with no barricades around them. There are anecdotal reports and case series representing various spectrums of craniofacial injuries occurring due to wincrowing machines. Although the majority of these injuries are nonfatal, they require surgical management with or without which multiple complications are doomed to happen. We present a series of nine children affected by wincrowing machine injury including mechanism of

injury, clinical and neurosurgical issues associated and management of multiple complications arising out of it.

Material and Methods

Demographic parameters

Age and sex

Nine children in age group of 1.5 years to 8 years were admitted at neurosurgery ward, trauma center, King George’s Medical University, Lucknow following trauma in a single month of November 2015 [Table 1]. Seven of them were male and two were female kids.

Clinical presentation

90% of the cases presented within 12 h of injury. Most of the patients presented to us in Glasgow Coma Scale (GCS) 15/15 ($n = 6$). Two patients of GCS six and seven needed airway protection. All cases had a compounding wound (100%) [Figure 1] with an additional brain matter leak in five patients (56%) [Figure 2], cerebrospinal fluid (CSF) leak alone in two patients (22%) and no leak in two patients (22%) through

**Harsha Huliyyappa,
Balakrishna Ojha,
Anil Chandra,
Sunil Kumar Singh,
Chhitij Srivastava**

*Department of Neurosurgery,
King George’s Medical
University, Lucknow,
Uttar Pradesh, India*

Address for correspondence:

*Dr. Harsha Huliyyappa,
Department of Neurosurgery,
King George’s Medical
University, Lucknow - 226 003,
Uttar Pradesh, India.
E-mail: harsha_huliyyappa@
yahoo.com*

Access this article online

Website: www.asianjns.org

DOI: 10.4103/1793-5482.180880

Quick Response Code:



How to cite this article: Huliyyappa H, Ojha B, Chandra A, Singh SK, Srivastava C. Craniofacial trauma in pediatric patients following wincrowing blade injury-review of literature. *Asian J Neurosurg* 2018;13:212-6.

This is an open access journal, and articles are distributed under the terms of the Creative Commons Attribution-NonCommercial-ShareAlike 4.0 License, which allows others to remix, tweak, and build upon the work non-commercially, as long as appropriate credit is given and the new creations are licensed under the identical terms.

For reprints contact: reprints@medknow.com

Table 1: Demographic profile, clinical, radiological, and operative findings of 9 patients

Age/sex	Associated injuries	GCS	NCCT	Surgery
8 years/female	Neck abrasions	15/15	Left frontal compound depressed fracture Brain matter leak	Debridement craniectomy AD using FL
2 years/female	Left orbital and globe injury with complete loss of vision	15/15	Left frontoorbital compound depressed fracture CSF leak	Debridement craniectomy Primary dural closure
6 years/male	Nil	E3V4M5	Left parietal compound depressed fracture with contusion Brain matter leak	Debridement craniectomy Debridement contusectomy AD using FL
18 months/male	Left EAC laceration , CSF otorrhea	15/15	Left temporal compound depressed fracture Brain matter leak Wound dehescence with subdural empyema	Debridement craniectomy AD using FL Redebridement with AD using opposite FL
3 years/male	Right globe injury Loss of vision	15/15	Right frontoorbital compound depressed fracture with contusion Brain matter leak	Debridement craniectomy Debridement contusectomy Ad using PC
7 years/male	Left femur fracture Left humerus fracture	E1VETM4	Left fronto parietal compound fracture Multiple small contusions No leak	Wound debridement and suturing (E4V3M5)
3 years/male	Nil	15/15	Left frontal compound depressed fracture Brain matter leak	Debridement craniectomy AD using FL
12 years/male	Multiple neck abrasions Right maxillary bone fracture	E2VTM4	Right parietal compound depressed fracture Left occipital contusion CSF leak SAH	Debridement craniectomy Primary dural closure (E2VTM4)
5 years/male	Left radius and Ulna fracture	15/15	Left frontal compound depressed fracture Left orbital rim fracture No leak	Wound debridement and suturing

AD – Augmentation duroplasty; FL – Facia lata; PC – Pericranium; EAC – External auditory canal; CSF – Cerebrospinal fluid; GCS – Glasgow coma scale; MCCT – Noncontrast computed tomography; SAH – Subarachnoid hemorrhage

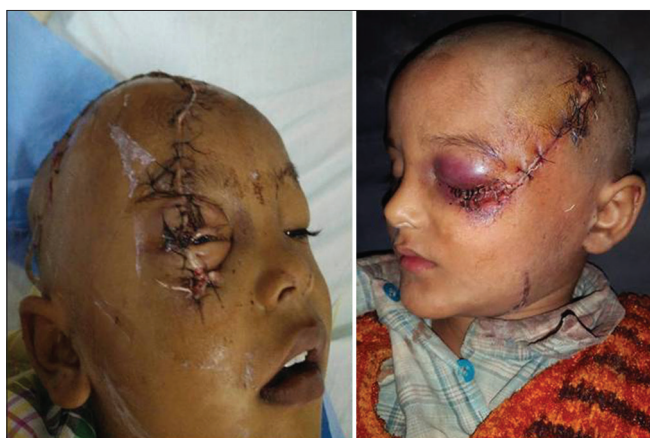

Figure 1: Compound depressed fracture with orbital extension with globe injury with cerebrospinal fluid leak (right)

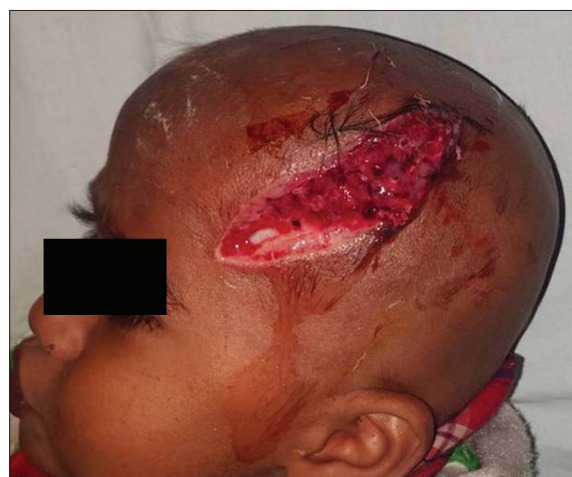

Figure 2: Left frontal compound depressed fracture with brain matter leak with evident vegetable matter

the compound depressed fracture. All patients had vegetable material, straw and sand particles in the wound. Depressed fracture involved mainly the frontal bone ($n = 6$), parietal bone ($n = 2$) and temporal bone ($n = 1$). Three patients had

associated orbital fracture; two of them had subconjunctival hemorrhage, hyphema, vitreal hemorrhage resulting in complete loss of vision in the injured eye. One had corneal

laceration with irideal prolapse. Two patients had associated extensive neck abrasions. Two patients had long bone fractures and maxillary bone fracture. Patient with temporal bone fracture had associated lacerated ear cartilage with CSF otorrohea. Three patients presented with hemiparesis.

Mode of injury

In our study, 8 (88%) patients sustained injury due to inadvertent running into an unguarded running winnowing machine while playing around the house or being chased by a pet animal. In one case, the kid had ran into the still blades while running around at night. All had the first impact on the frontoparetotemporal area of the skull with associated facial area in some. Long bone fractures occurred as the kids were thrown off by the machine. Patients who had neck abrasions were due to partial strangulation by the clothes that got stuck in the blades.

Mechanism of injury

On close examination, each blade appears like a ceiling fan blade but is much sharper, heavier, rusted, and studded with vegetable matter. It is operated by turning the handle on the rear side. The unguarded fan happens turns at a sufficient speed on rotation and cannot be seen by small kids during these revolutions. As they have a low ground clearance during revolutions (1–2 feet from ground), majority of kids would be hit or sliced through the head, orbit and upper face when the blades are moving from 12° clock to 6° clock positions and has an impact equivalent to mechanized fan blades/machete so as to cause deep penetrating trauma [Figure 3].

Radiological findings

Noncontrast computed tomography (NCCT) with three-dimensional reconstruction showed a depressed fracture in eight patients (88%) with external protrusion of brain matter in four patients [Figures 4 and 5]. Intraparenchymal bone fragments were seen in six

patients (66.7%). Three patients had contusions large enough needing evacuation. One patient had a compound fracture without depressed fragments. The majority of the orbital bone fractures involved the superior orbital rim and the roof of the orbit. One patient had associated subarachnoid hemorrhage with ischemic areas as his neck got strangulated. No patients had epidural hematoma/subdural hemorrhage/pneumocephalus, posterior fossa injury, or spine injury.

Surgical management

All received tetanus and antibiotic prophylaxis. All patients were operated within 6 h of arrival. Out of seven debridement craniectomy, five augmentation duroplasty was done as the dura was contused and lacerated (facia lata repair = 4, pericranium repair = 1), two needed additional fibrin glue, three underwent minimal debridement contusectomy and removal of hematoma with satisfactory postoperative NCCT [Figure 6]. The majority of the patients had a foreign body like grass and sand particles which were removed with copious saline irrigation. All patients received postoperative ceftriaxone, amikacin, and metronidazole for 5 days with a regular dressing of the wound. One patient with temporal region laceration had to be reoperated for wound dehescence and found to have subdural empyema needing evacuation and repeat augmentation duroplasty with opposite side fascia lata. As this patient had cut through of repeatedly sutured wound, healing by secondary intention was successfully attempted. One patient had brain swelling per-operatively and, therefore, required larger craniectomy with augmentation duroplasty.

Complications

Six (66.6%) patients developed complications in the perioperative period. Postoperatively two patients needed




Figure 3: Left-hand: Author sketch on an approximate height of the machine and the patients. Right-hand upper inset: Winnower machine. Right-hand lower inset: Machine being used for winnowing

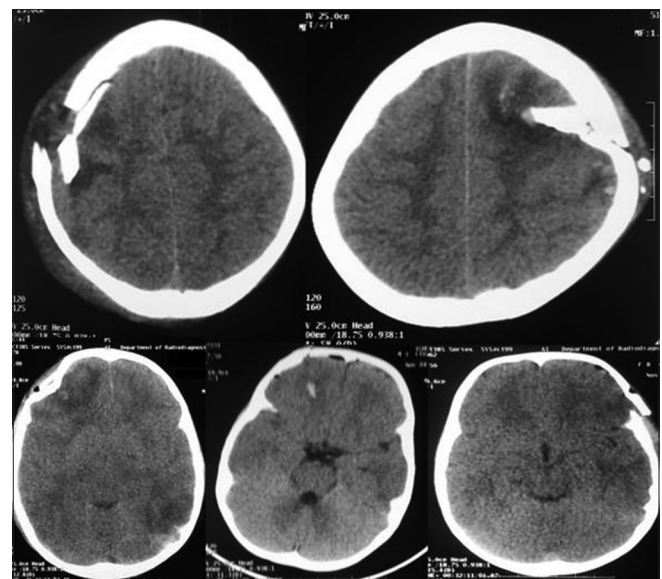

Figure 4: Preoperative noncontrast computed tomography head of five patients showing classically depressed fracture with brain matter herniation

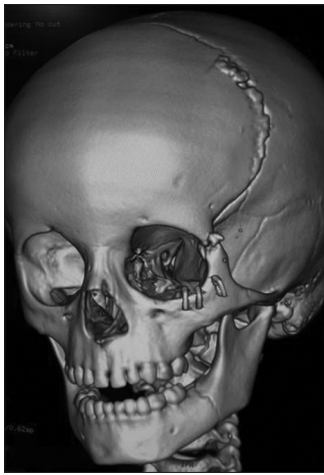


Figure 5: Noncontrast computed tomography with three-dimensional reconstruction showing classically depressed fracture with fracture line extending onto the left orbital wall

lumbar drain (surgeware) for wound site CSF leak; and for CSF otorrhea [Table 2]. Wound infection occurred in 2 (22.2%) patients with *Staphylococcus Aureus* growth on culture. One of them also had subdural empyema with a base of skull dural tear at temporal region which was closed with fascia lata graft and glue. This patient was started on imipenem and vancomycin as per culture sensitivity report. Pus did not yield any fungus or mycobacterial growth. Both recovered well. No mortality was noted. Wound dehiscence occurred in four patients (44.4%) requiring resulting. Two patients showed considerable improvement of hemiparesis (power 4/5) in postoperative period. Both patients with globe injury persisted to have vision loss at the time of discharge. Two patients had postoperative seizure in spite of phenytoin but did not recur. Only one patient in low GCS showed improvement at the time of discharge.

Follow-up

At follow-up period of 1.5 months, all patients had healed the wound with a return to normal activity. There was complete resolution of hemiparesis in 1 patient. Both low GCS patients remained so. No mortality was witnessed.

Discussion

In countries where agriculture remains a major form of occupation, occupation-related injuries and hazards are of major concern, especially during the harvest seasons. We witnessed a total of 9 cases of winnower machine injury in a single month following the harvest of Kharif crops (July to October). During the harvest season, the grain needs to be separated from the straw and husk by a process of “Winnowing.” Winnowers, which are basically a hand, operated large blowing fans help in blowing away the lighter husk from the thrashed grains. In Indian scenario, so as to prevent stealth of valuable crops, this process of winnowing is carried out near the settlements rather than

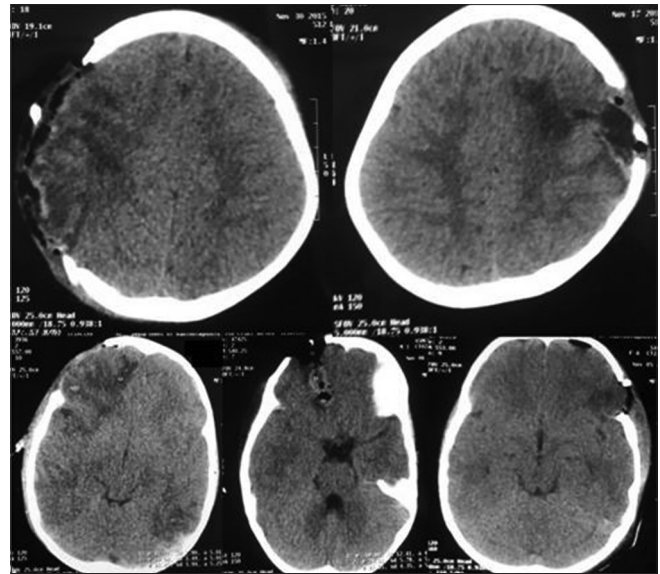


Figure 6: Postoperative noncontrast computed tomography of the five patients in Figure 4 depicting adequate debridement and decompression

Table 2: Postoperative complications

Complications	Number of patients
Wound infection	2
Wound dehiscence	4
Wound debridement	2
Seizures	2
Persistent hemiparesis	2
CSF otorrhea	1
Wound CSF leak	2
Persistent low GCS	2

CSF – Cerebrospinal fluid; GCS – Glasgow coma scale

in the fields allowing an unusual yet dangerous proximity to the areas of child activity. Winnowers acquired from blacksmiths are substandard, with no proper reinforced safety measures. In one case, the injury occurred when the child accidentally fell on the blade when it was not functioning; revealing the fragile nature of the facial and skull bones in the children.

A PubMed search was made with keywords of fan blade injury, yielding three case series and three case reports of such injuries. However, only one case series and one case report were suggestive of winnower fan blade injury.

A study by Mohan and Patel showed that children below 14 years of age were involved in 16% of all agricultural injuries in the northern part of India. Nearly 30% and 40% of the injuries among 0–14 years and 0–4-year-old children were caused by blade related machines, respectively.^[1] Kumar et al. had >90% of craniocerebral injuries following winnower blade injuries in children of tender age 13 years or less with a mean age of 8 years.^[2]

Though the majority of our cases were nonfatal, the machine causes a significant degree of high velocity,

sharp, deep penetrating injuries.^[3,4] Associated strangulation resulting in possible ischemic damage was seen in two cases in our study which has not been reported before. The majority of the studies shows that adhering to principles such as early surgery, removal of contaminants from the wound, thorough debridement with dural repair (primary/augmentation) during the primary treatment would give the maximum benefit and best possible results.^[2,5] Like in many studies, the majority of the injuries in our patient occurred in the fronto-parietal and facial regions. Postoperative wound infections and the CSF leak are the two dreaded complications which add on to the prolonged hospital stay and morbidity in many studies.^[6] We had a higher postoperative wound infection rates of 22.2% against 12.9% in a study by Kumar *et al.* and we attribute this to delay at presentation.^[2] Despite the risk of fungal infection by the vegetable material, antifungal was not initiated in any of our case and all recovered well with just debridement and antibiotics alone. The majority of the western literature on compound depressed fracture describes clean wound status and hence are less likely to harbor foreign bodies. Craniectomy can be avoided in such cases with good postoperative results and avoids the requirement of cranioplasty at a later date.^[4] Factors which portend possibility of complications are compound fractures, the presence of dirt, intracranial lesions, cortical laceration, unilateral pupillary dilatation, admission GCS score of 8 or less, delay in surgery >8 h and deeply depressed bone fragments.^[6,7] Early surgery and proper debridement with antibiotic cover play an important role in reducing the rate of wound infection.^[6,7]

Finally, farmers of today need to be educated regarding the safe and effective methods of agricultural practice through special programs. Avoiding usage of dangerous equipment in the vicinity of kids is of utmost importance which needs to be reinforced. Proper safety barriers and fencing while using such instruments should be highlighted. The National Institute for Occupational Safety and Health, USA is one such program that focuses on traumatic occupational injury research and prevention program to reduce the incidence of worker injuries and deaths due to trauma. The program strives to fulfill its mission through the following: High-quality research, practical solutions, partnerships and research to practice.^[8] Studies from Indian subcontinent always an emphasis on this fact of adapting preventive measures despite which unhealthy agricultural practices still flourish unabated.^[5] Design solutions for safety must be considered and retrofitting of existing machines with safety cages must be done to prevent such inadvertent injuries.^[9] Emphatically, these are operated by young men or even adolescents who fail to foresee some dangerous

situations [Figure 3]. Sometimes, smaller kids are drawn toward for the reason that it is run by another kid! In our case, 5 of them were operated by a kid.

Conclusion

Early surgery debridement, steps to minimize postoperative infections, identifying putative risk factors early in the management are the principles of a successful treatment regimen. Nevertheless, educating parents during this short period regarding safe agricultural practices and the importance of early hospitalization needs to be addressed in all such cases so as to prevent future injuries.

Declaration of patient consent

The authors certify that they have obtained all appropriate patient consent forms. In the form the patient(s) has/have given his/her/their consent for his/her/their images and other clinical information to be reported in the journal. The patients understand that their names and initials will not be published and due efforts will be made to conceal their identity, but anonymity cannot be guaranteed.

Financial support and sponsorship

Department of Neurosurgery, King George's Medical University, Lucknow, India.

Conflicts of interest

There are no conflicts of interest.

References

1. Mohan D, Patel R. Design of safer agricultural equipment: Application of ergonomics and epidemiology. *Int J Ind Ergon* 1992;10:301-9.
2. Kumar A, Shankar R, Pandey RP, Keshri V, Singh K, Sharma V. Five years' experience at a single centre of craniocerebral injury from winnowing fan blades. *J Clin Neurosci* 2010;17:178-81.
3. Bouckaert MM. Fan blade injury. *S Afr Med J* 1999;89:837-9.
4. de Villa GH, Nicholoff TJ Jr. Fan blade injury of the face. *J Philipp Dent Assoc* 1998;50:32-5.
5. Kaif M, Singh G, Husain M, BK Ojha, Chandra A. Winnowing fan blade head injury. *Indian J Neurotrauma* 2008;5:49-50.
6. Alias A, Krishnapillai R, Teng HW, Abd Latif AZ, Adnan JS. Head injury from fan blades among children. *Asian J Surg* 2005;28:168-70.
7. Ersahin Y, Mutluer S, Mirzai H, Palali I. Pediatric depressed skull fractures: Analysis of 530 cases. *Childs Nerv Syst* 1996;12:323-31.
8. The National Institute for Occupational Safety and Health (NIOSH). NIOSH Program Portfolio (Traumatic Injury). Available from: <http://www.cdc.gov/niosh/programs/ti/>. [Last reviewed on 2015 Sep 22].
9. Kumar A, Varghese M, Mohan D. Equipment related injuries in agriculture: An international perspective. *J Inj Prev Control* 2000;7:175-86.