

## CASE REPORT

# Resolution of aspergillosis in neuroimaging of an immunocompromised patient with pulmonary and cerebral lesions

Mohsen Meidani, Atousa Hakamifard<sup>1</sup>, Amir Hossein Sarrami<sup>2</sup>

Acquired Immunodeficiency Research Center, <sup>1</sup>Nosocomial Infection Research Center, <sup>2</sup>Department of Radiology, Isfahan University of Medical Sciences, Isfahan, Iran

## ABSTRACT

Central nervous system (CNS) aspergillosis is uncommon and considered the most lethal form of aspergillosis. Indeed, current therapeutic strategies such as combination antifungal regimen, neurosurgical resection of infected tissue, and removal of infection source fail to improve the unsatisfactory prognosis of CNS aspergillosis in the majority of the patients. The authors describe a case of chronic pulmonary aspergillosis with concomitant CNS lesions that dramatically responded to antifungal therapy and the CNS lesions resolved in follow-up imaging.

**Key words:** Aspergillosis, *Aspergillus*, central nervous system, voriconazole

## Introduction

Aspergillosis of central nervous system (CNS) is uncommon. It occurs mainly in the setting of disseminated infection (essentially from a pulmonary source), as well as from direct extension, from the paranasal sinuses or direct inoculation through trauma and neurosurgery.<sup>[1]</sup> CNS aspergillosis is seen almost exclusively in immunocompromised patients and considered the most lethal form of aspergillosis. Indeed, current therapeutic strategies such as combination antifungal regimen, neurosurgical resection of infected tissue, and removal of infection source fail to improve the unsatisfactory prognosis of CNS aspergillosis in the majority of the patients.<sup>[2,3]</sup>

In this paper, the authors describe a case of chronic pulmonary aspergillosis (CPA) with concomitant CNS lesions that dramatically responded to antifungal therapy and the CNS lesions resolved in follow-up imaging.

## Case Report

A 53-year-old smoker man was admitted to our hospital with a 5 months history of productive cough associated with intermittent episodes of hemoptysis. The patient was under treatment with prednisone for chronic headache since 2 years before. On admission, physical examination was not remarkable. Laboratory study showed mild leukocytosis and high levels of serum erythrocyte sedimentation rate (ESR) and C-reactive protein (CRP) (188 mm and 118 mg/dL, respectively). In chest X-ray, a cavitary lesion with air fluid level in left upper lobe was seen which was better demonstrated in following thorax computed tomography (CT) scan [Figures 1 and 2].

Microscopic study of sputum specimen did not show any microorganism in different staining. As the patient complained of headache, brain imaging was also performed. Brain magnetic resonance imaging (MRI) revealed multiple ring enhancement lesions with peripheral edema in right temporoparietal lobe and left cerebellar hemisphere

Access this article online	
Quick Response Code:	Website: www.asianjns.org
	DOI: 10.4103/1793-5482.175644

### Address for correspondence:

Dr. Atousa Hakamifard, Nosocomial Infection Research Center, Isfahan University of Medical Sciences, Isfahan, Iran.  
E-mail: atousa\_medline@yahoo.com

This is an open access article distributed under the terms of the Creative Commons Attribution-NonCommercial-ShareAlike 3.0 License, which allows others to remix, tweak, and build upon the work non-commercially, as long as the author is credited and the new creations are licensed under the identical terms.

**For reprints contact:** reprints@medknow.com

**How to cite this article:** Meidani M, Hakamifard A, Sarrami AH. Resolution of aspergillosis in neuroimaging of an immunocompromised patient with pulmonary and cerebral lesions. Asian J Neurosurg 2016;11:456-7.

[Figures 3 and 4]. Echocardiogram and blood culture did not show any evidence of endocarditis.

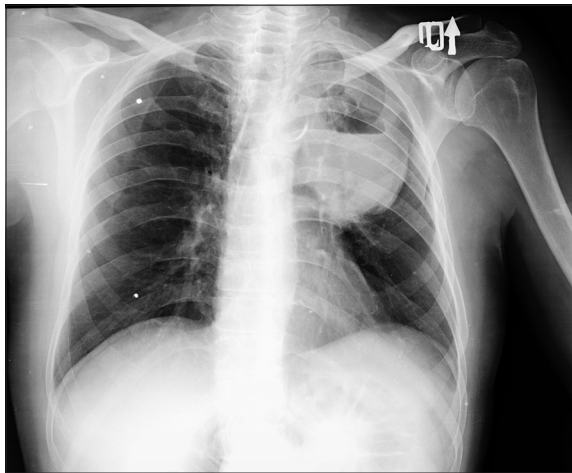
In next step, the patient underwent a CT-guided percutaneous biopsy of the lung lesion. Considering clinical manifestation, laboratory data, and imaging findings, an empiric antimicrobial regimen (intravenous meropenem, vancomycin, and voriconazole) was started. Histopathological study of the lung specimen revealed septated hyaline hyphae with dichotomous acute angle branching among the areas of necrosis surrounded by fibrotic tissue and inflammation. The findings were compatible with the diagnosis of CPA with concomitant CNS lesions. Other microscopic studies for detecting further microorganism, include gram staining, acid-fast staining, and tissue culture, were negative. Hence, the administration of meropenem and vancomycin was stopped after 3 weeks, and treatment with voriconazole was continued. Control chest X-ray and brain MRI were done 2 weeks and also 4 weeks later, which revealed complete resolution of cerebral and pulmonary

lesions [Figures 5 and 6]. At the end of the 4<sup>th</sup> week of treatment, patient's symptoms include productive cough and headache were resolved, and the serum level of ESR and CRP diminished to 19 mm and 4 mg/dL, respectively.

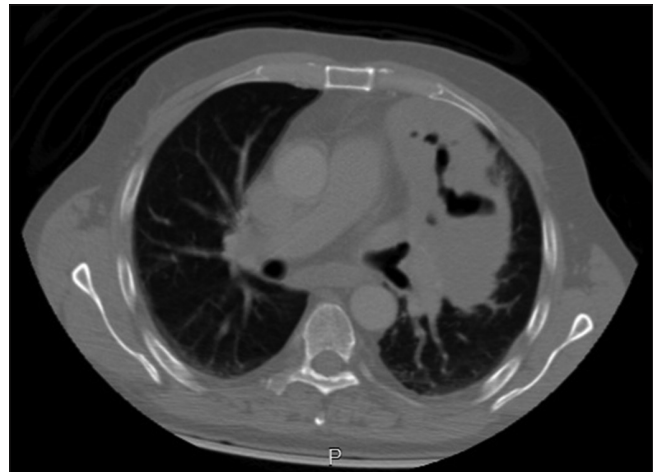
Intravenous antifungal therapy continued for 12 weeks with careful clinical and radiologic follow-up.

## Discussion

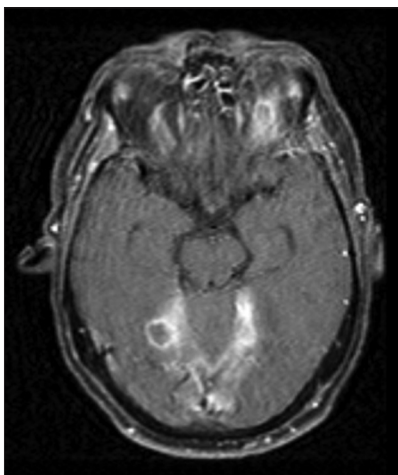
In this report, a patient with CPA and concomitant cerebral lesions was described. CPA implies a pattern of aspergillosis in immunocompetent patients that usually progresses slowly over weeks or months. It is characterized by the formation of at least one pulmonary cavity, positive related microscopic or serologic evidence, and the presence of clinical symptoms. Clinical symptoms include weight loss, fatigue, chronic productive cough, hemoptysis, and/or shortness of breath.<sup>[4]</sup>



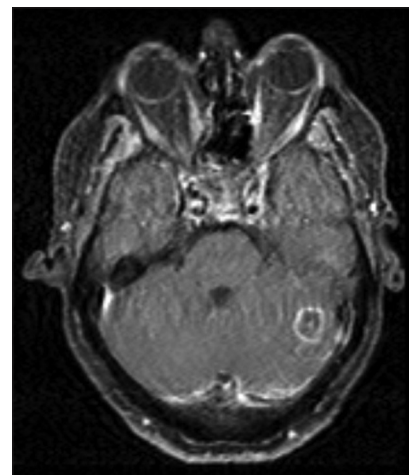
**Figure 1:** Upright chest X-ray showed a consolidation with cavitation in left upper lobe



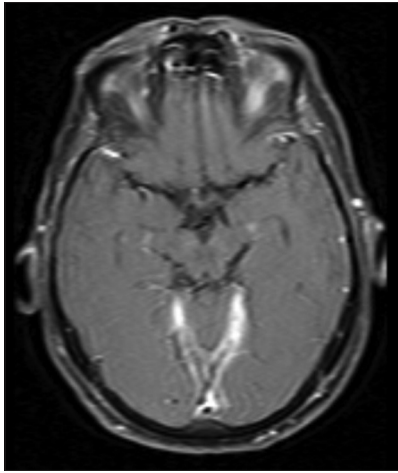
**Figure 2:** Axial contrast-enhanced chest computed tomography scan showed a consolidation with cavitation in left upper lobe



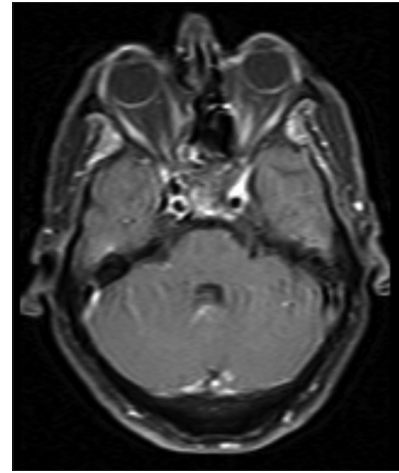
**Figure 3:** Axial contrast-enhanced T1-weighted image showed a ring enhancement lesion in right temporooccipital lobe



**Figure 4:** Axial contrast-enhanced T1-weighted image showed a ring enhancement lesion in left cerebellar hemisphere



**Figure 5:** In axial contrast-enhanced T1-weighted image at the end of the 4<sup>th</sup> week of treatment the lesion was resolved



**Figure 6:** In axial contrast-enhanced T1-weighted image at the end of the 4<sup>th</sup> week of treatment the lesion was resolved

The major predisposing factors for developing CPA are underlying lung disease (such as tuberculosis and chronic obstructive pulmonary disease) and various degrees of immune dysfunction secondary to the conditions such as diabetes mellitus, alcoholism, and corticosteroid consumption.<sup>[5]</sup> Our patient was under long-term treatment with prednisone for chronic headache. Corticosteroids have been introduced as a risk factor for both invasive aspergillosis and CPA.<sup>[6]</sup>

CNS involvement of aspergillosis is a diagnostic and therapeutic challenge; since the clinical presentation is nonspecific and the neuroradiologic findings are similar to other CNS fungal, bacterial, and mycobacterial infections, and also brain tumors.<sup>[1,2]</sup>

In our patient, multiple ring enhancement lesions were seen in CT scan and MRI of brain. Histopathological study of specimens obtained from biopsy of lung lesion was leading for the diagnosis of aspergillosis. ESR and CRP are nonspecific inflammatory markers in CPA and are usually elevated. Their main role is in the monitoring during treatment.<sup>[4]</sup>

In this patient, intravenous antifungal therapy alone and without surgical intervention resulted in significant clinical improvement and decrease inflammatory markers. We believe that if the fungal abscesses were secondarily infected with bacteria, the lesions would relapse or would not resolve primarily with pure antifungal treatment. Duration of standard antibiotic regimen for bacterial brain abscess (without surgery) in an immunocompromised patient is at least 8 weeks,<sup>[7]</sup> while we stopped meropenem and vancomycin within 3 weeks.

The course of resolution of lesions in brain MRI was dramatic. All cerebral and cerebellar lesions were resolved within a month. We continued intravenous treatment for 12 weeks and then followed the patients with oral antifungal treatment. After 6 months, no recurrence was observed.

We described a case that was unusual in three respects: First, the patient had minimal neurologic symptom despite multiple cerebral and cerebellar lesions. This can be due to the lack of inflammatory response because of the state of immune dysfunction and receiving high cumulative dose of corticosteroid. Second, the involvement of cerebellum in CNS aspergillosis is very rare. Aspergillosis has a predilection for the involvement of anterior and middle cranial fossa.<sup>[3]</sup> Third, this patient showed a dramatic response to antifungal therapy alone. In today's medicine, neurosurgical resection of infected tissue is frequently performed as an adjuvant to antifungal therapy of CNS aspergillosis.<sup>[8]</sup> However, in this case surgical intervention was not required.

### Acknowledgment

We gratefully acknowledge all the academic staff of Infectious Diseases Department and Radiology Department of Isfahan University of Medical Sciences.

### Financial support and sponsorship

Nil.

### Conflicts of interest

There are no conflicts of interest.

### References

1. Segal BH. Aspergillosis. *N Engl J Med* 2009;360:1870-84.
2. Nadkarni T, Goel A. Aspergilloma of the brain: An overview. *J Postgrad Med* 2005;51 Suppl 1:S37-41.
3. Chen S, Pu JL, Yu J, Zhang JM. Multiple *Aspergillus* cerebellar abscesses in a middle-aged female: Case report and literature review. *Int J Med Sci* 2011;8:635-9.
4. Denning DW, Riniotis K, Dobrashian R, Sambatakou H. Chronic cavitary and fibrosing pulmonary and pleural aspergillosis: Case series, proposed nomenclature change, and review. *Clin Infect Dis* 2003;37 Suppl 3:S265-80.
5. Guinea J, Torres-Narbona M, Gijón P, Muñoz P, Pozo F, Peláez T, et al. Pulmonary aspergillosis in patients with chronic obstructive pulmonary disease: Incidence, risk factors, and outcome. *Clin Microbiol Infect* 2010;16:870-7.

6. Palmer LB, Greenberg HE, Schiff MJ. Corticosteroid treatment as a risk factor for invasive aspergillosis in patients with lung disease. *Thorax* 1991;46:15-20.
7. Helweg-Larsen J, Astradsson A, Richhall H, Erdal J, Laursen A, Brennum J. Pyogenic brain abscess, a 15 year survey. *BMC Infect Dis* 2012;12:332.
8. Koshy R, Malhotra P. Treatment of primary aspergilloma of the central nervous system in a diabetic immunocompetent patient with surgical resection and voriconazole: A case report and review of the literature. *Turk Neurosurg* 2011;21:641-4.

