

CASE REPORT

Multiple spinal extradural arachnoidal cysts: An uncommon cause of thoracic cord compression

Raghavendra Nayak, Anupkumar Chaudhuri, Shahid Sadique, Sanjeev Attry

Department of Neurosurgery, Bangur Institute of Neurosciences, Kolkata, West Bengal, India

ABSTRACT

Spinal extradural arachnoid cysts are one of the rare causes of symptomatic spinal cord compression. Among them, occurrence of multiple cysts at the same spinal segment is rarely described in the literature. They appear to be extradural outpouchings of arachnoid that communicate with the intraspinal sub-arachnoid space through a small defect in the dura, filled by cerebrospinal fluid. Pathogenesis of these lesions is still unclear. Surgical excision is considered as the gold standard treatment. We present a 7-year-old female child who presented with spastic paraparesis. Her magnetic resonance imaging showed a thoracic posterior extradural arachnoid cyst, whereas, intraoperatively we found multiple cysts, which were excised completely. Neurological symptoms gradually recovered after surgical decompression.

Key words: Dural defect, paraparesis, spinal extradural arachnoid cyst

Introduction

Spinal extradural arachnoid cyst is a relatively rare disease entity that accounts for approximately 1-3% of all primary spinal space-occupying lesions.^[1] Occurrence of multiple arachnoid cysts at a single spinal segment is rarely described in the literature. Causes of spinal extradural arachnoid cysts remain unclear. They appear to be extradural outpouchings of arachnoid that communicate with the intraspinal sub-arachnoid space through a small defect in the dura, filled by cerebrospinal fluid (CSF). These cysts are most commonly located in the thoracic spine, followed by the lumbosacral junction and predominantly affect males. The most common presenting symptoms are pain, paresthesias, intermittent claudication and variable degrees of spastic weakness.^[2] Surgical resection of symptomatic lesion results in complete cure or major neurological improvement.

Case Report

A 7-year-old female child presented with 8 months history of progressive bilateral ascending numbness and weakness of

lower extremities. She had become bedridden in last 2 months and had developed urinary incontinence few days prior to admission. Neurological examination revealed presence of spastic paraparesis along with reduced sensation for all modalities below the nipples. Bilateral knee-jerk and ankle jerks were exaggerated with ankle clonus. Magnetic resonance imaging (MRI) of the dorsal spine showed a cystic lesion with signal intensities similar to CSF, extending from D1 to D7 vertebra levels [Figures 1 and 2]. Foraminal extensions of the lesion were also noted [Figure 3]. Diagnosis of extradural arachnoid cyst was made, and surgery was advocated.

Midline dorsal laminectomy was done from D1 to D7 vertebra. Intraoperatively, we found the presence of multiple lesions (nearly 14 in numbers) which were in communication with the intradural space, which was an unexpected and a rare finding [Figure 4]. All the cysts were excised after ligating the pedicles [Figure 5]. Postoperatively the patient showed a significant neurological improvement.

Discussion

Spinal extradural arachnoid cyst that accounts for approximately 1-3% of all primary spinal space-occupying lesions, is a

This is an open access article distributed under the terms of the Creative Commons Attribution-NonCommercial-ShareAlike 3.0 License, which allows others to remix, tweak, and build upon the work non-commercially, as long as the author is credited and the new creations are licensed under the identical terms.

For reprints contact: reprints@medknow.com

| Access this article online | |
|---|----------------------------------|
| Quick Response Code: | Website: www.asianjns.org |
|  | DOI: 10.4103/1793-5482.150004 |

Address for correspondence:

Dr. Raghavendra Nayak, Raghavendra Nilay, Vandige, Ankola, Uttara Kannada - 581 357, Karnataka, India.
E-mail: nayakraghu@gmail.com

How to cite this article: Nayak R, Chaudhuri A, Sadique S, Attry S. Multiple spinal extradural arachnoidal cysts: An uncommon cause of thoracic cord compression. Asian J Neurosurg 2017;12:321-3.

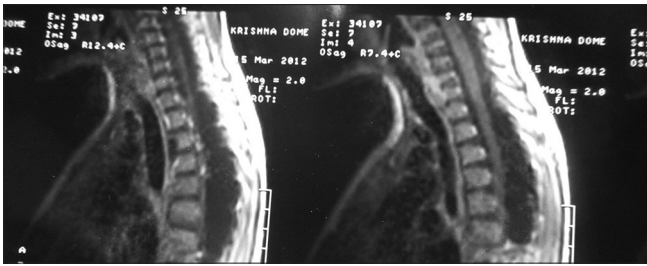

Figure 1: Magnetic resonance T1 weighted sagittal image of thoracic spine showing hypointense lesion extending from D1 to D7

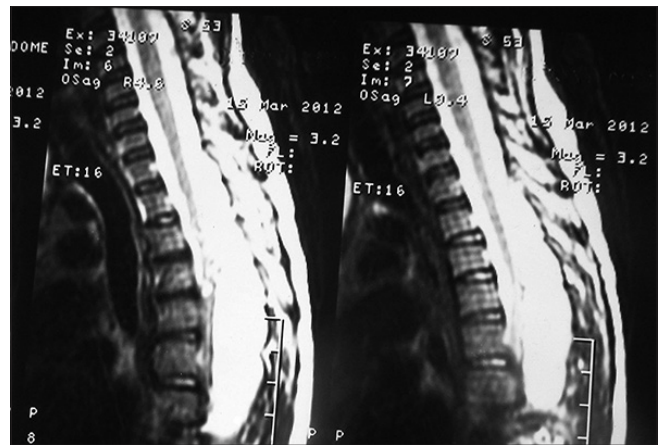

Figure 2: Magnetic resonance T2 weighted sagittal image of thoracic spine showing hyperintense lesion extending from D1 to D7

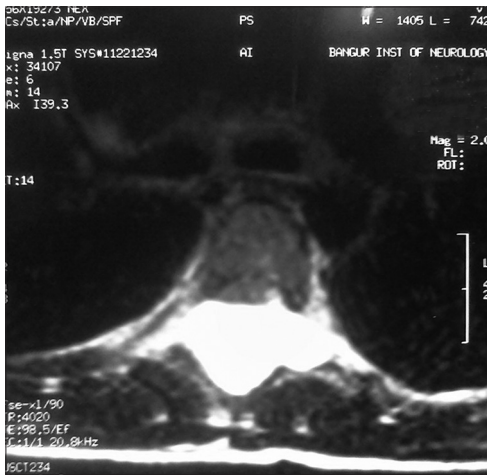

Figure 3: Magnetic resonance T2 weighted image showing foraminal extensions of the cysts

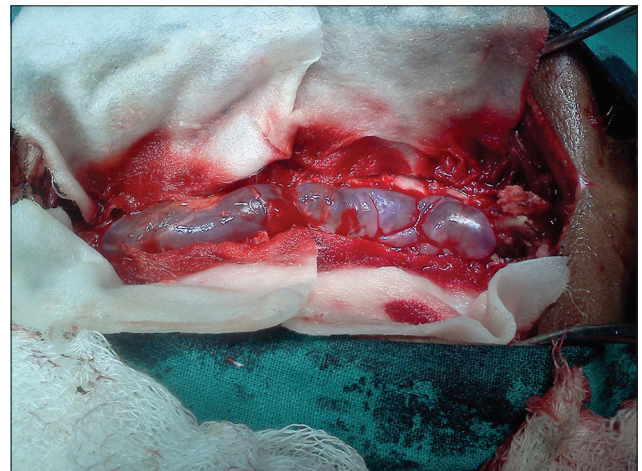


Figure 4: Intraoperative findings shows multiple extradural arachnoid cysts

relatively rare disease entity.^[1] They are also described as “meningeal cyst” or “arachnoid pouches”. Characteristically, they are formed by a thin fibrotic membranous capsule, macroscopically similar to the arachnoid membrane filled by CSF.^[2]

They almost always communicate with the intrathecal sub-arachnoid space through a small defect in the dura.^[3] These cysts occur predominantly in the middle and lower thoracic spine (65%) but have also been reported in the lumbar and lumbosacral (13%), thoracolumbar (12%), sacral (7%), and cervical regions (3%). They are commonly located posterior to the cord at the thecal sac - nerve root sleeve junction, the dorsal midline, or the nerve root sleeve itself (85%). A few have been reported to extend into or through the neural foramen.^[4]

According to the classification described by Nabors *et al.*^[5] for spinal meningeal cysts, extramedullary cysts of the spinal canal can be divided into three main types.

- Type 1: Extradural meningeal cysts that contain nonneural tissue subdivided into extradural cysts (Type 1A) and sacral meningoceles (Type 1B)
- Type 2: Extradural meningeal cysts that contain neural tissue and
- Type 3: Intradural meningeal cysts.

Our case belonged to the Type 1A. The origin of spinal extradural cysts is uncertain. A congenital origin has been proposed for these cysts, involving either congenital diverticula of the dura or herniation of arachnoid through a congenital dural defect.^[3,6]

Enlargement of cyst dimensions is proposed to be responsible for spinal cord compression. Authors have described the continuous extension of arachnoid cysts by three mechanisms: (a) Active CSF secretion from the residual arachnoid matter, that is noncommunicating arachnoid cyst, (b) valve effect, also termed communicating arachnoid cyst with passive fluid transport mechanism, and (c) free water entrance caused by hyperosmolar cyst content.^[7]

The most common presenting symptoms and signs are pain and progressive spastic or flaccid paraparesis, which are often asymmetric and generally related to compression of the spinal cord or nerve roots. Symptoms typically fluctuate, with remissions and exacerbations. Valsalva maneuvers, which

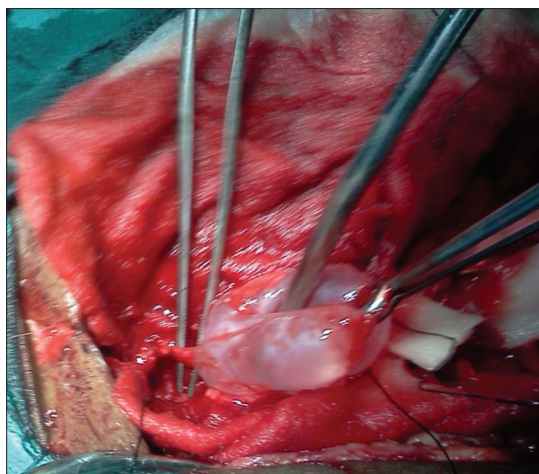


Figure 5: Intraoperative picture showing the presence of intradural connection of an arachnoidal cyst through a pedicle

occur during daily activities, might increase the volume of the cyst.^[8] The differential diagnosis includes tumor, ependymal cysts, epidermoid or dermoid cyst, enterogenous cysts, and teratogenic cysts.

Surgery remains the mainstay of treatment of spinal extradural arachnoid cyst which are progressive. Neurological dysfunction appears in the course of spinal cord compression. There is general agreement that the successful treatment of a spinal arachnoid cyst requires complete excision from the posterior aspect of the thecal sac, followed by obliteration of the communicating pedicle and water tight repair of the dural defect to eradicate the ball valve mechanism, as we performed in our cases.

These cysts can usually be dissected and elevated off of the dura with ease; however, in cases in which the cyst cannot be resected completely because of dense fibrous adhesion preventing safe separation of the cyst from the dura (especially posttraumatic, or postinflammatory cysts), a wide marsupialization of the cyst can be performed by resecting the dorsal wall of the cyst and closing the dural defect.^[9]

Nakagawa *et al.*, reported a case report of an intradural/extradural arachnoid cyst treated by percutaneous aspiration of the cyst contents under MRI guidance, which proved to be successful after 1-year of follow-up.^[10] The other therapeutic options are cystoperitoneal shunting when the dural defect is large and not amenable to watertight repair, less invasive

percutaneous computed tomography or MRI guided aspiration and minimally invasive endoscopic treatment.^[3]

Conclusion

Multiple spinal arachnoid cysts at single spinal segment are rare benign lesions that produce neurological symptoms due to compression over the spinal cord. MRI is useful in detecting the mass and the signal characteristics are consistent with those of CSF. Surgical treatment of spinal arachnoid cysts not only provides neural decompression but also prevent cyst recurrence. Although quite rare, the diagnosis of arachnoid cyst should be considered in the differential diagnosis of intraspinal extradural cystic lesions, causing spinal cord compression. Surgery is the treatment of choice with good clinical outcome.

Financial support and sponsorship

Nil.

Conflicts of interest

There are no conflicts of interest.

References

1. Marbacher S, Barth A, Arnold M, Seiler RW. Multiple spinal extradural meningeal cysts presenting as acute paraplegia. Case report and review of the literature. *J Neurosurg Spine* 2007;6:465-72.
2. McCrum C, Williams B. Spinal extradural arachnoid pouches. Report of two cases. *J Neurosurg* 1982;57:849-52.
3. Liu JK, Cole CD, Kan P, Schmidt MH. Spinal extradural arachnoid cysts: Clinical, radiological, and surgical features. *Neurosurg Focus* 2007;22:E6.
4. Boisserie-Lacroix M, Bouin H, Joulie M, Laurent F, Biset JM, Drouillard J, *et al.* The value of MRI in the study of spinal extradural arachnoid cysts. *Comput Med Imaging Graph* 1990;14:221-3.
5. Nabors MW, Pait TG, Byrd EB, Karim NO, Davis DO, Kobrine AI, *et al.* Updated assessment and current classification of spinal meningeal cysts. *J Neurosurg* 1988;68:366-77.
6. Aithala GR, Sztriha L, Amirlak I, Devadas K, Ohlsson I. Spinal arachnoid cyst with weakness in the limbs and abdominal pain. *Pediatr Neurol* 1999;20:155-6.
7. Kahraman S, Anik I, Gocmen S, Sirin S. Extradural giant multiloculated arachnoid cyst causing spinal cord compression in a child. *J Spinal Cord Med* 2008;31:306-8.
8. Okacha N, Quamous O, Ali A, Mostarchid BE, Mohamed B. Spinal extradural arachnoid cyst: An uncommon cause of thoracic spine compression. *Pan Arab J Neurosurg* 2011;15:50-4.
9. Uemura K, Yoshizawa T, Matsumura A, Asakawa H, Nakamagoe K, Nose T. Spinal extradural meningeal cyst. Case report. *J Neurosurg* 1996;85:354-6.
10. Nakagawa A, Kusaka Y, Jokura H, Shirane R, Tominaga T. Usefulness of constructive interference in steady state (CISS) imaging for the diagnosis and treatment of a large extradural spinal arachnoid cyst. *Minim Invasive Neurosurg* 2004;47:369-72.