

CASE REPORT

Moyamoya disease presenting as bilateral acute subdural hematomas without deficits

Mudumba Vijayasaradhi, Vangala B. Prasad

Department of Neurosurgery, Nizam's Institute of Medical Sciences, Hyderabad, Telangana, India

ABSTRACT

We report a patient presenting with imageological features of bilateral acute subdural hematomas and subarachnoid hemorrhage, who was subsequently diagnosed as a case of moyamoya disease. Imageological features, source of hemorrhage, literature review, and management are discussed. We report this case in view of its rarity in presentation with these imageological features.

Key words: Bilateral acute subdural hemorrhage, moyamoya disease, subarachnoid hemorrhage

Introduction

Moyamoya disease is a rare condition, characterized by stenosis of supraclinoid internal carotid artery (ICA), with development of collaterals at the base of the brain supplying the anterior circulation. Angiographically, it gives rise to the characteristic appearance of “puff of smoke” due to collaterals, hence the name.^[1] Usually 66% of adult moyamoya patients present with hemorrhagic manifestations, and in contrast, children usually present with ischemic manifestations.^[2] Usually hemorrhagic moyamoya patients present with intracerebral hemorrhage or subarachnoid hemorrhage due to rupture of moyamoya vessel or collaterals arising from moyamoya vessels.^[3] Associated anomalies like aneurysms, arteriovenous malformations, and ectatic vessels can give rise to bleeding in these patients presenting with hemorrhages. Common sites of bleeding are usually in the territories of these vessels, viz. intracerebral, subarachnoid, or intraventricular locations. Presentation with spontaneous bilateral diffuse subdural hemorrhage and subarachnoid hemorrhage in the same patient is not yet reported in moyamoya patients in the literature. Though a case of subdural hematoma was described earlier in an African-American, it was in the setting of congestive heart

failure and it was unilateral without associated subarachnoid hemorrhage.^[3] Similar case report of nontraumatic subdural hemorrhage is available in the literature search. But in that case, the bleeding was in the subdural space only, and unilateral, without subarachnoid component.^[4]

Case Report

A 35-year-old male patient, not a known diabetic or hypertensive, presented with history of sudden onset of headache of 1 day duration following an act of sneezing. Headache was sudden, severe, and excruciating, and was associated with vomiting. It was followed by a brief episode of unconsciousness for which he was hospitalized. There was no history of bleeding disorders or usage of anticoagulants in the past. There was history of stroke involving right upper limb which resolved by 2 days spontaneously 1 year back. Initial examination at admission showed that his vital parameters were normal. Neurological examination revealed neck rigidity and positive Kernig's sign. The initial Glasgow Coma Scale was 15/15. There were no focal neurological signs. Routine blood and biochemical investigations including prothrombin time and activated plasma thromboplastin time were within normal range. A computed tomography revealed bilateral acute frontoparietal subdural hematomas, which were extending into interhemispheric regions, and bilateral diffuse subarachnoid hemorrhage [Figure 1]. There was no

Access this article online	
Quick Response Code:	Website: www.asianjns.org
	DOI: 10.4103/1793-5482.149997

Address for correspondence:

Dr. Mudumba Vijayasaradhi, Department of Neurosurgery, Nizam's Institute of Medical Sciences, Hyderabad, Telangana, India. E-mail: vijaya2saradhi@yahoo.com

This is an open access article distributed under the terms of the Creative Commons Attribution-NonCommercial-ShareAlike 3.0 License, which allows others to remix, tweak, and build upon the work non-commercially, as long as the author is credited and the new creations are licensed under the identical terms.

For reprints contact: reprints@medknow.com

How to cite this article: Vijayasaradhi M, Prasad VB. Moyamoya disease presenting as bilateral acute subdural hematomas without deficits. Asian J Neurosurg 2017;12:228-31.

mass effect or midline shift. There was an old infarct in left caudate nucleus correlating with the previous history of stroke 1 year back [Figure 2].

With a suspicion of aneurysmal bleed based on history, a four-vessel cerebral angiogram was performed which showed characteristic features of moyamoya disease [Figures 3-6]. There

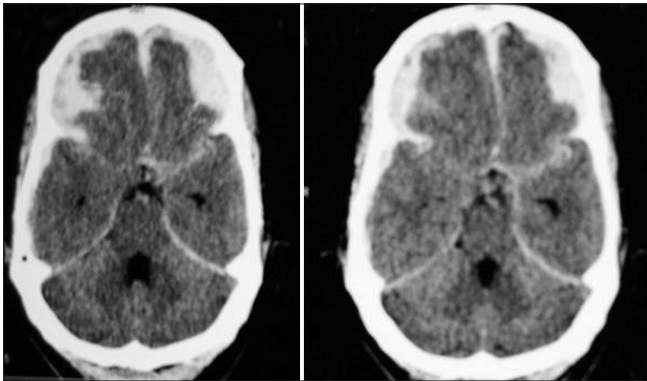


Figure 1: Axial computed tomography done on the day of ictus showing bilateral subdural hematoma with interhemispheric extension and diffuse subarachnoid hemorrhage

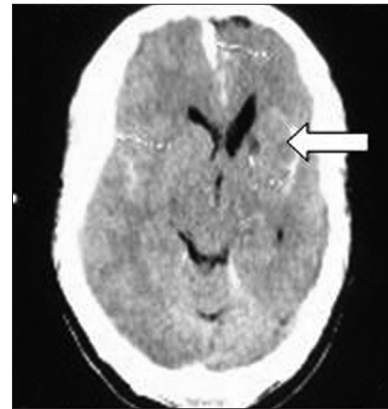


Figure 2: Axial computed tomography showing small infarct in left caudate region suggestive of old infarct

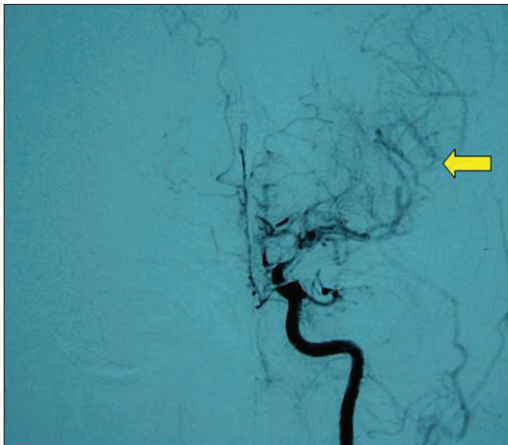


Figure 3: Left internal carotid artery injection during four-vessel angiography anterior-posterior view showing supraclinoid ICA stenosis with abundant lenticulostriate collaterals (arrow)

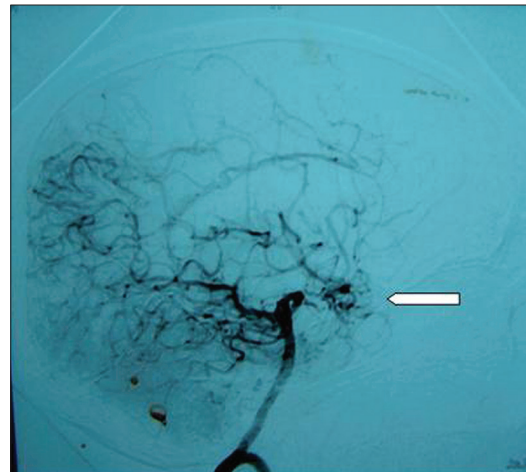


Figure 4: Left vertebral injection lateral view showing anterior circulation vessels getting supply from posterior communicating artery

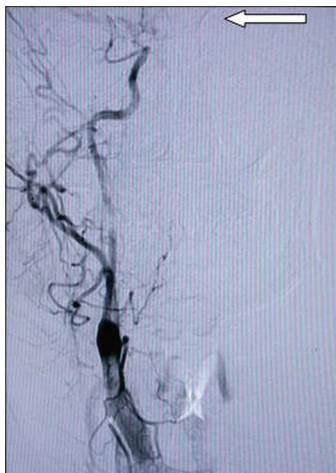


Figure 5: Right external carotid injection lateral view showing high parietal parasagittal vault moyamoya anastomotic vessel (arrow)

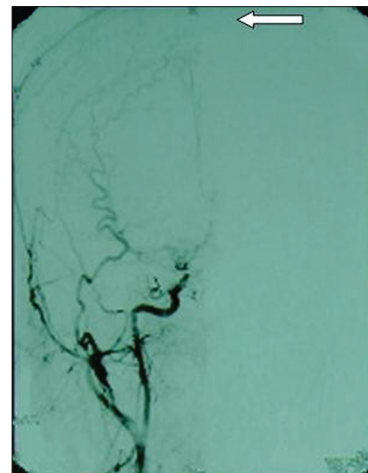


Figure 6: Right external carotid injection AP view showing high parietal parasagittal vault moyamoya anastomotic vessel (arrow)

were angiographic features of supraclinoid internal carotid stenosis [Figure 3], with lenticulostriate collaterals [Figure 4]. External carotid artery giving rise to vault moyamoya vessel at high parietal region was seen [Figures 5 and 6]. There were no other vascular anomalies noted, such as aneurysms or arteriovenous malformations. Patient was investigated for secondary causes of ICA stenosis, which include protein C, protein S, antithrombin III, serum homocysteine levels, and collagen vascular profile, which were all normal. He was managed conservatively.

Discussion

Hemorrhagic presentation in moyamoya disease is usually manifested in adult patients, contrary to children where ischemic presentation predominates.^[5] The usual pathogenesis of bleed is rupture of a high-flow moyamoya vessel in these patients. Usual imageological manifestations of moyamoya disease are subarachnoid, intracerebral bleed, and intraventricular hemorrhage. A large variety of arterial anomalies, including aneurysms, arteriovenous malformations, fenestrations, primitive arteries, ectasia, or a combination of these, have been described in these patients.^[2] There appears to be a significantly higher frequency of arterial anomalies in patients with moyamoya than in the general population. In 1000 cases of moyamoya, Morioka *et al.*^[6] found 56 aneurysms (5.6%), contrary to the rate of aneurysms in the normal population, which is $0.15 \pm 1\%$.^[6] The main routes of collateral circulation in moyamoya disease are basal moyamoya vessels, leptomeningeal anastomosis between them and anterior circulation, and transdural anastomoses between the extracranial and intracranial vessels. Leptomeningeal collaterals develop in abundance, when prominent basal moyamoya vessels are present. In the advanced stage, the degree of leptomeningeal collaterals from the posterior cerebral artery diminish and there occurs transdural anastomoses, represented by ethmoid moyamoya and vault moyamoya vessels.^[5]

In moyamoya patients without aneurysms, moyamoya vessels have been suggested as the main source of bleeding. Rebleeding is the most important reason for the poor outcome of patients with hemorrhagic moyamoya disease. In our case, in view of large quantity of blood, it is probable that the site of bleeding is a large moyamoya vessel or an occult aneurysm. Bilateral bleeding in subdural space may be due to origin of bleeding near or at superior sagittal sinus from a transdural anastomotic channel or from the sinus itself which has bled on both sides of the hemisphere. Another source could be from extracranial anastomotic leptomeningeal collateral. With this supposition, it is difficult to explain subarachnoid hemorrhage component in this case. Currently there are no absolute predictors to prognosticate episodes of hemorrhage in these patients. In the instances where there are intracerebral hemorrhages, dilated anterior choroidal and posterior

communicating vessels were thought to be the culprits. But bleed from them into the bilateral subdural space, as seen in our case, is a remote possibility. In a morphometric analysis of moyamoya vessels the most dilated vessels showed marked fibrosis and marked attenuation of media with segmentation of elastic lamina resulting in microaneurysm formation and subsequent rupture.^[7] None of the autopsy studies could pin point the exact site of rupture which was responsible for bleeding in those patients. Their series showed consistently dilated anterior choroidal artery and posterior communicating arteries in hemorrhagic patients of moyamoya disease.^[8] Goals of treatment in these patients are to prevent rebleed.

Another probable cause of bleeding in these moyamoya patients is that there could be high cerebral venous pressures and changes in cerebral perfusion caused by loss of cerebrovascular autoregulation, which is known to occur in moyamoya disease.^[5] This was postulated as the cause of subdural hematoma in one of the cases reported earlier.^[7] Same phenomenon may explain the occurrence of bilateral subdural hematoma following an act of sneezing, as seen in our patient. Another probability is the rupture of transdural anastomotic channel from external carotid artery near superior sagittal sinus. Though the source of bleeding still remains puzzling in our case, the fact remains that bilateral subdural hemorrhage along with diffuse subarachnoid hemorrhages in the same patient is not known in moyamoya till date, as per literature search.

The usual treatment modality is STA – MCA (superficial temporal artery to middle cerebral artery) bypass, which reduces blood flow through moyamoya vessels.^[1] The same was planned for this patient at a later date.

Conclusion

This article adds to the body of literature of moyamoya disease, where the source of bleeding remains elusive. In view of bilaterality of bleed, we hypothesize that transdural anastomotic channel is implicated as a probable source of bleeding in this case. This ambiguity remains with any rare condition.

Financial support and sponsorship

Nil.

Conflicts of interest

There are no conflicts of interest.

References

1. Takeuchi S, Tanaka R, Ishii R, Suchia T, Kobayashi K, Arai H. Cerebral hemodynamics in patients with Moyamoya disease. *Surg Neurol* 1985;23:468-74.
2. Yabumoto M, Funahashi K, Fujii T, Hayashi S, Komai N. Moyamoya disease associated with intracranial aneurysms. *Surg Neurol* 1983;20:20-241.
3. Oppenheim JS, Gennuso R, Sacher M, Hollis P. Acute atraumatic subdural hematoma associated with moyamoya disease in an

- African-American. *Neurosurgery* 1991;28:616-8.
4. Nakakita K, Tanaka S, Fukuda A, Fujii C, Kohama A, Miyasato H. Nontraumatic acute subdural hematoma caused by the rupture of transdural anastomotic vessels in moyamoya disease. *No Shinkei Geka* 1994;22:561-5.
 5. Piao R, Oku N, Kitagawa K, Imaizumi M, Matsushita K, Yoshikawa T, *et al.* Cerebral hemodynamics and metabolism in adult moyamoya disease. *Ann Nucl Med* 2004;18:115-21.
 6. Morioka M, Hamada JI, Kawano T, Todaka T, Yano S, Kai Y, *et al.* Angiographic dilatation and branch extension of the anterior choroidal and posterior communicating arteries are predictors of hemorrhage in adult moyamoya patients. *Stroke* 2003;34:90-5.
 7. Satoshi T, Akiko A, Kouichi H, Kenich M, Yasuyuki M. Acute subdural hematoma in patient with Moyamoya disease after bilaterally EDAS and right frontal single burr-hole operation: A Case Report. *Neurotraumatology* 2005;28:40-3.
 8. McCormick WF, Nofzinger JD. Saccular intracranial aneurysms. An autopsy study. *J Neurosurg* 1965;25:155-9.