

CASE REPORT

Gossypiboma complicated with paraspinal abscess and lumbar sinus: An uncommon complication of posterior lumbar spinal surgery

Ranjan Kumar Sahoo, Pradipta Tripathy¹, Pulin Bihari Das², Debahuti Mohapatra³

Department of Radiology, ¹Neurosurgery, ²Orthopedic, and ³Pathology, Institute of Medical Science and SUM Hospital, Kalinga Nagar, Ghatikia, Bhubaneswar, Odisha, India

ABSTRACT

A 42-year-old female presented with the complaint of purulent discharging sinus over posterior lumbar area following one month of lumbar spinal surgery for prolapsed intervertebral disc. Gossypiboma complicated with paraspinal abscess and sinus track formation over posterior lumbar area was diagnosed in magnetic resonance imaging which was confirmed in re-exploration of lumbar spinal operative site.

Key words: Gossypiboma, paraspinal abscess, posterior lumbar spinal surgery

Introduction

Gossypiboma is a non-medical term derived from Latin word “Gossypium” (cotton) and “boma” (place of concealment) and defined as a mass inside body consisting of cotton matrix with surrounding foreign body reaction.^[1] It occurs very rarely in posterior spinal surgery for lumbar disc in comparison to abdominal and thoracic surgery. Clinical manifestation of gossypiboma may occur incidentally in early post-operative period or it may remain silent for years. Gossypiboma often mimics mass or abscess both clinically and radiologically.^[2,3] Incidence of gossypiboma is difficult to estimate because of low reporting due to medicolegal implication.^[4] Here, we describe a case of gossypiboma presenting as paraspinal abscess with sinus track in posterior lumbar area 1 month following posterior lumbar disc surgery.

Case Report

The present case report is about a 42-year-old woman presented to neurosurgical outpatient department with the

complaint of purulent discharge from posterior lower lumbar area with severe backache for last 7 days. She was operated for L4/L5 posterior central extruded disc manifesting as acute sciatica 1 month back. At that time, L4 laminectomy and microscopic discectomy had been done. Her post-operative period was uneventful. She got symptomatic relief after surgery and was discharged on eighth post-operative day after suture removal. On subsequent follow-up, she complained of intermittent severe pain at the operation site and fever with rigor for which she was given antipyretics and analgesics. After 3 weeks of surgery, she noticed pus discharge from the wound site and had severe backache.

Pus was sent for culture and sensitivity and wound dressing was done. Culture did not show any growth of the organism. However, broad spectrum injectable antibiotic in combination (vancomycin piperacillin and tazobactam) was given for 7 days. There was no response and sinus discharge persisted. Hence a magnetic resonance imaging (MRI) of the lumbosacral spine was carried out. MRI showed T1W hypointense, T2W/short tau inversion recovery hyperintense collection at paraspinal location extending from L2 to L5

Access this article online	
Quick Response Code:	Website: www.asianjns.org
	DOI: 10.4103/1793-5482.148804

Address for correspondence:

Dr. Pradipta Tripathy, Department of Neurosurgery, IMS and SUM Hospital, Sector-8, Kalinga Nagar, Ghatikia, Bhubaneswar - 751 003, Odisha, India.
E-mail: pradipta_tripathy@yahoo.com

This is an open access article distributed under the terms of the Creative Commons Attribution-NonCommercial-ShareAlike 3.0 License, which allows others to remix, tweak, and build upon the work non-commercially, as long as the author is credited and the new creations are licensed under the identical terms.

For reprints contact: reprints@medknow.com

How to cite this article: Sahoo RK, Tripathy P, Das PB, Mohapatra D. Gossypiboma complicated with paraspinal abscess and lumbar sinus: An uncommon complication of posterior lumbar spinal surgery. Asian J Neurosurg 2017;12:211-3.

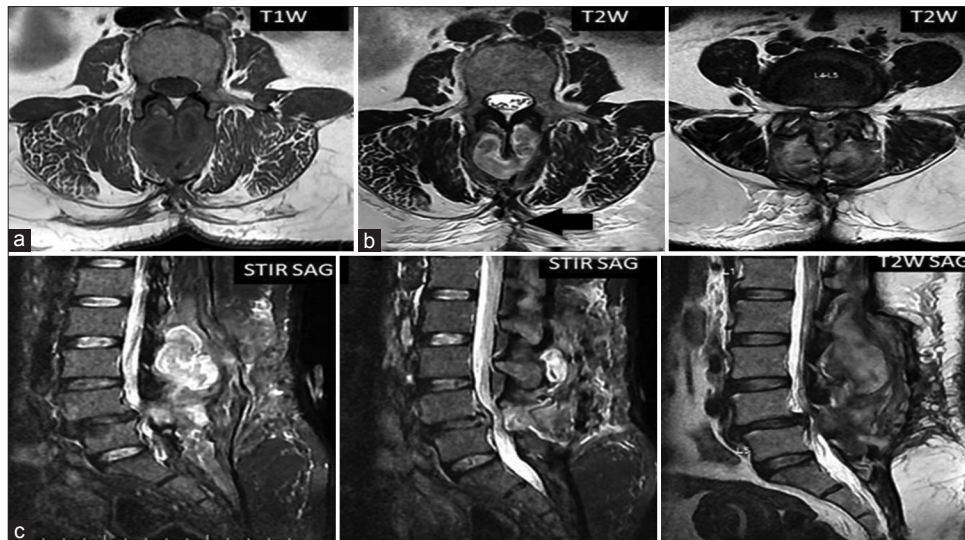


Figure 1: The axial magnetic resonance imaging (MRI) images shows T1W isointense (a) and T2W hypointense (b) signal of retained gauze piece inside posterior paraspinal abscess of lumbar spine. The sagittal T2W/short tau inversion recovery (c) MRI images shows hyperintense signal of paraspinal abscess (from L2 to L5 level) surrounding the gauze piece and the ill-defined posterior lumbar sinus tract (black arrow)

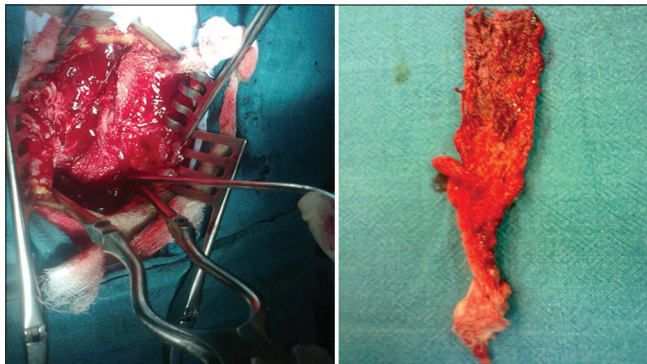


Figure 2: Intraoperative picture shows retained surgical gauze piece in the posterior lumbar paraspinal location which is extracted and shown on the table

vertebral location in horseshoe manner leading to an ill-defined sinus track at L5 vertebral level. The collection showed T1W and T2W hypointense thick elongated foreign body inside, which was suspected to be a retained gauze piece [Figure 1]. On re-exploration of the operative site, the gauze piece was retrieved [Figure 2]. The paraspinal abscess was evacuated and excision of sinus track was done. The patient improved and became asymptomatic on follow-up.

Discussion

Gossypiboma and textiloma are often used synonymously. The textiloma in the true sense denotes the retained surgical gauze piece consisting of organic material and the gossypiboma is a mass within body consisting of cotton matrix with surrounding foreign body reaction.^[5] Gossypiboma or textiloma may manifest acutely in the early post-operative period due to exudative reaction, abscess and skin fistula formation. It may present later

months or years after surgery in the form of foreign body granuloma or mass formation.^[6] Our case reported in early post-operative period with discharging sinus, paraspinal abscess surrounding retained surgical gauze piece in posterior lumbar area.

The non-absorbable gossypiboma containing radio-opaque marker are easily identified in radiograph or computed tomography (CT) scan in post-operative periods. However retained surgical gauze piece with no radio opaque marker are difficult to detect in imaging. On ultrasound imaging, gossypiboma appears as a hyper reflective lesion with hypoechoic rim casting posterior acoustic shadow. On CT scan image, a spongiform pattern with gas bubbles or a heterogeneous low attenuation mass with a thin high-attenuation capsule are common characteristic features of retained surgical sponges.^[7] On MRI scan, paravertebral gossypiboma appears as hypointense on T1W image and hyperintense on T2W image with low signal intensity stripe suggestive of gauze fiber.^[2,8] Surgical sponge with high sero-sanguinous and protein rich fluid will shows high signal in the center of mass in T1WI and T2W image while organized cotton/gauze fibers with little fluid will show low signal intensity in the center of mass.^[9] In our case, the retained gauge piece shows low signal intensity stripe on T2W image inside paraspinal abscess with ill-defined posterior lumbar sinus track.

There are many factors such as emergency surgery, unexpected change in the surgical procedure dis-organization, hurried sponge counts, long operations, unstable patient condition, inexperienced staff, inadequate staff numbers and patient with high body mass index that may leads to retained gauze piece in the body during operation.^[4]

Conclusion

Gossypiboma usually has no specific clinical signs or imaging appearance. Patient-clinician and clinician-radiologist interactions and compliance required for accurate diagnosis. Gossypiboma should be included in the differential diagnosis of paraspinal masses in case of history of operation. Meticulous inspection of the operative site, body cavity, careful counting and record maintenance of gauze pieces before wound closure are required to prevent the incidence of gossypiboma and its complication.

Financial support and sponsorship

Nil.

Conflicts of interest

There are no conflicts of interest.

References

1. Rajput A, Loud PA, Gibbs JF, Kraybill WG. Diagnostic challenges in patients with tumors: Case 1. Gossypiboma (foreign body) manifesting 30 years after laparotomy. *J Clin Oncol* 2003;21:3700-1.
2. Turgut M, Akyüz O, Ozsunar Y, Kacar F. Sponge-induced granuloma (“gauzoma”) as a complication of posterior lumbar surgery. *Neurol Med Chir (Tokyo)* 2005;45:209-11.
3. Stoll A. Retained surgical sponge 40 years after laminectomy. Case report. *Surg Neurol* 1988;30:235-6.
4. Tarik U, Gokhan DM, Sunay YM, Mahmut A. The medico-legal importance of gossypiboma. 4th Mediterranean Academy of Forensic Science Meeting, 14-18 October 2008, Antalya-Turkey. Abstract CD of Poster Presentations; 2009. p. 82-3.
5. Kim HS, Chung TS, Suh SH, Kim SY. MR imaging findings of paravertebral gossypiboma. *AJNR Am J Neuroradiol* 2007;28:709-13.
6. Olnick HM, Weens HS, Rogers JV Jr. Radiological diagnosis of retained surgical sponges. *J Am Med Assoc* 1955;159:1525-7.
7. Yamato M, Ido K, Izutsu M, Narimatsu Y, Hiramatsu K. CT and ultrasound findings of surgically retained sponges and towels. *J Comput Assist Tomogr* 1987;11:1003-6.
8. Kominami M, Fujikawa A, Tamura T, Naoi Y, Horikawa O. Retained surgical sponge in the thigh: Report of the third known case in the limb. *Radiat Med* 2003;21:220-2.
9. Kuwashima S, Yamato M, Fujioka M, Ishibashi M, Kogure H, Tajima Y. MR findings of surgically retained sponges and towels: Report of two cases. *Radiat Med* 1993;11:98-101.