

# Neuroendoscopy - Is it safe?

Manas Panigrahi, Bharat Gupta, Rajesh Reddy

Department of Neurosurgery, Krishna Institute of Medical Sciences, Secunderabad, Telangana, India

## ABSTRACT

**Background:** The effect of heat in endoscopic instruments used for laparoscopy and hysteroscopy has been well-studied. Reports of thermal injury from nasal endoscopes have also been reported. However, there are no experimental studies, which have objectively documented and provided recommendations for safe use of endoscopes in neurosurgery.

**Objectives:** To study the heat generated at the tip of the endoscope and the subsequent thermal damage caused to a cotton drape placed in proximity, by varying the intensity of light delivered through different optical cables, ambient (operating room) temperatures and working distances.

**Materials and Methods:** The study was carried out in the operation theater using a 300 watt xenon light source connected to the endoscope with 3.5 mm and 4.8 mm optical cables. A digital thermometer was used to record the heat generated at the tip of the endoscope.

**Results:** The heat generated at the tip of the endoscope reached its peak in the first 6 min and attained a plateau at 15 min after turning on a light source of 60% intensity. Thermal injury to the cotton drape took a longer time with a 3.8 mm cable compared with 4.8 mm cable. The heat generated at the tip of the endoscope, and thereby the thermal injury caused was found to be lower when the ambient temperature was close to 20°C.

**Conclusions:** Complications related to thermal injuries caused by heat generated at the tip of an endoscope can be reduced by using a smaller diameter cable, light intensity of 60%, increasing the working distance (as permissible), reducing the time spent for dissection while keeping the endoscope very close to the target and lowering the ambient temperature to 20°C.

**Key words:** Neuroendoscope, parameters, thermal injury

## Introduction

The endoscope is an important tool in the armamentarium of neurosurgeons for minimally invasive surgical approaches, which are becoming increasingly popular for a variety of neurosurgical procedures. It has been widely accepted for third ventriculostomy, excision of intraventricular tumors, trans-sphenoidal removal of sellar-parasellar, as well as other skull base tumors and lumbar disc surgeries. Endoscope assisted aneurysm clipping and microvascular decompression for neurovascular conflicts are also established procedures.

Neuroendoscope has the advantage of better visualization over an operating microscope because of the illumination, magnification and the panoramic view provided by the former. Studies are comparing endoscopic and microsurgical approaches for sellar-parasellar and other skull base procedures have shown favorable results for endoscopic surgery in providing early recovery, better resection and fewer complication rates.<sup>[1,2]</sup>

One of the major concerns with endoscopic surgery is the higher incidence of postoperative cerebrospinal fluid (CSF) leak, new onset neurological deficit, endocrine imbalances and a longer learning curve. The reasons for higher complications may be due to the pathology itself or the technique of dissection. It is well known that heat generated at the tip of the endoscope due to optical light can cause thermal injury to tissues in its proximity.

This is an open access article distributed under the terms of the Creative Commons Attribution-NonCommercial-ShareAlike 3.0 License, which allows others to remix, tweak, and build upon the work non-commercially, as long as the author is credited and the new creations are licensed under the identical terms.

**For reprints contact:** reprints@medknow.com

Access this article online	
<b>Quick Response Code:</b> 	<b>Website:</b> <a href="http://www.asianjns.org">www.asianjns.org</a>
	<b>DOI:</b> 10.4103/1793-5482.145567

### Address for correspondence:

Dr. Rajesh Reddy, Department of Neurosurgery, Krishna Institute of Medical Sciences, Minister Road, Secunderabad - 500 003, Telangana, India. E-mail: rajesh\_jipmer@rediffmail.com

**How to cite this article:** Panigrahi M, Gupta B, Reddy R. Neuroendoscopy - Is it safe?. Asian J Neurosurg 2017;12:17-21.

This study was undertaken based on our observation of thermal injury caused by an endoscope to a sterile cotton drape placed over the patient during a surgical procedure. As human tissue is more sensitive to thermal damage than a cotton drape, we were interested in studying the parameters that could reduce the incidence of thermal damage.

### Objectives

To study the heat generated at the tip of the endoscope, and the subsequent thermal damage caused to a cotton drape placed in proximity, by varying the intensity of light delivered through different optical cables, ambient (operating room) temperatures and working distances.

### Materials and Methods

The study was carried on in the operation theatre at Krishna Institute of Medical Sciences, Secunderabad, India. A 0° Karl Storz endoscope with 4.8 mm and 3.5 mm diameter optical cables of 3 m and 2.5 m lengths respectively were used. A digital thermometer, measuring scale, stop watch and cotton sheets used for draping the patient were also a part of the experimental set up [Figure 1]. A plastic sheet wrapped over card board was kept under the cotton sheet draped on the operating table to minimize transfer of thermal energy by conduction.

The endoscope was fixed at edge of operating table with the help of endoscope stand. The ambient (operating room) temperature was adjusted using a thermostat. The optical cable was connected to the endoscope set at a designed working distance from the target (cotton drape). The intensity of light was adjusted, and temperature was recorded at the tip of the endoscope at 1-min interval for 15 min. The time taken for the thermal injury (burn) to the cotton drape was noted [Figure 2].

The procedure was repeated for different intensities of light (60%, 80% and 100%), ambient temperatures (20°C, 24°C and 28°C) at working distances of 0, 1 and 2 cm using 3.5 and

4.8 mm cables. All recordings were noted down under the supervision of investigating neurosurgeon. The optical source was switched off for 15 min before repeating the study using a new set of parameters.

### Results

#### Effect of light intensity on heat generated at the tip of endoscope


It was observed with optical cables of 3.5 and 4.8 mm diameters that thermal energy generated at the tip of the endoscope increased as light intensity was raised keeping the working distance and ambient temperature constant [Figure 3a and b]. For instance, the temperature of 39.2°C, 42.7°C and 53.9°C was recorded for light intensities of 60%, 80% and 100% respectively using a 4.8 mm optical cable connected to an endoscope in an ambient temperature of 28°C, kept on the cotton drape (working distance = 0 cm) for 15 min. Maximum heat was generated within 6 min after turning on the optical source with the use of either of the two optical cables.

#### Effect of diameter of the optical cable on heat generated at the tip of endoscope

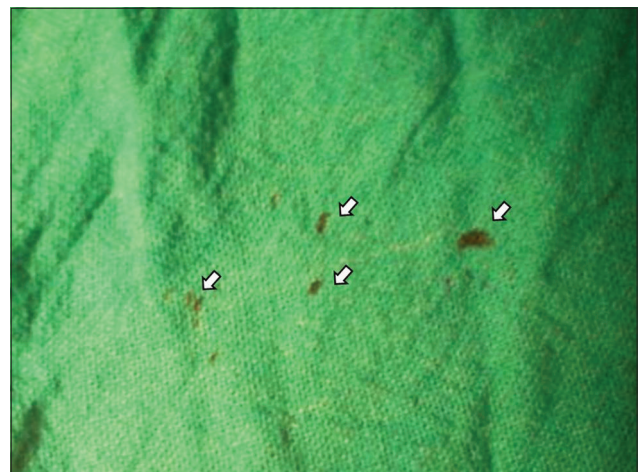A temperature of 42.1°C, 46.1°C, 47.3°C with the 3.5 mm cable and 45.2°C, 52.8°C, 53.9°C with the 4.8 mm cable was recorded at 1, 6 and 15 min using light intensity of 100%, ambient temperature of 28°C with the tip of the endoscope kept on the target (cotton drape). Similar observation was made with light intensities of 80% and 60% [Figure 4a-c]. Hence, it was concluded that smaller the diameter of the optical cable, lesser is the thermal energy generated at the tip of the endoscope for a given intensity of light, working distance and ambient temperature.

#### Effect of ambient temperature on heat generated at the tip of endoscope

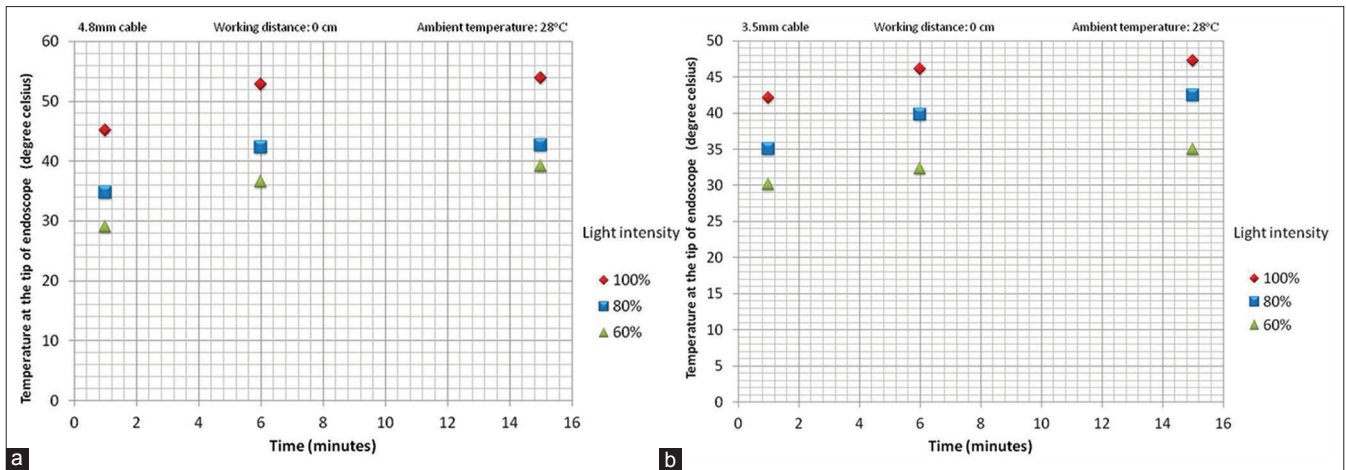
We observed that for a given intensity of light delivered by a cable of a particular diameter to the endoscope kept at a fixed



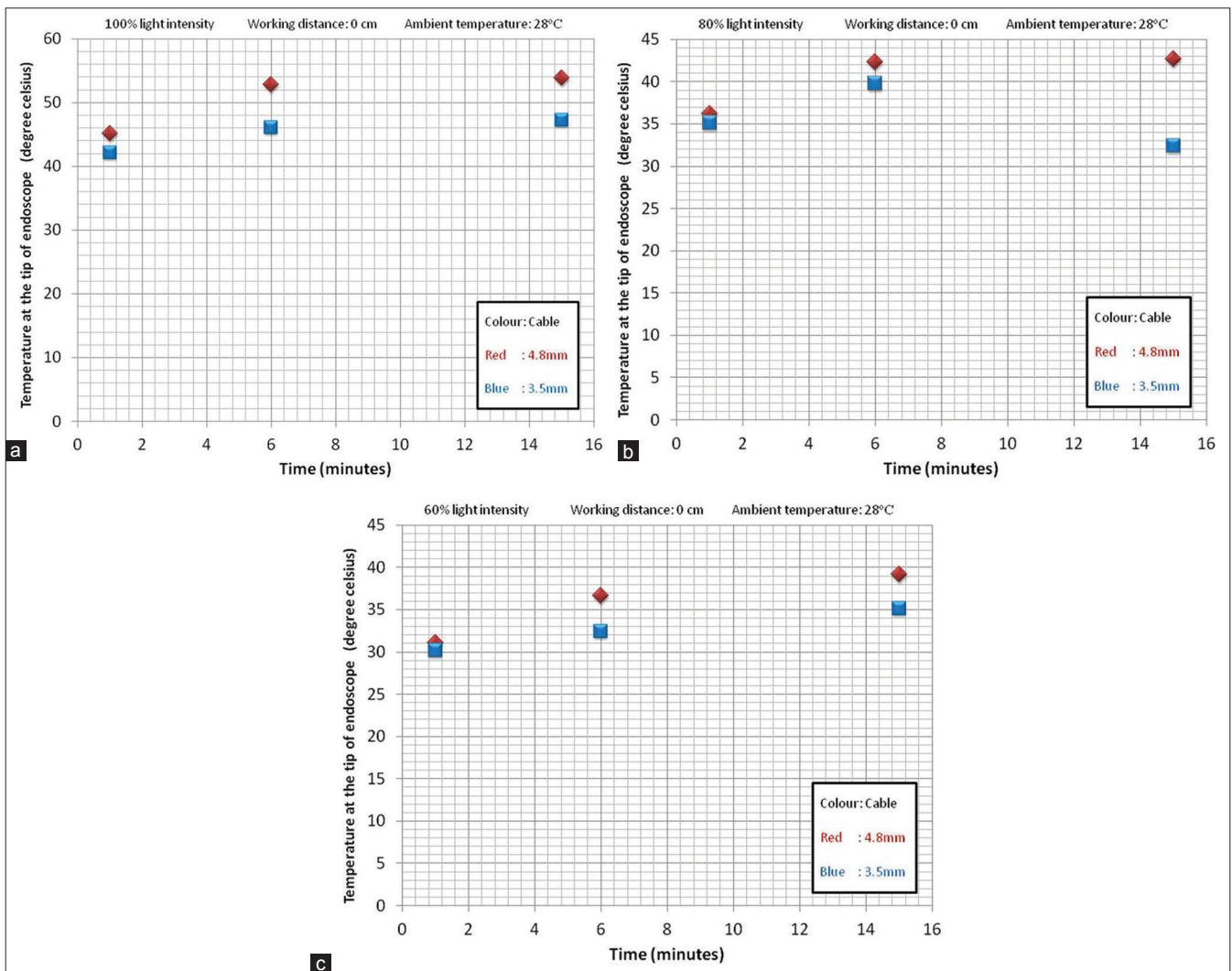
**Figure 1:** Experimental set up with Storz optic source, endoscope, cotton drape, digital thermometer and ruler



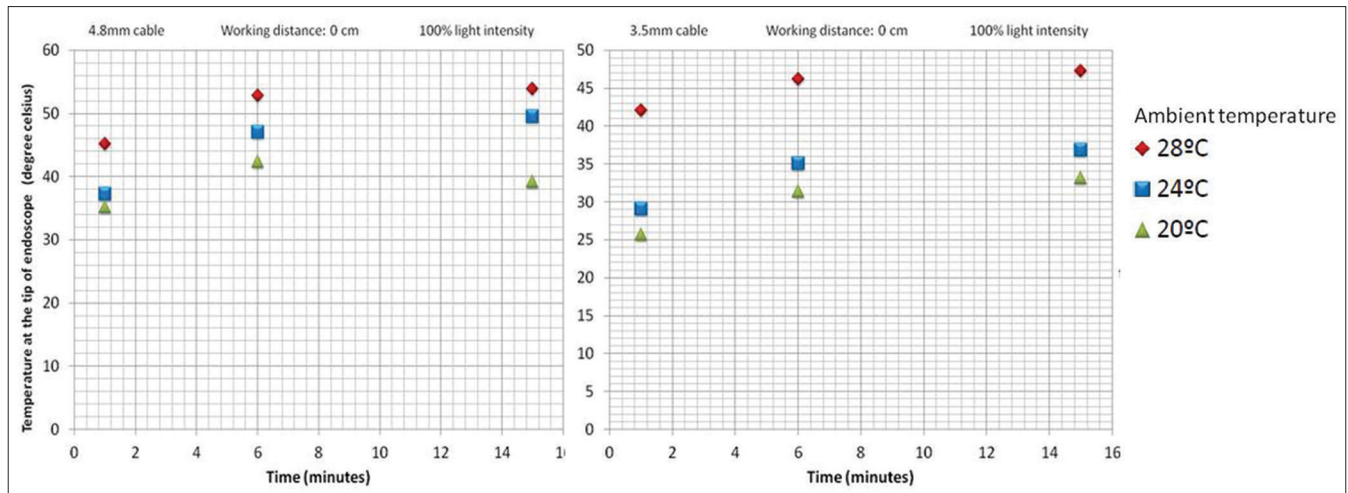
**Figure 2:** Thermal burn marks on the cotton drape (arrows)



**Figure 3:** (a) Effect of light intensity on heat generated at the tip of an endoscope using a 4.8 mm optical cable. (b) Effect of light intensity on heat generated at the tip of an endoscope using a 3.5 mm optical cable



**Figure 4:** (a) Effect of optical cable diameter on heat generated at the tip of the endoscope with 100% light intensity. (b) Effect of optical cable diameter on heat generated at the tip of the endoscope with 80% light intensity. (c) Effect of optical cable diameter on heat generated at the tip of the endoscope with 60% light intensity



**Figure 5:** Effect of ambient temperature on heat generated at the end of endoscope

distance from the target, lowering the ambient (operating room) temperature can reduce the heat generated at the tip of the endoscope and thereby decreased the chances of thermal injury [Figure 5]. For instance, the temperature recorded at the tip of the endoscope connected with light of 100% intensity using a 3.5 mm cable for 15 min was 47.3°C at an ambient temperature of 28°C which reduced to 33.2°C upon lowering the ambient temperature to 20°C, keeping the other parameters constant. Therefore, we recommend an ambient temperature of 20°C for reducing complications related to thermal injuries, while using an endoscope.

### Thermal injury

When the endoscope was kept in contact with the cotton drape, thermal injury (burn) occurred at 1, 7 and 10 min with 100%, 80% and 60% intensities of light delivered to the endoscope through a 4.8 mm cable. Similar observations were noted with the 3.5 mm cable, except that no thermal injury occurred at 15 min when the intensity of light was 60%.

Apart from a low-intensity light, lower ambient temperature was also associated with prolonged duration of time taken to produce thermal injury. This was confirmed when thermal burn was noted at 60, 80, and 100 s on the cotton drape kept in contact with the tip of the endoscope at ambient temperatures of 28°C, 24°C and 20°C respectively with a light intensity of 100% delivered through a 4.8 mm cable.

### Discussion

Some of the complications arising after endoscopic trans-sphenoidal surgeries have been attributed to thermal injury caused to the tissues during surgery. Delayed necrosis of sellar soft tissue and disintegrity of the arachnoid membrane due to the rapid rise of temperature during endoscopic surgery have been proposed as the causes for delayed postoperative CSF leak.<sup>[3]</sup> Delayed facial paresis and hearing loss following endoscope assisted microvascular

decompression of the trigeminal nerve may also be attributed to the heat generated at the tip of the endoscope during the procedure.<sup>[4,5]</sup>

Maric *et al.*<sup>[6]</sup> showed a 17% incidence of newly developed endocrine complications after pure endoscopic excision of pituitary adenoma in 117 patients. Fatemi *et al.*<sup>[2]</sup> found 5% incidence of panhypopituitarism after excision of pituitary macroadenomas with a 13.6% incidence in tumors more than 3cm in size. One of the possible explanations for the proportionate increase in the incidence of hypopituitarism with the size of the tumor is the increased duration of time taken for resection of larger tumors, which exposes the surrounding tissues to the heat generated by the endoscope for a longer duration. During our study, we found that temperatures more than 42°C cause thermal burns on a cotton sheet within a minute.

The effect of focal cortical temperature on cerebral blood flow was studied in rats by Ohmoto *et al.*<sup>[7]</sup>. He concluded that 43°C is the upper safe limit of temperature for the cortex because cerebral blood flow increases with temperature up to 43°C and thereafter reduces with a further rise in temperature. At temperatures >45°C, the cerebral blood flow was only 10% of normal baseline blood flow. Matsumi *et al.*<sup>[8]</sup> demonstrated coagulative necrosis in areas of monkey brain exposed to a focal temperature of more than 44°C. He found that these changes started 6 h after exposure to heat and were complete by 16 h after exposure.

In our study, we have recorded maximum temperatures of 47.3°C and 53.9°C with 3.5 mm and 4.8 mm cable and 100% light intensity. A rapid rise in temperature was noted in the first 6 min; thereafter only 1-2°C increase was noted for next 8 min. Similar observations were made by Matsumi *et al.*<sup>[8]</sup> which leads to the conclusion that maximum thermal injury to tissues occurs in the first 6 min of endoscopic surgery. Hence,

withdrawing the endoscope after every 10 min of dissection or turning off the light source intermittently at the same interval may reduce the incidence of thermal injury-related complications.

Since the working distance between the tip of the endoscope and target during a procedure is more or less constant (usually 1-2 cm), we recommend an alteration in the other parameters to reduce the incidence of thermal injury-related complications. Based on the observations made in our study, we recommend a 3.5 mm optical cable, light intensity of 60% and an ambient temperature of 20°C during an endoscopic procedure. We also recommend withdrawal of the endoscope when not required inside and irrigation with saline. More dedicated studies are required to determine the actual incidence of thermal injury to human brain tissue during endoscopy and efforts must be undertaken to formulate the alleviating factors.

## Conclusions

Endoscopic excision of large skull base tumors or endoscopic assisted neurosurgery usually takes prolonged operative time. Rapid rise of temperature at operative site can cause thermal injury to normal brain tissue. This may be the cause of newer postoperative endocrine/neurological deficits or worsening of the already existing deficits. It is important to use the correct diameter optical cable, appropriate light intensity and work at a lower room temperature for reducing the thermal injury-related complications.

## Financial support and sponsorship

Nil.

## Conflicts of interest

There are no conflicts of interest.

## References

1. Nasrin F, Dusick JR, Mattozo C, Mc Arthur DL, Cohan P, Boscordin J. Pituitary Hormonal loss and Recovery after Trans-Sphenoidal Adenoma Removal. *Neurosurgery* 2008;62:709-19.
2. Fatemi N, Dusick JR, de Paiva Neto MA, Kelly DF. The endonasal microscopic approach for pituitary adenomas and other parasellar tumors: A 10-year experience. *Neurosurgery* 2008;63:244-56.
3. Schaberg MR, Anand VK, Schwartz TH, Cobb W. Microscopic versus endoscopic transnasal pituitary surgery. *Curr Opin Otolaryngol Head Neck Surg* 2010;18:8-14.
4. Teo C, Nakaji P, Mobbs RJ. Endoscope-assisted microvascular decompression for trigeminal neuralgia: Technical case report. *Neurosurgery* 2006;59:ONSE489-90.
5. Yadav YR, Parihar V, Agarwal M, Sherekar S, Bhatlele P. Endoscopic vascular decompression of the trigeminal nerve. *Minim Invasive Neurosurg* 2011;54:110-4.
6. Maric A, Kruljac I, Cerina V, Pecina HI, Šulentic P, Vrkljan M. Endocrinological outcomes of pure endoscopic transsphenoidal surgery: A Croatian Referral Pituitary Center experience. *Croat Med J* 2012;53:224-33.
7. Ohmoto Y, Fujisawa H, Ishikawa T, Koizumi H, Matsuda T, Ito H. Sequential changes in cerebral blood flow, early neuropathological consequences and blood-brain barrier disruption following radiofrequency-induced localized hyperthermia in the rat. *Int J Hyperthermia* 1996;12:321-34.
8. Matsumi N, Matsumoto K, Mishima N, Moriyama E, Furuta T, Nishimoto A, *et al.* Thermal damage threshold of brain tissue – Histological study of heated normal monkey brains. *Neurol Med Chir (Tokyo)* 1994;34:209-15.