

## CASE REPORT

# Primary aneurysmal bone cyst of the petrous temporal bone: A case report and review of literature

Mayur Sharma, Vernon Velho, Hrushikesh Kharosekar

Department of Neurosurgery, Grant Medical College and Sir J.J Group of Hospitals, Byculla, Mumbai, Maharashtra, India

## ABSTRACT

Aneurysmal bone cyst (ABC) arising in the petrous portion of the temporal bone is a rare entity with only five such reported cases in the literature. We report the case of a 28-year-old man who presented with a tender swelling in the right preauricular region with right ear discharge and conductive hearing loss of 4 years' duration. Computed tomography and Magnetic Resonance imaging showed a destructive lesion in the right petrous bone with cavitation consistent with the diagnosis of ABC. Gross total resection of the lesion was achieved and diagnosis was confirmed histologically. The patient had no recurrence at 12 months of follow-up. This report presents the unusual location of an uncommon bony tumor with a review of its clinical, radiological, and histopathological features as well as the treatment modalities available.

**Key words:** Aneurysmal, cyst, petrous, primary, temporal

## Introduction

Aneurysmal bone cysts (ABCs) are rare, benign, rapidly growing, non-neoplastic osteolytic expansile lesions. This entity was first described by Jaffe and Lichtenstein in 1942.<sup>[1]</sup> ABCs most commonly originate in the metaphyseal region of the long bones, vertebrae and flat bones with a tender bony swelling. They usually affect the patients in their first or second decades and constitute 1-6% of all primary bone tumors.<sup>[2]</sup> Involvement of the skull bones by the ABCs is a rare occurrence with an incidence of 3-6% of all ABCs.<sup>[3]</sup> ABC in the temporal bone is even rarer with only 39 histologically confirmed cases in the literature. Moreover, there are only five reported cases of the ABCs arising in the petrous portion of the temporal bone [Table 1].<sup>[4-8]</sup> We present a rare case of ABC arising in the petrous portion of the temporal bone in a 28-year-old man who presented with right ear discharge, conductive hearing loss, and tender bony swelling.

## Case Report

A 28-year-old man presented to the outpatient department with complaints of chronic pain over the right preauricular region for the last 4 years. The pain was gradual in onset and progressive in nature. Pain was aching in nature with the sensation of heaviness over the right preauricular region. There was no history of diminished or altered sensations over the face. There was also history of intermittent serous discharge from the right ear for the last 4 years. Patient had also noticed diminished hearing in the right ear with the onset of discharge. He denied any history of trauma, seizures, vomiting, fever, or other associated symptoms. In view of these symptoms, patient was diagnosed to have chronic suppurative otitis media and underwent mastoidectomy twice over a period of 4 years at other institute.

On examination, higher mental functions were normal. There was conductive hearing loss in the right ear, Rinne's test was negative, and Weber's test was lateralized to the right ear. Facial nerve function was normal. Rest of the cranial nerves and neurological examination was normal. On local examination, a tender bony hard swelling of 3 cm × 2 cm × 2 cm size was felt in the right preauricular region. There were no other signs of inflammation over the swelling. The scar of previous surgery was well healed.

Computed tomography (CT) scan of the brain with and without contrast revealed an extradural heterogeneously enhancing mass in the right temporomastoid region [Figure 1]. MRI scan of the brain showed an extra-axial solid cystic lesion in the right temporomastoid region. The lesion was hypo to isointense on

### Access this article online

#### Quick Response Code:



#### Website:

www.asianjns.org

#### DOI:

10.4103/1793-5482.145327

### Address for correspondence:

Dr. Mayur Sharma, Department of Neurosurgery, Grant Medical College and Sir J. J. Group of Hospitals, Byculla, Mumbai - 400 008, Maharashtra, India. E-mail: drmayursharmaneuro@gmail.com

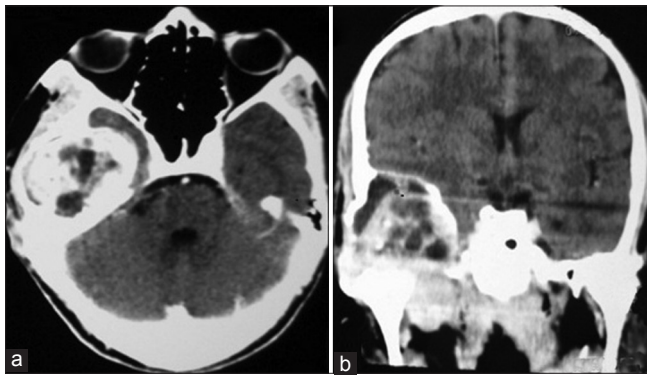
T-1 weighted, heterogeneously hyperintense on T-2 weighted and showed heterogeneous enhancement on gadolinium contrast images [Figure 2]. Preoperative digital subtraction angiography was showing a tumour blush in the right temporal skull base and adjacent middle fossa. The predominant vascular supply was from the right middle meningeal artery. The right petrous carotid artery was encased by the tumor.

The patient underwent a right temporal craniectomy with wide exposure of the petrous bone. The tumor was devascularized by coagulating the middle meningeal artery early in the procedure. The tumor was located in the middle temporal fossa outside the temporal dura mater. The lesion was variegated in appearance and had a well-formed capsule. There were cystic spaces within the tumor which were filled with straw-colored fluid. The lesion was densely adherent to the temporal dura mater with extensive destruction of normal surrounding bone, however, there was no evidence of breach in the surrounding duramater. A small portion of the tumor which was extending toward the base of the skull was left behind. An en bloc gross total excision was achieved.

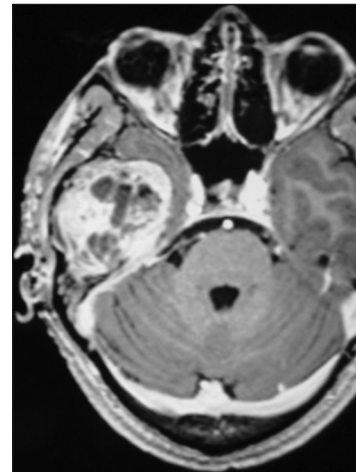
Histopathological examination had shown thin bony trabeculae which were enclosing the dilated blood-filled spaces. These septae consist of fibrocollagenous tissue admixed with loosely woven bone and multinucleate giant cells. There was no evidence of malignancy. These histological features with the clinical presentation were characteristic of ABCs [Figure 3].

In the immediate post-operative period, the patient had grade 2 (House and Brackmann) Facial paresis which had recovered back to normal with a short course of steroids at the first follow-up. Post-operative CT scan had shown the gross total excision of the tumor except the portion which was extending to the skull base [Figure 4].

At the last follow-up of 12 months, the facial nerve function was normal and hearing in the right ear had improved on clinical examination.



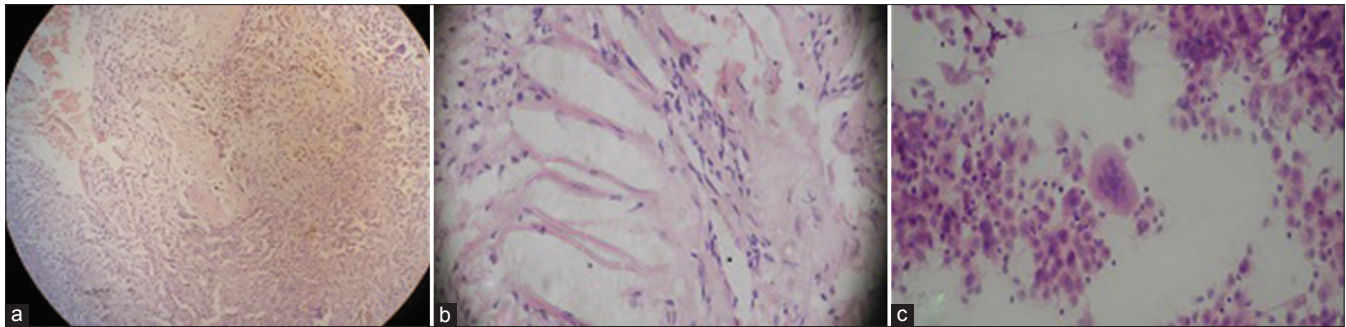
**Figure 1:** Computed tomography scan of the brain with contrast (a) axial view (b) coronal view showing an extradural, heterogeneously enhancing lesion in the right temporomastoid region



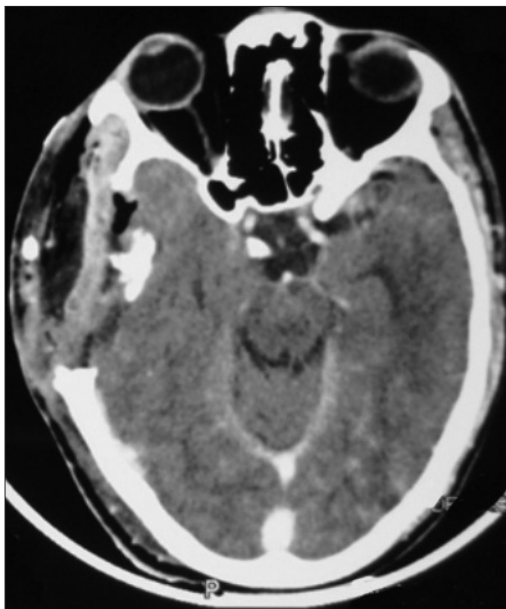**Figure 2:** Magnetic resonance imaging (axial view) scan of the brain with gadolinium contrast showing an extra-axial, solid cystic lesion with heterogeneous enhancement in the right temporomastoid region

**Table 1: Cases of aneurysmal bone cysts involving the petrous portion of the temporal bone reported in the literature**

Authors	Gender/Age (years)	Location	Presentation	Management	Recurrence
Legent <i>et al.</i> 1988 <sup>[8]</sup>	F/23	Right temporo-occipital region	Otalgia, endolabyrinthine type perception deafness	Curettage	Not known
Lackmann <i>et al.</i> 1993 <sup>[5]</sup>	M/8	Right petrous temporal bone	Recurrent meningitis	Total resection	No recurrence till 1 month
Muzumdar <i>et al.</i> 2004 <sup>[5]</sup>	M/18	Right petrous temporal bone	Right facial nerve paresis, right ear sensorineural hearing loss	Complete excision in a piecemeal fashion	No recurrence at 18 months after surgery
Kumar <i>et al.</i> 2006 <sup>[7]</sup>	M/30	Right petrous temporal bone	Right ear conductive hearing loss, vertigo, dizziness	Near complete excision with radiotherapy for recurrent lesion after 2 months	Recurrence at 2 months follow up
Sayama <i>et al.</i> 2010 <sup>[4]</sup>	F/16	Right petrous temporal bone	Right facial nerve paresis, right ear hearing loss and pain, right facial numbness and tingling	Complete excision	No recurrence at 32 months follow up
Present report	M/28	Right petrous temporal bone	Right preauricular swelling, right ear discharge with conductive hearing loss	Near complete excision	No recurrence at 12 months follow up



**Figure 3:** Neuropathological examination (a) low power view (b) high power view showing thin bony trabeculae enclosing the dilated blood-filled spaces (c) High power view demonstrating a multinucleate giant cell



**Figure 4:** Post-operative computed tomography scan of the brain with contrast showing gross total excision of the lesion

## Discussion

ABC was first described by Jaffe and Lichtenstein as a separate clinical entity in 1942.<sup>[1]</sup> They described it as an expanding bony lesion with a vascular lining and the classical “soap bubble” appearance on radiological examination. ABCs are benign, expansile thin-walled osteolytic bony lesions. They usually affect the patients in their first or second decade of life.<sup>[2,9]</sup> Females are more commonly affected than males (1.2:1).<sup>[10]</sup> The most common site of origin is the metaphysis of the long bones, flat bones, and the posterior elements of the vertebrae. Origin from the skull bones is a rare entity and constitutes 3-6% of all ABCs.<sup>[3,11]</sup> Our case is unique in that it is probably the sixth reported case of the ABC with an origin in the petrous portion of the temporal bone which presented with preauricular swelling.

ABCs can be primary (*de novo*) or secondary in association with other pre-existing benign bone lesions such as osteoblastoma, chondroblastoma, chondromyxoid fibroma, giant cell tumour,

or fibrous dysplasia.<sup>[11]</sup> The pathogenesis of ABCs is not yet clear, although many theories have been proposed suggesting its origin. Lichtenstein proposed that the alteration in the focal vascular dynamics with secondary venous hypertension leads to the slow expansion of the cortex and the development of the cyst. ABC has also been considered as a secondary lesion due to an underlying arteriovenous anomaly in a preexisting primary bone pathology, which seems to explain the histological features and the natural history of these cysts.<sup>[12]</sup> Local trauma has also been proposed in the development of these cysts. Our case neither had associated pre-existing lesion in the right temporal area nor had history of trauma preceding the onset of swelling. Thus, it can be considered as primary ABC of the temporal bone.

The presenting symptoms of the temporal ABCs can be a swelling around the temporal region which may or may not be painful, focal neurological deficit, conductive hearing loss, headache, signs of raised intracranial pressure, and cranial nerve involvement (5<sup>th</sup>, 7<sup>th</sup>, rarely 3<sup>rd</sup>) depending upon the location and size of the lesion.<sup>[3-5,8,10,13]</sup> Rarely, patient can present with signs and symptoms of recurrent bacterial meningitis.<sup>[6]</sup> Our patient presented with painful swelling and hearing loss of 4 months’ duration.

ABCs have a characteristic appearance of “blown out” or “soap bubble” with a surrounding rim of sclerosis and periosteal new bone formation on plain skull radiographs.<sup>[14]</sup> On contrast enhanced computed tomography (CECT) scan, ABCs appear as multiloculated lesion within the diploe of the skull with characteristic fluid-fluid levels. The capsule and internal septations show enhancement with the intravenous contrast agent. Magnetic resonance imaging (MRI) also reveals an expansile multiloculated lesion with internal septations.<sup>[11,15]</sup> Angiography may reveal abnormal tumor blush with areas of delayed venous phase and arteriovenous shunts.<sup>[4]</sup> In our case, the tumor had abnormal blush which was supplied by the right middle meningeal artery.

On gross histological examination, ABCs appear to be multicystic spaces which are separated by fibrous septae. These sinusoidal spaces are filled with hemorrhagic fluid and

are lined with flattened fibroblasts with interspersed giant cells instead of endothelium.<sup>[4,7]</sup> Our case had similar characteristic appearance on histology. The differential diagnosis of ABCs includes telangiectatic osteosarcoma, hemangioma, solitary bone cyst, and giant cell reparative granuloma.<sup>[16]</sup>

Various treatment modalities for ABCs include en-bloc resection, curettage with bone grafting, embolization, cryosurgery, and radiotherapy.<sup>[4]</sup> However, en-bloc or complete resection is the treatment of choice to achieve cure and prevent recurrences. Curettage alone is associated with high recurrence rate of 21-68%.<sup>[16]</sup> Radiotherapy alone may induce sarcomatous changes, however, it can be considered for residual or recurrent lesions (in the dose of 20-60 Gy).<sup>[7]</sup>

## Conclusion

This report presents the unusual location of an ABC in the petrous temporal bone. Imaging and histological findings are characteristic. En-bloc resection is the treatment of choice to achieve cure. Radiotherapy can be considered for residual or recurrent lesion.

## Acknowledgments

We would like to thank our Dean, Sir J. J. Group of Hospitals for allowing us to publish the hospital record.

## References

1. Jaffe HL. Solitary unicameral bone cyst: With emphasis on the roentgen picture, the pathologic appearance, and the pathogenesis. *Arch Surg* 1942;44:1004-25.
2. Cakirer S, Basak M, Celebi I, Kabukcuoglu F, Erdem Y. Aneurysmal bone cyst of the temporal bone. *Curr Probl Diagn Radiol* 2003;32:169-75.
3. Ameli NO, Abbassioun K, Azod A, Saleh H. Aneurysmal bone cyst of the skull. *Can J Neurol Sci* 1984;11:466-71.
4. Sayama CM, MacDonald JD. Aneurysmal bone cyst of the petrous bone: Case presentation and review of the literature. *Pediatr Neurosurg* 2010;46:308-12.
5. Muzumdar DP, Goel A, Mistry R, Gujral S, Fattepurkar S. Postoperative cerebellar herniation in a large intrapetrous aneurysmal bone cyst. *J Clin Neurosci* 2004;11:534-7.
6. Lackmann GM, Töllner U. Aneurysmal cyst of the petrosal bone. *Arch Dis Child* 1993;69:241-2.
7. Kumar P, Singh S, Phadke RV, Diwakar H, Agarawal T, Jain M, *et al.* Role of radiotherapy in a recurrent aneurysmal bone cyst of the temporal bone: Case report. *Neurosurgery* 2006;58:E584.
8. Legent F, Lenne Y, Gayet M, de Kersaint-Gilly A, Beauvillain C, Desgraviens B, *et al.* Aneurysmal cyst of the petrous bone. Apropos of a case. *Annales d'oto-laryngologie et de chirurgie cervico faciale: Bulletin de la Societe d'oto-laryngologie des hopitaux de Paris*. 1988;105(8):591-596.
9. Kumar R, Mukherjee KK. Aneurysmal bone cysts of the skull: Report of three cases. *Br J Neurosurg* 1999;13:82-4.
10. Vergel De Dios AM, Bond JR, Shives TC, McLeod RA, Unni KK. Aneurysmal bone cyst. A clinicopathologic study of 238 cases. *Cancer* 1992;69:2921-31.
11. Lippman CR, Jallo GI, Feghali JG, Jimenez E, Epstein F. Aneurysmal bone cyst of the temporal bone. *Pediatr Neurosurg* 1999;31:219-23.
12. Biesecker JL, Marcove RC, Huvos AG, Miké V. Aneurysmal bone cysts. A clinicopathologic study of 66 cases. *Cancer* 1970;26:615-25.
13. Haddad GF, Hambali F, Mufarrij A, Nassar A, Haddad FS. Concomitant fibrous dysplasia and aneurysmal bone cyst of the skull base. Case report and review of the literature. *Pediatr Neurosurg* 1998;28:147-53.
14. Tuna H, Karatas A, Yilmaz ER, Yagmurlu B, Ereku S. Aneurysmal bone cyst of the temporal bone: Case report. *Surg Neurol* 2003;60:571-4.
15. Chateil JF, Dousset V, Meyer P, Pedespan JM, San-Galli F, Rivel J, *et al.* Cranial aneurysmal bone cysts presenting with raised intracranial pressure: Report of two cases. *Neuroradiology* 1997;39:490-4.
16. Sabatini PR, Horenstein MG, Oliveri CV, Gacek RR. Aneurysmal bone cyst of the temporal bone associated with reversible hemifacial paralysis. *Am J Otolaryngol* 2005;26:261-4.

**How to cite this article:** Sharma M, Velho V, Kharosekar H. Primary aneurysmal bone cyst of the petrous temporal bone: A case report and review of literature. *Asian J Neurosurg* 2016;11:444-5.

**Source of Support:** Nil, **Conflict of Interest:** None declared.