

CASE REPORT

Primary cerebellopontine angle glioblastoma in an adult

Souvagya Panigrahi, Sudhansu S. Mishra, Srikant Das

Department of Neurosurgery, S. C. B. Medical College and Hospital, Cuttack, Odisha, India

ABSTRACT

Supratentorial glioblastoma is the most frequent primary intracranial tumor in adults. Its localization in the cerebellum is extremely rare and such tumor presenting as cerebellopontine angle (CPA) mass in an adult is even rarer. We report the case of primary cerebellar glioblastoma in a 52-year-old woman who presented clinically and radiologically as CPA mass. Its clinical presentation, radiological findings, and treatment instituted are discussed in view of pertinent literature.

Key words: Adults, cerebellopontine angle mass, glioblastoma, primary

Introduction

Most lesions involving the cerebellopontine angle (CPA) are located extra-axially and are usually acoustic schwannomas or meningiomas. Other less common lesions include epidermoid tumors, metastases, and arachnoid cysts. Glioblastomas of the CPA are rare. A tumor arising from the brain parenchyma may become exophytic and manifest in the CPA. Regardless of the site of origin, tumors in the CPA present with sign and symptoms resulting from compression of fifth, seventh, and eighth cranial nerves and lateral aspect of pons and cerebellar peduncle. It is very important for the neurosurgeon to make the differential diagnosis between these lesions because their treatment modalities, prognosis, and outcome are different. Clinical manifestations of these diseases are very similar, so making an appropriate diagnosis is fundamental for the management of each of them.

Case Report

A 52-year-old lady presented with a 2-month history of giddiness, blurred vision, and difficulty in walking. She had worsening headaches, vomiting, and gait ataxia with swaying to left for the last 20 days. On physical examination, she was

well nourished, afebrile, and in no acute distress. Her vital signs were stable. On neurological examination, she was alert and fully oriented. Her pupils were equally round and reacted to light. Cranial nerve examination revealed bilateral sixth paresis with left seventh minimal paresis and reduced hearing on the left side. Finger-to-nose examination revealed dysmetria on the left. Her left lower extremity was slightly weak and sensory testing was grossly normal. A working diagnosis of CPA space-occupying lesion was made.

Computed tomographic (CT) scan of the head showed an ill-defined, heterogeneously enhancing left CPA mass with mild perifocal edema [Figure 1a]. Magnetic resonance imaging (MRI) revealed T1 hypointense, T2 hyperintense intra-axial fairly marginated inhomogeneously enhancing mass lesion of size $24 \times 21 \times 24$ mm in left CPA region with mild perilesional edema and mass effect, compressing the fourth ventricle causing mild outflow obstruction [Figure 2]. No evidence of restricted diffusion was seen in diffusion-weighted images (DWIs). Single-voxel magnetic resonance spectroscopy (MRS) of the lesion demonstrated decrease in *N*-acetyl aspartate (NAA) and creatine with raised choline peak, along with increased choline–NAA ratio [Figure 3].

The patient underwent a left retromastoid suboccipital craniectomy in the prone position; brain became lax after draining CSF. After gentle retraction of cerebellum, a pink, fleshy, moderately vascular tumor was seen, which was

This is an open access article distributed under the terms of the Creative Commons Attribution-NonCommercial-ShareAlike 3.0 License, which allows others to remix, tweak, and build upon the work non-commercially, as long as the author is credited and the new creations are licensed under the identical terms.

For reprints contact: reprints@medknow.com

Access this article online	
Quick Response Code: 	Website: www.asianjns.org
	DOI: 10.4103/1793-5482.145323

Address for correspondence:

Dr. Souvagya Panigrahi, Department of Neurosurgery,
 S. C. B. Medical College and Hospital, Cuttack, Odisha, India.
 E-mail: souvagya.ms@gmail.com

How to cite this article: Panigrahi S, Mishra SS, Das S. Primary cerebellopontine angle glioblastoma in an adult. *Asian J Neurosurg* 2017;12:62-4.

apparently encapsulated on the lateral aspect but had indistinct margins on the cerebellar side. A near-total resection was achieved using microsurgical technique with minimal handling of cranial nerves. Histological examination of the removed tumor specimens showed a cellular tumor composed of elongated, spindle-shaped cells with irregular, moderately pleomorphic nuclei, as well as proliferative blood vessels and necrosis [Figure 4a]. The presence of glial fibrillary acidic protein (GFAP) in immunohistochemistry staining confirmed the glial origin of the neoplasm [Figure 4b].

Postoperative course was uneventful, and her hearing and facial paresis improved immediately and sixth nerve paresis improved over the next few days. CT scan head done on second postoperative day showed adequate decompression of the left CPA region [Figure 1b]. She was subjected to whole posterior fossa fractionated radiotherapy starting 4 weeks after surgery. At the 3-month follow-up, she was conscious and alert without any complaint.

Discussion

Glioblastomas are the most frequent primary intracranial tumor in adults, with a frequency about 15%-20%.^[1] These are infiltrating tumors located in the deep white matter or in the deep gray matter neighboring white matter, mainly in cerebral hemispheres. Their localization in the cerebellum is extremely rare,^[2] and such tumor presenting as CPA mass is even rarer.^[3,4] They develop secondary to diffuse or anaplastic astrocytomas. However, they can sometimes occur primarily.^[5]

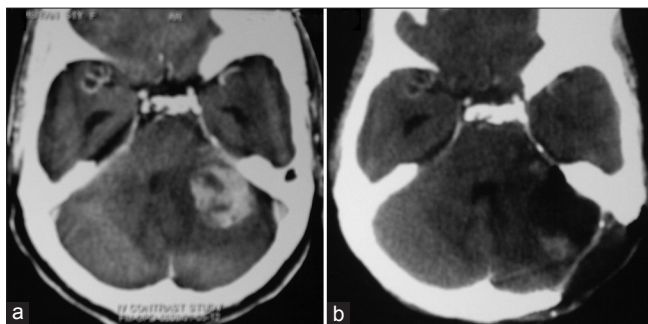


Figure 1: Contrast computed tomographic scan of head showing an ill-defined heterogeneously enhancing left CPA mass with mild perifocal edema (a). Second day postoperative image demonstrates the craniectomy site, adequate decompression of left CPA region with no hemorrhage on the tumor bed (b)

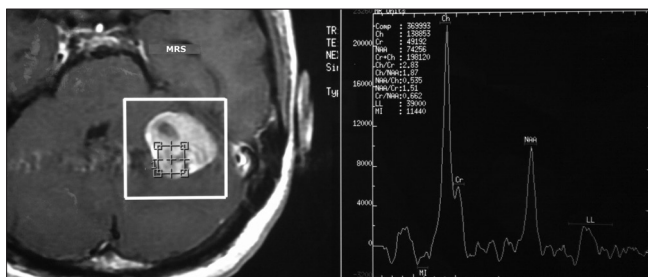


Figure 3: MR spectroscopy (MRS) shows decrease in *N*-acetyl aspartate with raised choline peak, along with increased choline-NAA ratio

Glioblastomas can be seen in all age groups; however, patients are generally over 50 years of age. When compared to childhood tumors, localization in the posterior fossa in adults is rare.^[6,7] Occurrence of primary infratentorial glioblastoma in adults is extremely rare; few cases have been published so far.^[8-10]

Primary cerebellar or brainstem tumors may occupy CPA through either of the two paths: Lateral extension from the fourth ventricle through foramen of Luschka or direct exophytic growth from the site of origin.^[11] It is for the prudent clinician to realize the subtle clinical features of CPA lesions that suggest an intra-axial mass. A short duration of symptoms and rapid progression to brainstem dysfunction and hydrocephalus (like in the present case) are suggestive of a parenchymal lesion rather than an extra-axial mass. Also, an intra-axial lesion should be suspected when hydrocephalus accompanies a moderate-sized CPA tumor.

There remains a substantial overlap in the clinical presentation of intra-axial and extra-axial lesions in the CPA, and diagnostic imaging will always be required. MRI is favored with its high contrast resolution and multi-planar capability. Irregularity of

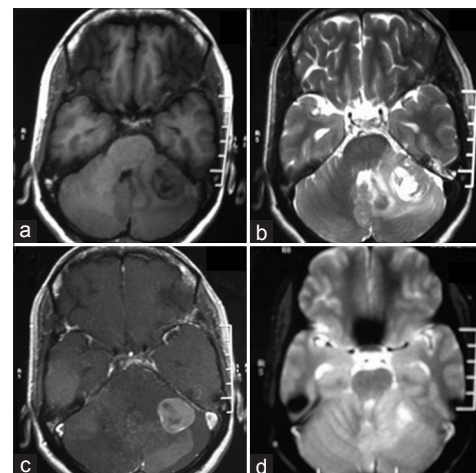


Figure 2: Magnetic resonance (MR) image revealing T1 hypointense (a), T2 hyperintense (b) intra-axial fairly marginated inhomogeneously enhancing (c) mass of size 24 × 21 × 24 mm in left CPA region with mild perilesional edema and mass effect, compressing the fourth ventricle causing mild outflow obstruction. No evidence of restricted diffusion was seen in diffusion-weighted image (d)

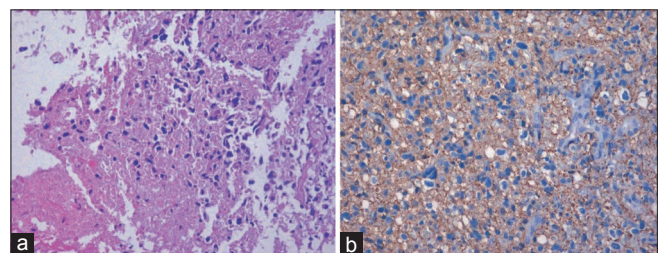


Figure 4: Photomicrograph of the excised specimen showing a cellular tumor composed of elongated, spindle-shaped cells with irregular, moderately pleomorphic nuclei, as well as proliferative blood vessels and necrosis (a: Original magnification ×200). The tumor cells showing cytoplasmic positivity for glial fibrillary acidic protein (b: Original magnification ×200)

the interface between the mass and adjacent brain is the most important feature on MRI to distinguish the two; however, one should remember that with longstanding extra-axial lesion, the interface might be blurred because of encephalomalacia.^[10,11] Bright signal intensity within the adjacent brain and dilation of lateral recess of fourth ventricle may indicate intra-axial lesion.

In the differential diagnosis of posterior fossa glioblastoma in adults, diseases like metastases, abscess, hemangioblastoma, cystic astrocytoma, and entities like infarct, encephalitis, tuberculomas, or multiple sclerosis should be considered. MR diffusion/perfusion imaging and MRS examinations are helpful method in differentiating tumors from other diseases. Solid tumors with central hypodensity suggesting necrosis were described in cerebellar glioblastoma. The typical MRI finding is a heterogeneous mass, isointense to hypointense on T1W and hyperintense on T2W images. Heterogeneous contrast enhancement is present and ring enhancement due to thick irregular wall of the tumor is usually seen.^[12] MRS shows a significant reduction in NAA due to loss of neuronal elements, as well as elevation of choline peak which may reflect increased membrane synthesis. The differences in vascularity and metabolite levels in the periphery of a tumor have been found to be significant for the differentiation of metastases and glioblastoma. The relative cerebral blood volumes in the peritumoral areas calculated with perfusion-weighted MRI are clearly higher in gliomas than in metastases. DWI shows increased signal intensity in abscess and apparent diffusion coefficient (ADC) map demonstrates markedly decreased signal centrally within abscess. But primary or metastatic neoplasm is frequently seen as low signal on DWI.^[13] The contrast enhancement 1-2 weeks after infarction is the so-called “fogging effect” that is probably due to a reduction in edema and leakage of proteins from cell lysis.^[14] However, this lesion shows virtually normal-appearing T2-weighted images.

Considering malignant glial tumors, it would be always reasonable to attempt a gross total tumor resection; however, the infiltrative nature of the glioblastoma makes it difficult to achieve many times.^[15] Though the biological behavior of cerebellar and supratentorial glioblastoma is similar,^[16,17] infratentorial compartment has the special problem of brainstem invasion, which is a known independent prognostic factor affecting survival. Tumor recurrence is almost always local. In very few cases reported, there is also extra-cerebellar failure, including spinal seeding through the CSF. The use of radiation therapy for malignant gliomas is a well-established treatment; however, it remains a matter of debate whether it should be delivered only to the posterior fossa, to the whole brain, or to the neuraxis.^[18] The role of chemotherapy is not fully established, but is the only reasonable complementary therapy for younger children. Considering the fact that the infratentorial glioblastoma’s histological characteristics are equal to the supratentorial ones, it seems reasonable to use concomitant and adjuvant chemotherapy in its treatment.^[19]

Conclusion

In conclusion, primary CPA glioblastoma is extremely rare in adults. However, it must be considered in the differential diagnosis of other intra-axial as well as extra-axial CPA mass lesions. As the surgical and adjunctive management differs in both types, preoperative diagnosis is of great importance. Routine MRI in association with MRS, DWI, and brain perfusion imaging techniques must be used in prospective evaluation.

Financial support and sponsorship

Nil.

Conflicts of interest

There are no conflicts of interest.

References

- Russell DS, Rubinstein LJ. Pathology of tumors of the nervous system. 5th ed. Baltimore: Williams and Wilkins; 1989.p. 219-47.
- Steinberg GK, Shuer LM, Conley FK, Hanbery JW. Evolution and outcome in malignant astroglial neoplasms of the cerebellum. *J Neurosurg* 1985;62:9-17.
- Wu B, Liu W, Zhu H, Feng H, Liu J. Primary glioblastoma of the cerebellopontine angle in adults. *J Neurosurg* 2011;114:1288-93.
- Jindal A, Jaiswal AK, Jaiswal S, Pandey P, Mahapatra AK, Sharma MC. Cerebellar glioblastoma multiforme presenting as a cerebellopontine angle mass. *J Pediatr Neurosci* 2006;1:21-3.
- Vanderberg SR. Current diagnostic concepts of astrocytic tumors. *J Neuropathol Exp Neurol* 1992;51:644-57.
- Kulkarni AV, Becker LE, Jay V, Armstrong DC, Drake JM. Primary cerebellar glioblastoma multiforme in children. Report of four cases. *J Neurosurg* 1999;90:546-50.
- Katz DS, Poe LB, Winfield JA, Corona RJ Jr. A rare case of cerebellar glioblastoma multiforme in childhood: MR imaging. *Clin Imaging* 1995;19:162-4.
- Tamaki T, Eguchi T, Sakamoto M, Teramoto A: Glioblastoma multiforme of the cerebellum in an elderly man. *J Chin Med Assoc* 2004;67:301-4.
- Lobão CA, Barbosa AS, Nogueira J, Aversa A. Cerebellar glioblastoma multiforme in an adult. *Arq Neuropsiquiatr* 2008;66:879-80.
- Kuriowa T, Numaguchi Y, Rothman MI, Zoarski GH, Morikawa M, Zagardo MT, *et al.* Posterior fossa glioblastoma multiforme: MR Findings. *AJNR Am J Neuroradiol* 1995;16:583-9.
- Ahn MS, Jackler RK. Exophytic brain tumors mimicking primary lesions of the cerebellopontine angle. *Laryngoscope* 1997;107:466-71.
- Dorman GJ, Dunsmore RH. Glioblastoma multiformis of cerebellum. *Surg Neurol* 1975;3:219-23.
- Lai PH, Ho JT, Chen WL, Hsu SS, Wang JS, Pan HB, *et al.* Brain abscess and necrotic brain tumor: Discrimination with proton MR spectroscopy and diffusion-weighted imaging. *AJNR Am J Neuroradiol* 2002;23:1369-77.
- Asato R, Okumura R, Konishi J. “Fogging effect” in MR of cerebral infarct. *J Comput Assist Tomogr* 1991;15:160-2.
- Demir MK, Hakan T, Akinci O, Berkman Z. Primary cerebellar glioblastoma multiforme. *Diagn Interv Radiol* 2005;11:83-6.
- Luccarelli G. Glioblastoma multiforme of the cerebellum: Description of three cases. *Acta Neurochir (Wien)* 1980;53:107-16.
- Rosenfeld J, Rossi ML, Briggs M. Glioblastoma multiforme of the cerebellum in an elderly man. A case report. *Tumori* 1989;75:626-9.
- Kopelson G, Lingood R. Infratentorial glioblastoma: The role of neuraxis irradiation. *Int J Radiat Oncol Biol Phys* 1982;8:999-1003.
- Stupp R, Mason WP, van den Bent MJ, Weller M, Fisher B, Taphoorn MJ, *et al.*; National Cancer Institute of Canada Clinical Trials Group. Radiotherapy plus concomitant and adjuvant temozolomide for glioblastoma. *N Engl J Med* 2005;352:987-96.