

## CASE REPORT

# *Nocardia farcinica* abscess of the cerebellum in an immunocompetent patient: A case report and review of the literature

María Pascual-Gallego, Pedro Alonso-Lera, Ana Arribi<sup>1</sup>, Juan A. Barcia, Javier Marco<sup>2</sup>

Departments of Neurosurgery, <sup>1</sup>Microbiology, <sup>2</sup>Internal Medicine, Hospital Clínico San Carlos, Universidad Complutense de Madrid, Madrid, Spain

## ABSTRACT

*Nocardial* brain abscesses are uncommon and rarely occur in patients without predisposing factors. They may be mistaken for gliomas or necrotic metastases, and surgical intervention may be required to make the diagnosis. We report the first case of *Nocardia farcinica* cerebellar abscess in a patient without immunosuppression. He presented to us with headache and instability beginning a week before. Brain magnetic resonance imaging (MRI) revealed a cystic lesion located at the right cerebellar hemisphere, hypointense in T1 and hyperintense in T2, with a fine wall that enhanced after injection of gadolinium. Image tests also showed a cavitated lesion at the upper lobule of the right lung. The patient underwent craniotomy and drainage of the cerebellar abscess. Initial post-operative treatment with linezolid produced a limited response. He was re-operated and vancomycin, imipenem and ciprofloxacin were added with an excellent outcome of the cerebellar and lung lesions.

**Key words:** Cerebellar abscess, immunocompetent, nocardia

## Introduction

*Nocardial* brain abscesses are uncommon and rarely occur in patients without immunosuppression.<sup>[1]</sup> Cerebral nocardiosis is associated with significant morbidity and mortality (34%), highest with brain abscess.<sup>[2,3]</sup> Brain abscesses due to *Nocardia* presented in immunocompetent patients are often misdiagnosed as malignant brain tumors,<sup>[4,5]</sup> and surgical intervention may be required to make the diagnosis. We report the first case of cerebellar abscess due to *Nocardia farcinica* in a patient without immunosuppression. The clinical presentation, differential diagnosis, and treatment of this rare disorder are discussed, and a literature review is made.

## Case Report

A 62-year-old male presented to us with headache and instability beginning a week before, with no other associated symptoms. An emergency CT scan showed a cerebellar mass. There were no medical antecedents of interest, except for previous surgery for an olfactory groove meningioma 11 years earlier without any complications. On admission, blood count showed leucocytosis ( $12.1 \times 10^3/\mu\text{L}$ ) and neutrophilia (91.5%), a globular sedimentation rate of 60 mm/h, and C reactive protein of 1.80 mg/dl. A detailed laboratory investigation revealed that this patient was immunocompetent. A chest x-ray and a thoracic CT scan showed a cavitated lesion at the upper lobule of the right lung [Figure 1].

Brain magnetic resonance imaging (MRI) revealed a well-demarcated mass of 3.6 cm in diameter located at the right cerebellar hemisphere surrounded by vasogenic edema, hypointense in T1, and hyperintense in T2 [Figure 2]. The images were of cystic appearance, bilobulated, with a fine wall that enhanced after injection of gadolinium [Figure 3]. A body extension study ruled out any other metastatic lesion.

A suboccipital craniotomy was performed, and a cerebellar mass with a necrotic or abscessified content was removed. The histological study disclosed a cerebellar abscess and capsule.

A sample of cerebellar tissue obtained at the operating room was sent to the microbiology laboratory and cultured in

### Access this article online

#### Quick Response Code:



#### Website:

www.asianjns.org

#### DOI:

10.4103/1793-5482.145179

### Address for correspondence:

Dr. Maria Pascual-Gallego, Department of Neurosurgery, Hospital Clínico San Carlos, Universidad Complutense, Avd. Profesor Martín Lagos s/n Madrid, Madrid, Spain.  
E-mail: mariapascualgallego@gmail.com

standard medium for bacteria and fungi under aerobic and anaerobic conditions at 35°C for 10 days. At 48 hours on the aerobic plaques, small grayish colonies, later identified as ramified Gram-positive cocobacilli positive for urease and catalase were evident. Sensibility tests were performed by E-test® (BD Biodisk, Sweden), with the following minimum inhibitory concentrations (MIC in mg/ml): trimethoprim–sulfamethoxazole 0.064, levofloxacin 0.008, erythromycin 0.125, vancomycin 0.032, imipenem 0.25, linezolid 0.016, daptomicin 256.

Linezolid (600 mg/12 h) was given to the patient with clinical and neurological improvement in the following weeks.

The chest x-rays performed after surgery showed an increase of size of the lesion. Sixteen days after surgery, the patient showed a sudden decrease of consciousness, with a GCS drop from 15 to 10.

An emergency CT scan showed cerebellar swelling and acute hydrocephalus. The patient was immediately operated upon, placing a right external ventricular drainage.

This second time *Nocardia* was again isolated by the same techniques in cerebrospinal fluid after 17 days of culture. MIC of tested antibiotics was similar except for imipenem (32 mg/ml). Isolates were sent to a reference laboratory and later identified as *N. farcinica* by 16S rRNA sequencing.

Antibiotics were changed to vancomycin, imipenem, and ciprofloxacin. Intraventricular vancomycin (1,000 mg/12 h) was also administered.

Chest x-rays showed improvement of the lung lesion, and a transient clinical improvement, but headache recurred after attempts to close the drainage. A control MRI showed a new cystic collection with ring enhancement after injection of gadolinium at the surgical cavity with diffusion restriction at the lower part of cyst that suggested abscess. The patient was re-operated, and an abscess was again found and removed. Again, *N. farcinica* was identified at the purulent collection. Antibiotic therapy was changed to linezolid and ciprofloxacin following culture results. The patient improved favorably and has been asymptomatic until the last control, 14 months later. The control MRIs showed changes due to surgery with no relapse signs [Figure 4].

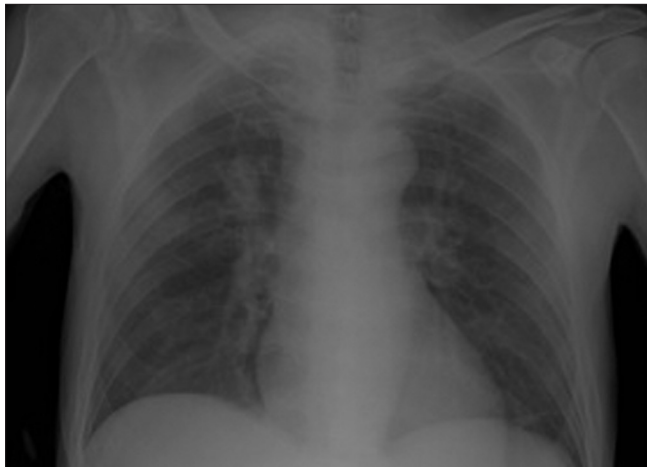


Figure 1: Chest x-ray

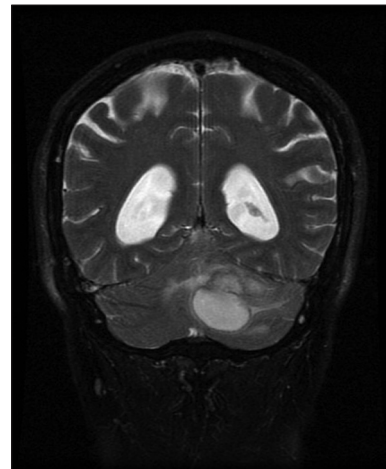


Figure 2: T2W coronal image

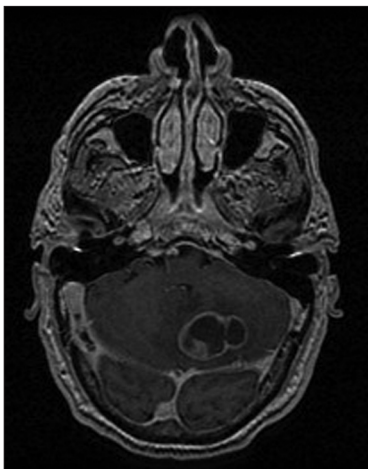


Figure 3: T1W axial post-contrast image

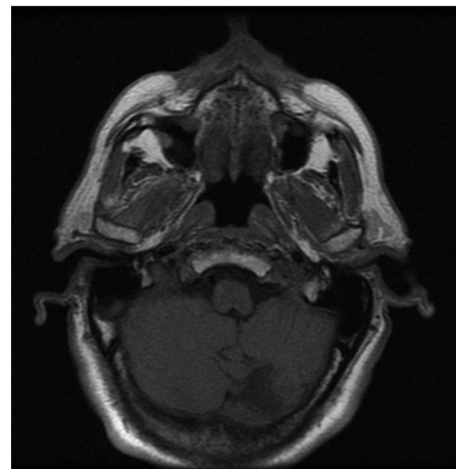


Figure 4: Postoperative T1W post-contrast image

## Discussion

There are at least 30 known species of *Nocardia*, but most of the cases described in humans are due to *N. asteroides* and *N. farcinica*. *N. farcinica* is a Gram-positive branching filamentous bacillus causing many localized and disseminated infections in humans, including pulmonary and wound infections, brain abscesses, and bacteremia.<sup>[6]</sup>

Central nervous system infection can present in the form of meningitis or abscess. However, nocardial brain abscesses are uncommon and are not always preceded by clear infective symptoms.<sup>[1]</sup> Nocardiosis is an infrequent disease that affects most frequently patients who display a cellular immunodeficiency, such as transplant recipients on immunosuppressive treatment, but uncommonly associated with patients with no underlying risk factors.<sup>[5,6]</sup> Clinical and microbiologic spectrum of nocardiosis has changed recently due to the widespread use of cotrimoxazole prophylaxis, the emergence of new types of immunosuppressed patients, and the improved identification of isolates using molecular techniques.

There have been reported seven cases of brain abscesses due to *N. farcinica* in patients without immunocompromise until now.<sup>[1,2,7-11]</sup> All of them were supratentorial and unique lesions. Only one of the seven was a woman,<sup>[8]</sup> and the clinical manifestations were focal neurological deficits and seizures due to the location, being difficult to make a differential diagnosis with a tumor only with the symptoms. All of them underwent surgical resection and antibiotherapy, with a good outcome and complete improvement in all cases except one<sup>[1]</sup> that had a residual weakness of the left hand secondary to the surgery. There was only one case<sup>[10]</sup> that had an associated lung lesion and another one that was associated with a pulmonary embolism.<sup>[8]</sup>

In our case, the primary infection was most probably the lung after acquiring the bacteria through the airway. The patient was a hunter and it could have been easy to encounter the infectious agent in this media. Two aspects make our case rather exceptional: The fact that the immunologic study did not reveal any type of immunosuppression and the location of the abscess in the cerebellum.

Exposure to the germ is often difficult to suspect from the past medical history of the patient, and even if the patient has been exposed to the germ, if he is immunocompetent, difficult to suspect.

Abscesses are mainly located in the brain stem, basal ganglia, and cerebral cortex of the frontal, parietal, and occipital lobes. Cerebellar and spinal locations are uncommon. The clinical features of nocardia brain abscess are insidious and non-specific, occurring frequently with a medical background

of obvious or latent immunodeficiency; fever, if any, is observed subordinate to extracerebral nocardiosis.<sup>[12]</sup> Focal neurological deficits and seizures are the most common clinical manifestations in patients with brain abscesses caused by *Nocardia*,<sup>[2,5,6]</sup> like in patients with abscesses caused with another etiology.

Based on imaging, the differential diagnosis includes gliomas and necrotic metastases. Computerized tomography scan (CT) and conventional magnetic resonance (MR) show lesions with a necrotic core and multilobed thick walls enhancing after injection of gadolinium or iodine, like other cerebral abscesses. To prevent a delay in diagnosis and treatment, an aggressive therapeutic approach is required, being craniotomy usually required instead of aspiration and drainage alone due to the thick wall and multiloculations of the abscesses.

*Nocardia* spp. are resistant to the antibiotics used for the empirical treatment of cerebral abscesses, like third-generation cephalosporins and metronidazole.<sup>[13]</sup> *Nocardia* species are difficult to culture and have a tendency to slow growth. Bacteriological identification has progressed with advances in molecular microbiology: 16S rRNA gene universal PRC method, allowing a more rapid routine identification of nocardia strains from clinical samples.<sup>[14]</sup> Most nocardia strains display susceptibility to imipenim, amikacin, trimethoprim-sulfamethoxazole, and linezolid,<sup>[5,7,15,16]</sup> but develop beta-lactamase activity.

Clinical management of patients with a nocardia brain abscess relies upon early use of intravenous antibiotics adapted to the strains identified and their susceptibility.<sup>[17]</sup> In some rare cases, like in our case, *N. farcinica* can be resistant to numerous antibiotics requiring adjustments of medical management. Early identification of the bacteria is necessary to achieve good outcome in immunocompetent patients.<sup>[10]</sup>

## Conclusion

Brain abscess caused by *Nocardia farcinica* is an infrequent entity exceptionally observed in patients without immunocompromise. Rapid identification and appropriate antibiotic treatment, together with a surgical approach, are the clue to success.

## References

1. Fellows GA, Kalsi PS, Martin AJ. *Nocardia farcinica* brain abscess in a patient without immunocompromise. Br J Neurosurg 2007;21:301-3.
2. Chung TT, Lin JC, Hsieh CT, Chen GJ, Ju DT. *Nocardia farcinica* brain abscess in an immunocompetent patient treated with antibiotics and two surgical techniques. J Clin Neurosci 2009;16:1675-7.
3. Patil A, Cherian A, Iype T, Sandeep P. Nocardial brain abscess in an immunocompetent individual. Neurol India 2011;59:779-82.
4. Menkü A, Kurtsoy A, Tucer B, Yildiz O, Akdemir H. Nocardia brain abscess mimicking brain tumour in immunocompetent patients: Report of two cases and review of the literature. Acta Neurochir (Wien) 2004;146:411-4.

5. Lee GY, Daniel RT, Brophy BP, Reilly PL. Surgical treatment of nocardial brain abscesses. *Neurosurgery* 2002;51:668-71.
6. Mamelak AN, Obana WG, Flaherty JF, Rosenblum ML. Nocardial brain abscess: Treatment strategies and factors influencing outcome. *Neurosurgery* 1994;35:622-31.
7. Malincarne L, Marroni M, Farina C, Camanni G, Valente M, Belfiori B, *et al.* Primary brain abscess with *Nocardia farcinica* in an immunocompetent patient. *Clin Neurol Neurosurg* 2002;104:132-5.
8. Djennane S, Zecknini K, Billy C, Kamga I, Perronne V, Granier F. *Nocardia farcinica* brain abscess associated with a pulmonary embolism in an immunocompetent patient. *Presse Med* 2005;34:522-4.
9. Kandasamy J, Iqbal HJ, Cooke RP, Eldridge PR. Primary *Nocardia farcinica* brain abscess with secondary meningitis and ventriculitis in an immunocompetent patient, successfully treated with moxifloxacin. *Acta Neurochir (Wien)* 2008;150:505-6.
10. Iannotti CA, Hall GS, Procop GW, Tuohy MJ, Staugaitis SM, Weil RJ. Solitary *Nocardia farcinica* brain abscess in an immunocompetent adult mimicking metastatic brain tumor: Rapid diagnosis by pyrosequencing and successful treatment. *Surg Neurol* 2009;72:74-9.
11. Izawa D, Sakano K, Okumura H, Kuwata T, Tsuji N. Two cases of *Nocardia farcinica* brain abscess. *No Shinkei Geka* 2011;39:1167-72.
12. Vialle R, Aghakhani N, Otayza F, Monteanu V, Safi H, Tadie M. *Nocardia farcinica* brain abscess: Clinical and specific radiological findings and management. Report of two cases in immunocompromised patients. *Neurochirurgie* 2002;48:516-21.
13. Tourret J, Yeni P. Progress in the management of pyogenic cerebral abscesses in non-immunocompromised patients. *Ann Med Interne (Paris)* 2003;154:515-21.
14. Kiska DL, Hicks K, Pettit DJ. Identification of medically relevant *Nocardia* species with an abbreviated battery of tests. *J Clin Microbiol* 2002;40:1346-51.
15. Jodlowski TZ, Melnychuk I, Conry J. Linezolid for the treatment of *Nocardia* spp. infections. *Ann Pharmacother* 2007;41:1694-9.
16. Ntziora F, Falagas ME. Linezolid for the treatment of patients with central nervous system infection. *Ann Pharmacother* 2007;41:296-308.
17. Marnet D, Brasme L, Peruzzi P, Bazin A, Diallo R, Servettaz A, *et al.* *Nocardia* brain abscess: Features, therapeutic strategies and outcome. *Rev Neurol* 2009;165:52-62.

**How to cite this article:** Pascual-Gallego M, Alonso-Lera P, Arribi A, Barcia JA, Marco J. *Nocardia farcinica* abscess of the cerebellum in an immunocompetent patient: A case report and review of the literature. *Asian J Neurosurg* 2016;11:454-5.

**Source of Support:** Nil, **Conflict of Interest:** None declared.