

## CASE REPORT

# Baastrup's disease in the pediatric spine

Suryapratap Singh

Department of Neurosurgery, NMCH, Nellore, Andhra Pradesh, India

## ABSTRACT

Baastrup's disease is an uncommon entity in the elderly spine and it is very rare in the pediatric age group. There are only few case reports in the literature containing Baastrup's disease in pediatric spine. Baastrup's disease is also known as kissing spine because the posterior spinous processes touch or "kiss" one another, characterized by enlarged posterior spinous projections with normal neuroforamina and normal spinal disk height. There are various pathological and etiological hypotheses behind Baastrup's disease. Backache is one of the most common causes of morbidity in these patients and but sometimes patient can be asymptomatic with or without swelling on the back. Here, we present a case of 10-year-old female child with silent swelling on low back region diagnose as Baastrup's disease.

**Key words:** Baastrup's disease, kissing spine, pediatric

## Introduction

Back pain and spine problems are very common in elderly age. Baastrup's disease is one of the rare causes of low back pain in elderly and it is extremely rare in the pediatric age. It can be asymptomatic or can manifests as localized lumbar tenderness and pain on spinal extension that can be relieved by spinal flexion.<sup>[1,2]</sup> Detail clinical examination and complete radiological evaluation require for diagnosis of kissing spine. Both conservative and surgical options are available for treatment as per the symptoms and complications of the disease.

## Case Report

A 10-year-old female child presented with swelling on low back since 1 year. There were no complaints of back pain, radiating pain to leg or lower limb weakness.

On examination, she had hard swelling on low back at upper lumbar region. There was no tenderness over the spine or sacroiliac joints. Straight leg raising test was negative. No neurological deficits could be elicited. Hip joints were normal.

All blood investigations were normal and C-reactive protein was negative.

Plain roentgenogram of the lumbosacral spine showed enlarged and fusion of spinous processes of L1-L2 lumbar vertebrae, which were seen opposing each other [Figure 1]. Vertebral bodies and disc spaces appeared normal. There was no spondylolysis or spondylolisthesis. Magnetic resonance imaging (MRI) lumbosacral spine showed same lesion with normal spinal canal dimensions, normal facet joints and no disc prolapse [Figure 2].

Considering these findings, a radiological diagnosis of Baastrup's disease was made. Patient was asymptomatic and there were no neurological deficits so patient discharged with advice of close follow-up.

## Discussion

Baastrup's disease is an uncommon condition found in the elderly and extremely rare in children. This disease is named after Danish radiologist (1855-1950) Christian Ingerslev Baastrup.<sup>[1]</sup>

Baastrup's disease also known as Baastrup's sign, Baastrup's syndrome, kissing spine and Machete's syndrome has been implicated as a cause for low back pain.<sup>[1,3]</sup>

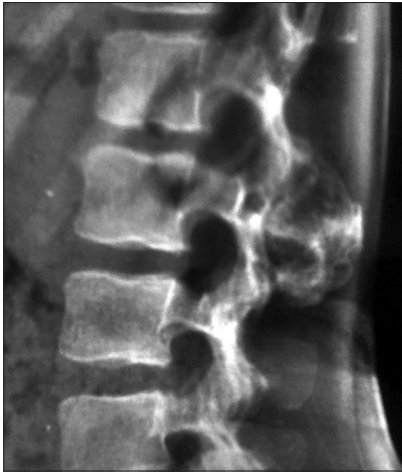Brailsford described arthritic joints between the spinous processes on radiological evaluation and noted that "such patients have pain in the back when standing erect, which is relieved by bending forward."<sup>[4]</sup> Christian Baastrup described the clinical and radiological features of the syndrome.<sup>[1]</sup>

In the kissing spine, the enlarged posterior spinous processes touch, or "kiss" one another with normal neuroforamina and spinal disk height. Among of much debate now it is

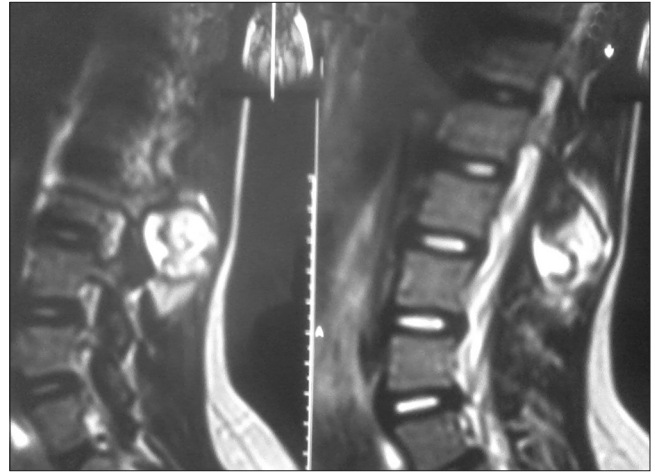
Access this article online	
Quick Response Code:	Website: www.asianjns.org
	DOI: 10.4103/1793-5482.145153

### Address for correspondence:

Dr. Suryapratap Singh, Registrar, Chinthareddypalam,  
Nellore - 524 002, Andhra Pradesh, India.  
E-mail: dr.suryapratap\_singh\_tomar@yahoo.com



**Figure 1:** Plain roentgenogram shows approximation and adhesion of the spinous processes of L1-L2 vertebrae



**Figure 2:** Magnetic resonance imaging shows fusion of spinous processes of L1-L2 vertebrae

considered mostly a case of aging related problem,<sup>[5]</sup> but our case is 10-year-old female child, which is extremely unusual. It is reported in mostly lumbar spine, but its cervical spine variant is also reported.<sup>[6,7]</sup>

Baastrup's disease is characterized by degenerative phenomena secondary to friction between adjacent spinous processes, with sclerosis of the margins and decrease in the interspinous space. In many occupational areas such as miners and heavy vehicle drivers or activities like dance or gymnastics can make Baastrup's disease more likely to appear at younger or pediatric age. This disease can manifest in children by different way with increased interspinous spaces and bone remodeling.<sup>[8,9]</sup>

According to Maes *et al.* the prevalence of Baastrup disease is 8.2% (44 of 539) of the study population.<sup>[10]</sup> According to Kwong *et al.* Baastrup disease occurs with high frequency among the elderly and was most common at L4-L5 segment.<sup>[11]</sup> According to Hanger prevalence rate of this disease in a group of heavy automotive vehicles drivers is 13% of the test population was most common at L3-L4 and L4-L5 segments.<sup>[12]</sup>

Overgrowth and calcifications of osteophytes at posterior lumbar spinous processes are caused by trauma and stress; although, some have claimed that this degenerative disease may be indicative of strenuous activities.<sup>[13]</sup>

Some cases of Baastrup's sign may asymptomatic; like our case. Pain may be due to the irritation of the periosteum or adventitial bursa between abutting spinous processes and some cases can compliant of radiating pain in leg due to the spinal canal stenosis.<sup>[12]</sup>

During the clinical examination, careful inspection and palpation is always useful. Palpation gives the feeling of crowding of (kissing) spinous process as compared with other interspinous spaces and sometime inflamed bursa with cyst may impart a "bouggy" feeling to the palpating hand.<sup>[14]</sup>

Baastrup's disease can identified on radiological evaluation by approximation and adhesion of the spinous processes and there enlargement.<sup>[14,15]</sup> Plain roentgenogram and computer tomography shows approximation and adhesion of the spinous processes and there enlargement with sometimes sclerosis and flattening of spinal processes. MRI can demonstrates involvement of spinal cord with lesion, interspinous bursal fluid and ventral extension of swelling.<sup>[14,16,17]</sup>

Some cases of Baastrup's sign are asymptomatic; if it does cause pain then patient requires appropriate treatment.<sup>[5]</sup> If patient is symptomatic, various treatment modalities are available. Both conservative and surgical options are available for treatment. Local steroid injection into the interspinous processes and nerve block can reduce the pain for a short period of time.<sup>[14]</sup>

Removal of enlarged part of the spinous process and lamina of vertebra called decompressive laminectomy reduces the pressure and pain. After this surgery, patient takes some time for recovery and may need physical therapy for a long time after the operation. Sometimes after laminectomy, patient can develop failed back syndrome and patient may feel severe pain during the routine work. In view of drawbacks of laminectomy, spine surgeons prefer laminectomy only in case of extreme pain and neurological deficit.<sup>[14]</sup>

Physiotherapy is not much effective as per the literature. Some studies show the satisfactory outcome of physiotherapy with electroanalgesia and thermo-analgesia.<sup>[14]</sup>

## **Conclusion**

Baastrup's disease in the pediatric age group without any clinical feature is rarely reported in the literature. This may be because of strenuous activities, trauma and repetitive stress. Baastrup's disease is common in elderly, but very rare in the pediatric age group. Detail clinical examination and complete radiological study can prevent the complication

of this disease. In last, during the evaluation of pediatric spine swelling, this rare pathological entity should be kept in mind.

## References

1. Baastrup CI. On the spinous processes of the lumbar vertebrae and the soft tissues between them, and on pathological changes in that region. *Acta Radiol [Old Series]* 1933;14:52-5.
2. Hazlett J. Kissing spines. *J Bone Joint Surg Br* 1964;46:1368-9.
3. Bywaters, E. G. "Rheumatoid and other diseases of the cervical interspinous bursae, and changes in the spinous processes." *Annals of the rheumatic diseases* 41.4 (1982): 360-370.
4. Brailsford JF. Deformities of the lumbosacral region of the spine. *Br J Surg* 1929;16:562-627.
5. Haig AJ, Harris A, Quint DJ. Baastrup's disease correlating with diffuse lumbar paraspinous atrophy: A case report. *Arch Phys Med Rehabil* 2001;82:250-2.
6. Fernandez De La Mela I. Lumbar interspinous nearthrosis (Baastrup disease) as responsible for some intractable backaches. *Medicamenta (Madr)* 1951;9:404-5.
7. Viallet P. Two cases of cervical localization of Baastrup disease. *J Radiol Electrol Arch Electr Medicales* 1950;31:206-7.
8. Arias Fernández J, Broncano Cabrero J, Bondía Gracia JM, Aquerreta Beola JD. Radiological manifestations of Baastrup's disease in children. *Radiologia*. 2011 Sep 27. [Epub ahead of print].
9. Gajdek D, Golebiowska B. Baastrup syndrome of the lumbar spine in miners. *Chir Narzadow Ruchu Ortop Pol* 1976;41:171-4.
10. Maes R, Morrison WB, Parker L, Schweitzer ME, Carrino JA. Lumbar interspinous bursitis (Baastrup disease) in a symptomatic population: Prevalence on magnetic resonance imaging. *Spine (Phila Pa 1976)* 2008;33:E211-5.
11. Kwong Y, Rao N, Latief K. MDCT findings in Baastrup disease: Disease or normal feature of the aging spine? *AJR Am J Roentgenol* 2011;196:1156-9.
12. Hagner W. Baastrup's disease of the lumbar segment of the spine among drivers of heavy motor vehicles. *Med Pr* 1988;39:65-70.
13. Kacki S, Villotte S, Knüsel C. Baastrup's sign (kissing spines): A neglected condition in paleopathology. *Int J Paleopathol* 2011;1:104-10.
14. Kota G, Kumar NK, Thomas R. Baastrups disease an unusual cause of backpain: A case report. *Internet J Radiol* 2005;4:1.
15. Bywaters EG, Evans S. The lumbar interspinous bursae and Baastrup's syndrome. An autopsy study. *Rheumatol Int* 1982;2:87-96.
16. Gardella G. Spinous process syndrome (Baastrup disease). *Ann Radiol Diagn (Bologna)* 1952;24:260-74.
17. Lin E. Baastrup's disease (kissing spine) demonstrated by FDG PET/CT. *Skeletal Radiol* 2008;37:173-5.

**How to cite this article:** Singh S. Baastrup's disease in the pediatric spine. *Asian J Neurosurg* 2016;11:446-7.

**Source of Support:** Nil, **Conflict of Interest:** None declared.