

## CASE REPORT

# Supratentorial intermediate grade meningeal melanocytoma with intratumoral bleed in the background of neurocutaneous melanosis: Report of an unusual case and review of literature

Kuntal Das, Anup Nair, Sushila Jaiswal<sup>1</sup>, Rabi Sahu, Arun Srivastava, Raj Kumar, Anant Mehrotra

Departments of Neurosurgery and <sup>1</sup>Pathology, Sanjay Gandhi Postgraduate Institute of Medical Sciences, Lucknow, Uttar Pradesh, India

## ABSTRACT

Primary melanocytic tumours of the central nervous system (CNS) are rare. According to the WHO classification (2007), these tumours include diffuse leptomeningeal melanosis, melanomatosis, melanocytoma, and primary CNS melanoma. Meningeal melanocytoma, most commonly seen in the infratentorial compartment and cervical spinal cord, is a benign primary melanocytic neoplasm. Primary CNS melanoma, on the other hand, represents the malignant end of the spectrum. Intermediate grade melanocytoma is a rare histological subtype of primary meningeal tumours and is characterised by the clinicopathological features between the two extremes. Neurocutaneous melanosis (NCM) is a rare phacomatosis characterised by melanotic lesions on the skin and leptomeninges. Leptomeningeal manifestation in NCM may be observed either in the form of diffuse leptomeningeal melanosis or primary CNS melanoma. Melanocytomas are focal lesions and their association with NCM is extremely rare. In this report, we present an unusual case of NCM accompanied by right frontal intermediate grade melanocytoma with intratumoral bleeding in a 17-year-old boy. A brief literature review is also presented.

**Key words:** Hemorrhage, hydrcephalus, intermediate grade melanocytoma, neurocutaneous melanosis, supratentorial

## Introduction

Primary melanocytic neoplasms of the central nervous system (CNS) are rare. The World Health Organization (WHO) 2007 recognises 4 distinct pathological entities under this heading, i.e., leptomeningeal melanosis, melanomatosis, meningeal melanocytoma, and primary melanoma.<sup>[1]</sup> Meningeal melanocytoma is a rare primary melanocytic neoplasm accounting for 0.06-0.1% of all brain tumours.<sup>[2]</sup> These tumours are commonly encountered in the infratentorial compartment of the cranial cavity and spinal column,<sup>[2,3]</sup> where melanocytes are most abundant, and are generally considered benign.

Good prognosis is usually observed following surgical excision and radiotherapy, although recurrences and conversion to malignant state are not uncommon.<sup>[2,3]</sup> Primary CNS melanoma, on the other hand, is primarily a malignant tumour having extremely poor prognosis inspite of optimal therapy.

Intermediate grade meningeal melanocytoma is a distinct variant of melanotic neoplasm having clinicopathological features between the two extremes.<sup>[4]</sup> These lesions are known to be more aggressive than the purely benign forms.

Meningeal melanocytoma is a focal lesion and has not been described in the setting of neurocutaneous melanosis (NCM), a rare phacomatosis characterised by excessive melanocytic proliferation of the skin and the leptomeninges, although melanocytoma has been reported to co-exist with the nevus of Ota.<sup>[5,6]</sup>

This is an open access article distributed under the terms of the Creative Commons Attribution-NonCommercial-ShareAlike 3.0 License, which allows others to remix, tweak, and build upon the work non-commercially, as long as the author is credited and the new creations are licensed under the identical terms.

**For reprints contact:** reprints@medknow.com

**How to cite this article:** Das K, Nair A, Jaiswal S, Sahu R, Srivastava A, Kumar R, *et al.* Supratentorial intermediate grade meningeal melanocytoma with intratumoral bleed in the background of neurocutaneous melanosis: Report of an unusual case and review of literature. Asian J Neurosurg 2017;12:98-102.

Access this article online	
Quick Response Code:	Website: www.asianjns.org
	DOI: 10.4103/1793-5482.145113

### Address for correspondence:

Dr. Raj Kumar, Sanjay Gandhi Post Graduate Institute of Medical Sciences, Rae Bareilly Road, Lucknow - 602 214, Uttar Pradesh, India. E-mail: rajkumar1959@gmail.com

Here we report a case of a 17-year-old boy with right frontal intermediate grade melanocytoma with intratumoral bleeding in the setting of NCM and present a brief literature review.

## Case Report

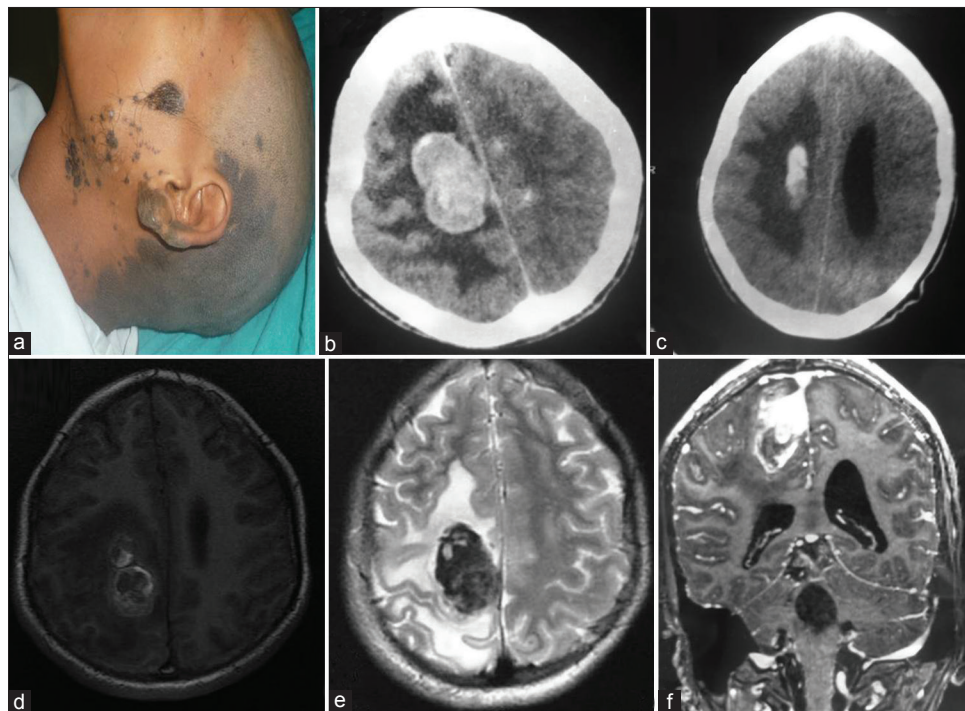
### History and examination

A 17-year-old boy presented with recurrent left sided partial seizures since 8 months with a history of sudden onset of headache and vomiting followed by altered sensorium 4 days prior to admission. He also had a large dark pigmented patch on his left arm including the elbow and shoulder area extending to the head and neck region since early childhood without any recent history of ulceration, bleeding, or itching. On examination, the boy was conscious but irritable. He obeyed commands and had left hemiplegia. He also had a large (>40 cm in the largest dimension) melanotic patch over the left arm including the elbow and shoulder, the left side of the neck, and the left temporoparietal area without any ulceration, nodularity, or bleeding. There were a few small hairy nevi situated in the region of the left angle of the mandible [Figure 1a]. CT showed well-defined hyper density suggestive of bleeding in the right posteromedial frontal lobe with grade 2 perilesional edema. Effacement of the ipsilateral lateral ventricle was observed with mild dilatation of the ventricles [Figure 1b and c]. Hence, a provisional diagnosis of intraparenchymal bleeding was made based on tumour or vascular malformation. Contrast brain MRI with

Magnetic Resonance Angiogram and Magnetoc Resonance Venography was performed keeping these possibilities in mind. Brain MRI showed the lesion to be heterogeneously T1 hyper intense and intensely T2 hypointense with blooming on the SWAN sequence indicating the presence of hemorrhage within the lesion [Figure 1d and e]. The lesion showed minimal peripheral contrast enhancement and marked perilesional edema (Grade II) with a midline shift of approximately 1.3 cm to the left. A dural attachment was also noted to the falx [Figure 1f]. MRA and MRV were normal. The patient was taken up for urgent surgical decompression of the lesion in view of the alarming mass effect and impaired sensorium.

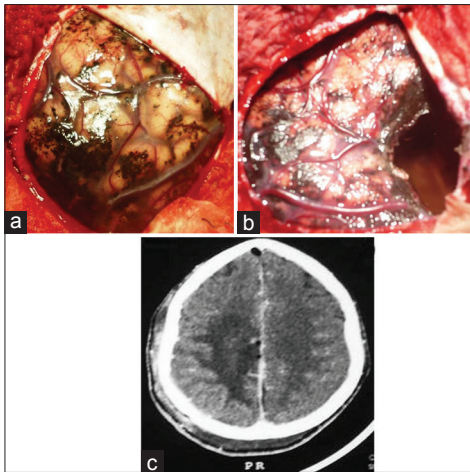
### Intraoperative

Right frontoparietal parasagittal craniotomy of 5 × 5 cm was performed. The dura was seen bulging but appeared normal otherwise. On opening the dura, the brain appeared tense and there was diffuse dark pigmentation of the exposed leptomeninges [Figure 2a]. Surface changes were seen in the posteromedial frontal lobe where a small corticectomy of 1 × 1 cm was made and an ill-defined jet black mass was encountered within 1 cm with blood clots within. The tumour was moderately vascular, partly suckable, and had a poor plane of cleavage from the surrounding brain parenchyma. The mass was medially attached to the falx. The blood clot was evacuated from within the lesion, and gross total tumour decompression was achieved [Figure 2b

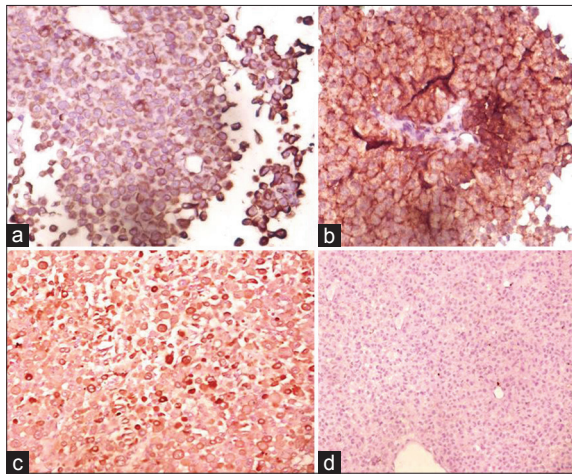


**Figure 1:** (a) Cutaneous melanocytic lesion involving the head and neck. (b) CT scans show evidence of bleeding in the right frontal lobe with marked perilesional edema. (c) Obliteration of ipsilateral lateral ventricle with mild dilatation of the contralateral one. (d) On T1WI, the lesion is heterogeneously hyperintense. (e) On T2WI, lesion appears intensely hypointense. (f) Coronal post contrast film shows peripheral but intense contrast enhancement with broad falcine attachment





**Figure 2:** (a) Diffuse melanosis involving the pia-arachnoid and the brain is seen to be tense, (b) Surgical cavity made after total removal of mass, (c) Postoperative scan shows complete excision of the mass



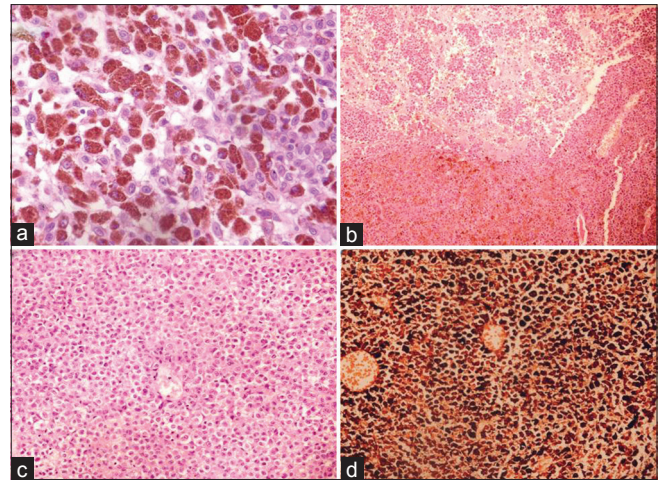
**Figure 4:** On immunohistochemistry tumor cells show positivity for: (a) Vimentin ( $\times 400$ ), (b) HMB-45 ( $\times 400$ ), (c) S-100 ( $\times 400$ ) and (d) Ki67  $< 2\%$  ( $\times 100$ )

and c]. Based on our observation of diffuse leptomeningeal darkish pigmentation, our intraoperative impression was that of metastatic melanoma with bleeding. Hence, we did not conduct additional biopsy from the dark appearing leptomeninges. At the same time, biopsy of the cutaneous lesion was also performed.

## Histopathology

### Cranial lesion

The tumour cells were arranged in sheets with adjacent areas of brain infiltration. The cells were polygonal with round vesicular nuclei containing small eosinophilic nucleoli and moderate cytoplasm containing melanin pigment. Mitotic figures were occasional with no necrosis [Figure 3a-d]. Immunohistochemistry (IHC) was positive for HMB-45, vimentin, and S-100 with no epithelial membrane antigen; Ki-67 index was 1-2% [Figure 4a-d]. The histopathological diagnosis was intermediate grade melanocytoma.



**Figure 3:** (a) Tumor composed of tumor cells arranged in sheets displaying polygonal cells having round vesicular nuclei, small eosinophilic nucleoli, and moderate amount of cytoplasm containing abundant melanin pigment. Mitotic figures are occasional (H and E  $\times 400$ ), (b) Tumor and adjoining brain showing tumor cells infiltration into the adjacent brain parenchyma (H and E  $\times 100$ ), (c) Melanin pigment got bleached with potassium permanganate (Bleach  $\times 200$ ), (d) Black pigmentation shown by Masson Fontana (Masson Fontana  $\times 200$ )

## Skin

The skin showed unremarkable keratinized epidermis. The superficial dermis showed a thick band of relatively monomorphic melanocytes. Mitosis was inconspicuous with no evidence of necrosis or infiltration in the underlying subcutaneous tissue, which is suggestive of intradermal naevus.

## Postoperative course

Postoperatively, the patient showed improvement in sensorium. There were no fresh deficits. The patient was referred to radiotherapy for further treatment. He was found to do well at the 6-month follow up.

## Discussion

Primary melanocytic tumours of the central nervous system (CNS), arising from the leptomeningeal melanocytes, are relatively rare. According to the WHO classification (2007), 4 varieties of these tumours exist. These include diffuse leptomeningeal melanosis, meningeal melanomatosis, meningeal melanocytoma, and primary CNS melanocytoma.<sup>[1]</sup>

First described in 1972 by Limas and Tio,<sup>[7]</sup> the meningeal melanocytomas account for 0.06-0.1% of all primary brain neoplasms.<sup>[2]</sup> These tumours arise from the leptomeningeal melanocytes, which are derived from the neural crest cells during embryonic life. Their annual incidence is estimated to be around 1/10 million people. These tumours are common in adults with a slight female preponderance.<sup>[8]</sup> Meningeal melanocytomas are usually solitary extra axial lesions, but Yosef Ali *et al.* have reported a 31-year-old man with multifocal melanocytomas involving the bilateral cerebello pontine (CP) angle and thoracic spinal cord.<sup>[9]</sup> Multifocal lesions have also

been described by Beseoglu K *et al.*<sup>[3]</sup> In a literature review, Hamasaki *et al.*<sup>[8]</sup> found the mean age at diagnosis of these patients to be 53 years (range: 27-69 years) with each sex being equally affected. Our patient presented at 17 years of age, which is relatively early compared with previous literature.

As far as the site predilection is concerned, melanocytomas are almost exclusively described in the posterior fossa and spinal cord.<sup>[2,3]</sup> This observation is primarily because of the abundance of the leptomeningeal melanocytes in the region of the ventrolateral brain stem and cervical spinal cord. The lesion, in our patient, was located in the right frontal parafalcine location having a broad based attachment with the falx cerebri. These lesions are rare in the supratentorial compartment and, to the best of our knowledge, only 26 cases of supratentorial meningeal melanocytomas has been reported till date.<sup>[3,6]</sup>

These patients usually present with non-specific compressive symptoms, classical of extra axial lesions, such as seizure, CP angle syndrome, and compressive cervical myelopathy, but acute presentation because of bleeding within the tumour, an usual feature of malignant melanoma, is extremely rare in meningeal melanocytomas especially when one considers the low grade nature of such lesions. Hino K *et al.*<sup>[5]</sup> also reported a case of meningeal melanocytoma with bleeding. Spontaneous intratumoral bleeding in our patient was explained by the intermediate grade histology of the tumour, which behaves more aggressively than benign melanocytomas. An impending malignant transformation could also explain the same.

CT scans showed these lesions to be hyper dense extra axial masses with an irregular outline, which usually enhance homogenously thus mimicking meningiomas.<sup>[10]</sup> On MRI, these lesions are usually T1 hyper and T2 hypointense with intense post contrast enhancement with dural attachment. This MRI finding is thought to be because of the presence of stable free radicals present in the melanin.<sup>[11]</sup> Melanomas, on the other hand, show non homogenous T1 hyperintensity as well as inhomogenous contrast enhancement because of the presence of variable amount of intratumoral bleeding in the tumour. The MR finding in our patient thus simulated the picture seen with melanoma although the lesion was actually melanocytoma. This once again highlights the limitations of MRI in distinguishing melanocytomas from melanomas, especially the intermediate grade tumours, and underscores the need for histopathological confirmation.

Grossly melanocytomas are pigmented, circumscribed, and often encapsulated. The lesions are usually dural based. Microscopically, they are composed of uniform spindle cells arranged in sheets having vasocentric fascicles, pseudopapillary appearance, and tight whorled nests, resembling meningioma. Heavily pigmented cells are seen at the periphery. Exceptionally amelanotic forms may be present. Nuclei show grooving in the spindle cells along with small conspicuous nucleoli.<sup>[2]</sup>

As described by Limas and Tio,<sup>[7]</sup> ultrastructural view demonstrates premelanosomes and mature melanosomes with the absence of desmosomes, interdigitating cytoplasmic processes, and intracytoplasmic fibrils, features that conclusively differentiate melanocytomas from melanotic meningiomas.

Absence of cellular atypia, nuclear pleomorphism, macronucleolus, and necrosis along with a low proliferative index usually serves to differentiate melanocytomas from melanoma.<sup>[2]</sup> The presence of markers HMB-45, S-100, and vimentin along with the absence of epithelial membrane antigen serve to further differentiate MM from melanotic meningioma. Histopathological examination also rules out melanotic schwannoma, which can cause diagnostic dilemma especially if the lesion is situated in the CP angle.<sup>[2]</sup>

The histopathological finding in our patient resembled the intermediate grade melanocytic lesion as described by Brat *et al.*<sup>[4]</sup> He introduced the term intermediate grade melanocytic tumor, which have features in between the low grade melanocytoma and high grade melanoma. These lesions behave aggressively but lack overt cytological atypia, mitotic rate, or anaplasia typical of melanoma. These are relatively hyper cellular showing sheet like growth, lack nesting pattern, low level of mitotic activity (1-3 per high power field), and MIB-1 index ranging from 1 to 4%. Intermediate grade lesions are more aggressive than purely benign melanocytomas and the presence of intratumoral hemorrhage, as seen in our patient, only substantiates this very fact.

In addition to the presence of intermediate grade melanocytoma, our patient had diffuse leptomeningeal melanosis of the surrounding brain region. In presence of a histologically proven giant intradermal naevus (>40 cm), we made a diagnosis of NCM in our patient as per the revised criteria for diagnosing NCM by Kaomagma and Frieden.<sup>[12]</sup> The criteria include:

- Large (>20 cm largest adult diameter) or multiple ( $\geq 3$ ) congenital nevi in association with meningeal melanosis or melanoma, the size criteria being slightly different in infants
- No evidence of cutaneous melanoma except when the examined areas of meningeal lesions are histologically benign
- No evidence of meningeal melanoma except when examined cutaneous lesions are histologically benign.

In addition, the presence of ventriculomegaly in our patient also goes in favour of NCM. Hydrocephalus is known to occur in NCM which is thought to develop because of reduced CSF absorption as a result of infiltration of the arachnoid villi by melanocytes or as a result of obstruction of CSF flow by the thickened leptomeninges.<sup>[13]</sup> Alternatively, hydrocephalus might have resulted from the associated hyperproteinorrhachia, which may lead to reduced CSF resorption.<sup>[14]</sup>

NCM is characterized by diffuse leptomeningeal melanosis which can have malignant conversion as well (meningeal



melanomatosis). Focal lesions like melanocytoma and primary focal melanomas are not part of this neurocutaneous syndrome. To our knowledge melanocytoma have not been reported earlier in the setting of NCM although there are reports where meningeal melanocytoma has been noted to co-exist with nevus of Ota.<sup>[5,6,11]</sup>

The implication of the co-existence of NCM in our patient is that the overall prognosis will remain poor as there is a body of evidence stating the limited survival in patients with NCM having symptomatic CNS lesions.<sup>[5,12]</sup> Various reasons for the stated poor prognosis include development of progressive cranial neuropathy (as the luxuriant leptomeningeal melanocytic growth is maximum at the cranial base), insidious development of hydrocephalus, and development of malignancies in the melanotic areas of the leptomeninges. These secondary melanotic malignancies tend to be plaque like in contrast to primary melanomas which tend to be focal.

Complete resection is the best treatment for meningeal melanocytomas. This prevents progressive neurologic sequelae and possible malignant degeneration. Complete excision ensures cure/prolonged remission in most cases.<sup>[2]</sup> However, recurrences do occur, the exact estimate is difficult to ascertain because of relative rarity of the condition. In a literature review, O Hamasaki *et al.* noted 5 recurrences among 14 (35%) patients reviewed,<sup>[8]</sup> 3 out of the 5 occurring after complete excision. Rhades *et al.*<sup>[15]</sup> reported 22% recurrence after 5 years of complete resection. Interestingly, recurrences have been reported after seemingly complete resection, often years after the surgery.<sup>[2]</sup> Adjuvant radiotherapy may be required in incomplete resections (macroscopic) and in patients wherein there is evidence of brain invasion in histology after seemingly gross total excision like in our case (microscopic). The role of adjuvant radiotherapy after complete excision, however, remains unclear. Rhades *et al.*<sup>[16]</sup> studied the therapeutic options for melanocytomas and concluded that complete and incomplete resection followed by radiotherapy ensured better disease free survival than incomplete resections alone. He also observed that radio therapeutic regimens with high total doses of up to 45-55 Gy were significantly superior to doses of <45 Gy as far as the local control was concerned.

Reasonable control, after incomplete excision, has also been reported with gamma knife surgery<sup>[17]</sup> but these are early results, which need further confirmatory studies. Chemotherapy has also been found to be largely ineffective. Apart from recurrences, progression to malignant melanoma has also been described thus warranting very close follow up of these patients.<sup>[18,19]</sup>

## Conclusion

Supratentorial intermediate grade meningeal melanocytoma with intratumoral hemorrhage in the setting of NCM is very rare and probably has not been reported earlier. This case highlights the importance of meticulous histopathological examination including proliferation index estimation not only

for diagnosis but also to prognosticate such cases. Complete excision, whenever possible, should be the aim of surgery and radiotherapy should be used in macro/microscopic incomplete excision. Stringent follow-up is of paramount importance for timely diagnosis and treatment of recurrences as well as malignant degenerations.

## Financial support and sponsorship

Nil.

## Conflicts of interest

There are no conflicts of interest.

## References

1. Prat DJ, Berr A. Melanocytic lesions. In: Louis DN, Ohgaki H, Wiestler OD, Cavenee WK, editors. World Health Organization Classification of Tumours of the Central Nervous System, Lyon: IARC Press, 2007;4:181-3.
2. Jaiswal S, Jaiswal AK, Vij M, Behari S, Pandey R. Primary meningeal melanocytoma of cerebellopontine angle: A case report with 12 years follow up. *Basic and Applied Pathology* 2011;4:1-4.
3. Beseoglu K, Knobbe CB, Reifemberger G, Steiger HJ, Stummer W. Supratentorial meningeal melanocytoma mimicking a convexity meningioma. *Acta Neurochir (Wien)* 2006;148:485-90.
4. Brat DJ, Giannini C, Scheithauer BW, Burger PC. Primary melanocytic neoplasms of the central nervous systems. *Am J Surg Pathol* 1999;23:745-54.
5. Hino K, Nagane M, Fujioka Y, Shiokawa Y. Meningeal melanocytoma associated with ipsilateral nevus of Ota presenting as intracerebral hemorrhage: Case report. *Neurosurgery* 2005;56:E1376.
6. Rahimi-Movaghar V, Karimi M. Meningeal melanocytoma of the brain and oculodermal melanocytosis (nevus of Ota): Case report and literature review. *Surg Neurol* 2003;59:200-10.
7. Limas C, Tio FO. Meningeal melanocytoma ("melanotic meningioma"). Its melanocytic origin as revealed by electron microscopy. *Cancer* 1972;30:1286-94.
8. Hamasaki O, Nakahara T, Sakamoto S, Kutsuna M, Sakoda K. Intracranial meningeal melanocytoma. *Neurol Med Chir (Tokyo)* 2002;42:504-9.
9. Ali Y, Rahme R, Moussa R, Abadjian G, Menassa-Moussa L, Samaha E. Multifocal meningeal melanocytoma: A new pathological entity or the result of leptomeningeal seeding? *J Neurosurg* 2009;111:488-91.
10. Chen CJ, Hsu YI, Ho YS, Hsu YH, Wang LJ, Wong YC. Intracranial meningeal melanocytoma: CT and MRI. *Neuroradiology* 1997;39:811-4.
11. Uematsu Y, Yukawa S, Yokote H, Itakura T, Hayashi S, Komai N. Meningeal melanocytoma: Magnetic resonance imaging characteristics and pathological features: Case report. *J Neurosurg* 1992;76:705-9.
12. Kadonaga JN, Frieden IJ. Neurocutaneous melanosis: Definition and review of the literature. *J Am Acad Dermatol* 1991;24:747-55.
13. Acosta FL Jr, Binder DK, Barkovich AJ, Frieden IJ, Gupta N. Neurocutaneous melanosis presenting with hydrocephalus: Case report and review of the literature. *J Neurosurg* 2005;102:96-100.
14. Bloch J, Vernet O, Aubé M, Villemure JG. Non-obstructive hydrocephalus associated with intracranial schwannomas: Hyperproteinorrhachia as an etiopathological factor? *Acta Neurochir (Wien)* 2003;145:73-8.
15. Rades D, Heidenreich F, Tatagiba M, Brandis A, Karstens JH. Therapeutic options for meningeal melanocytoma: Case report. *J Neurosurg* 2001;95:225-31.
16. Rades D, Schild SE. Dose-response relationship for fractionated irradiation in the treatment of spinal meningeal melanocytomas: A review of the literature. *J Neurooncol* 2006;77:311-4.
17. Kurita H, Segawa H, Shin M, Ueki K, Ichi S, Sasaki T, *et al.* Radiosurgery of meningeal melanocytoma. *J Neurooncol* 2000;46:57-61.
18. Roser F, Nakamura M, Brandis A, Hans V, Vorkapic P, Samii M. Transition from meningeal melanocytoma to primary cerebral melanoma: Case report. *J Neurosurg* 2004;101:528-31.
19. Uozumi Y, Kawano T, Kawaguchi T, Kaneko Y, Ooasa T, Ogasawara S, *et al.* Malignant transformation of meningeal melanocytoma: A case report. *Brain Tumor Pathol* 2003;20:21-5.