

CASE REPORT

Primary non-Hodgkin's lymphoma of the skull with extra and intracranial extension presenting with bulky scalp mass lesion

Manish Jaiswal, Ashok Gandhi, Devendra Purohit, Shashi Singhvi, Radhey Shyam Mittal

Department of Neurosurgery, SMS Medical College and Hospital, JLN Marg, Jaipur, Rajasthan, India

ABSTRACT

Primary non-Hodgkin's lymphoma (NHL) of the cranium with extra- and intracranial extension without systemic or skeletal manifestation in a non-immunocompromised patient is extremely rare. These lesions are most of the time misdiagnosed because they mimic other conditions like meningioma. Here, we report a case presented with huge bulky scalp mass which on magnetic resonance imaging (MRI) brain showed involvement of scalp, cranial vault, meninges, and the brain parenchyma, mimicking a meningioma. After gross total resection, biopsy and CD marker study revealed primary non-Hodgkin's diffuse large B-cell lymphoma (DLBCL). Malignant NHL should be considered in differential diagnosis of bulky scalp mass lesion.

Key words: Meningioma, non-Hodgkin's lymphoma, scalp mass

Introduction

Primary extra-lymph node lymphomas are not uncommon, but they often cause difficulty in diagnosis. Primary lymphoma arising from the cranial vault can mimic clinically and radiologically a meningioma.^[1,2] We present a case of lymphoma arising from the cranial vault mimicking as a meningioma and also review the literature.

Case Report

A 40-year-old lady presented with progressively increasing unsightly bulky huge scalp mass over bilateral frontoparietal region of 1 year duration. She had occasionally mild headache and no other signs and symptoms. There was no history of trauma, fever, or any other illness in the past. On examination, she was conscious and without any neurological deficit. There was slight tender huge bulky mass over bilateral frontoparietal region, with a firm, ill-defined, and bosselated surface. There was no local rise of temperature, and skin over it was healthy

except left forehead region where there was superficially excoriation [Figure 1]. Her blood investigations were normal. Investigations for HIV infection were negative. X-ray chest, ultrasonography of the abdomen, and peripheral smear were normal. Magnetic resonance imaging (MRI) brain showed large permeative enhancing destructive lesion of bilateral frontoparietal bone with large overlying scalp and intracranial extradural and intradural components infiltrating superior sagittal sinus causing mass effect over and edema of underlying brain parenchyma, resulting in effaced cortical sulci and lateral ventricle with midline shift toward the left side [Figure 2]. Computed tomography (CT) angiography brain was done to know vascularity of the mass, which revealed a large lobulated extra-axial mass lesion along bilateral frontal lobes with erosion and destruction of overlying calvarium and large extra-calvarial soft-tissue component with possible differential diagnosis of malignant nonmeningothelial tumor/atypical meningioma [Figure 3]. MR venogram showed no flow in the anterior part of superior sagittal sinus suggestive of infiltration of mass [Figure 3d]. She underwent bifrontal craniotomy and total excision of the lesion including the involved bone, meninges, as well as infiltrated brain parenchyma. Tumor was moderately vascular, fleshy in consistency, and infiltrating the scalp, bone, and brain parenchyma [Figure 4]. Postoperative period was uneventful and CT head was performed [Figure 5]. Histopathology revealed a diffuse, large B-cell type of non-Hodgkin's lymphoma (NHL). CD marker study of the tumor was CD45 [leukocyte common antigen (LCA)] strong positive which had almost pure population of CD20-positive B cells. Pan-cytokeratin (pan-CK) was negative in the tumor cells. CD3 was positive in a small population of lymphocytes, and tumor

Access this article online

Quick Response Code:



Website:

www.asianjns.org

DOI:

10.4103/1793-5482.145093

Address for correspondence:

Dr. Manish Jaiswal, A 33/48 A 2, Omkareshwar, Varanasi, Uttar Pradesh, India. E-mail: manishmlnmc@gmail.com

cells were negative. Ki-67/MIB index was approximately 70%-80%. Morphology was of NHL B-cell type [Figure 6 a,b,c,d].

Discussion

NHL represents only 3%-4% of all neoplasms in the general population and it occurs more frequently in patients with AIDS. Direct involvement of the CNS occurs only in 1%-2% of patients with lymphoma.^[2-5] These lesions are commonly reported in the seventh and eighth decades.^[2,6-9] Our patient was HIV negative and presented at young age in comparison to the literature. The clinical symptoms and signs of lymphoma in the skull include a painless scalp mass, headache due to bone destruction or infiltration of meninges with tumor, seizures and focal neurological deficits resulting from the cortical

infiltration.^[6,8,10] In our case, painless subcutaneous scalp mass was not associated with any neurological deficit.^[9] The disease can involve the pericranium, underlying meninges, and subcutaneous tissue. Pathologically, the spread of the disease to the meninges suggests that the lymphoma cells grow through the diploic spaces along the emissary veins and nerves that pass through the dura to the leptomeninges. Because of the characteristic permeating growth pattern of lymphoma, there was large soft-tissue component along with bone destruction in our case.^[6,8,10] CT scan head generally shows extra-intracranial extent, bone and dura mater invasion.^[7] On plain CT scan and MRI, these lesions are isodense and isointense in nature, respectively, which enhance after contrast administration.^[2,9,11] MRI is helpful in showing diffuse primary cutaneous lymphoma of the cranial vault with orbital and brain invasion, and can thus aid in the decision making regarding different treatment strategies by revealing the invasion of tumor.^[2,11] The angiographic findings of these lesions include mild vascularity in the periphery of the tumor and displacement of neural and vascular structures unlike meningiomas.^[2] When there is diffuse vault, meningeal and parenchymal infiltration, an intraoperative frozen section is recommended since the identification of a lymphoma is likely to influence the decision about the extent of the surgical excision.^[2,6] These lesions are effectively treatable by surgery and radiotherapy, with a good outcome in most of the cases.^[10,12,13] This can be followed by systemic chemotherapy with cyclophosphamide, vincristine, and prednisolone (CVP).^[7] Present case was managed by wide excision of tumor and

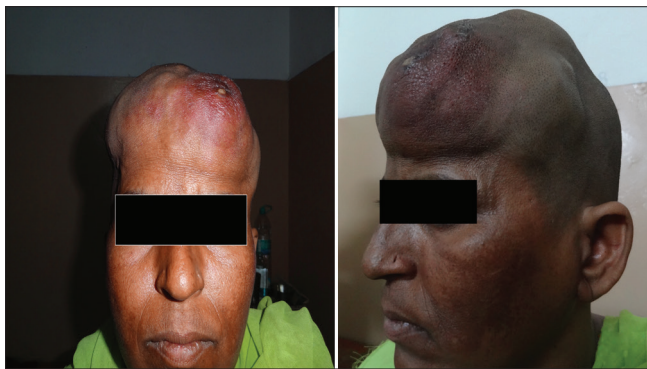

Figure 1: Bulky lobulated scalp mass over bilateral frontoparietal region of scalp with excoriation over left frontal area due to stretched scalp

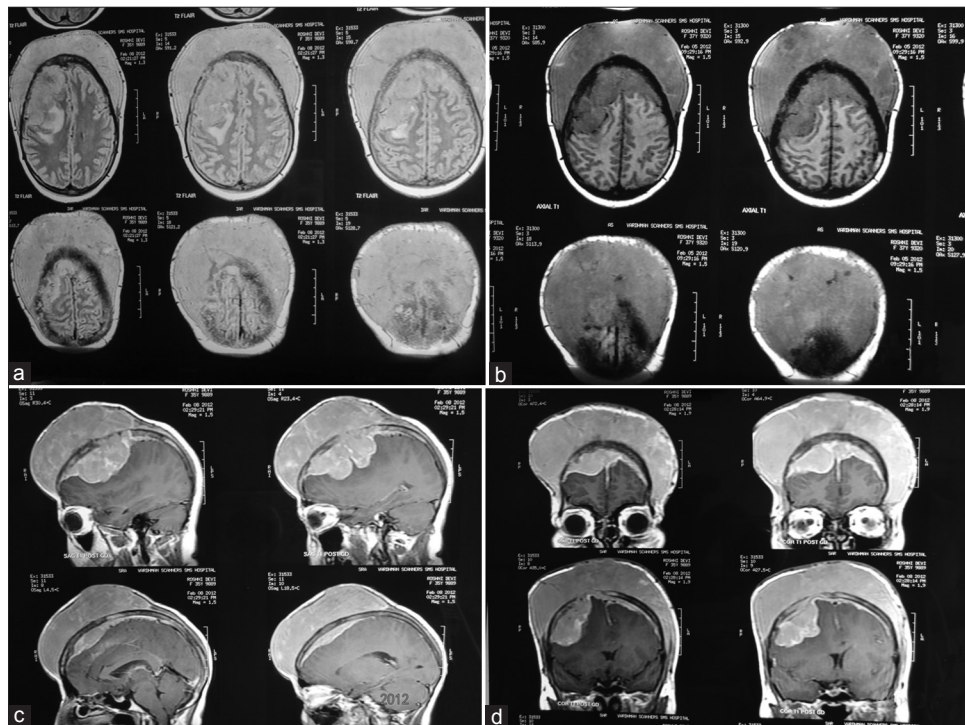


Figure 2: Magnetic resonance imaging brain showing isointense intra- and extracranial mass. (a) T2 FLAIR; (b) Axial T1, which enhances; (c) Sagittal post-GD; (d) Coronal post-GD

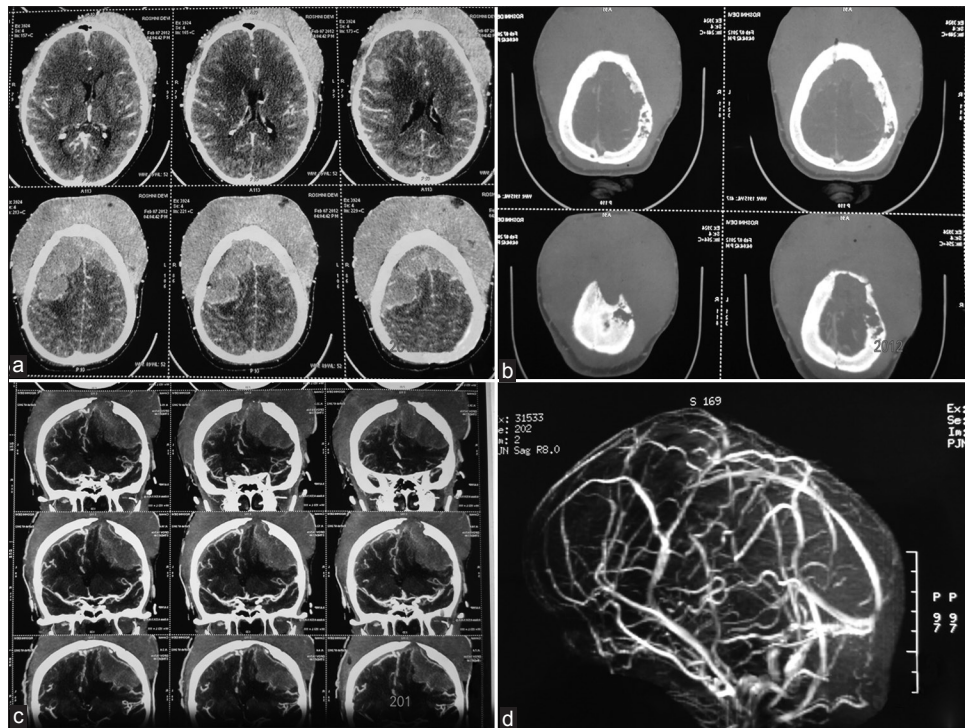


Figure 3: Computed tomography angiography brain (a-c) Large lobulated extra-axial mass lesion along bilateral frontal lobes with erosion and destruction of overlying calvarium and large extra-calvarial soft-tissue component. MR venography; (d) No flow in anterior part of superior sagittal sinus

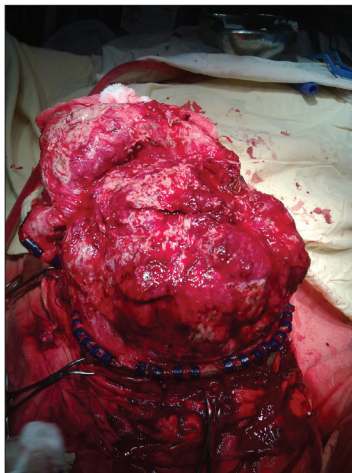


Figure 4: Pre-operative photo showing fleshy tumor with moderate vascularity and infiltration of scalp, bone, and meninges

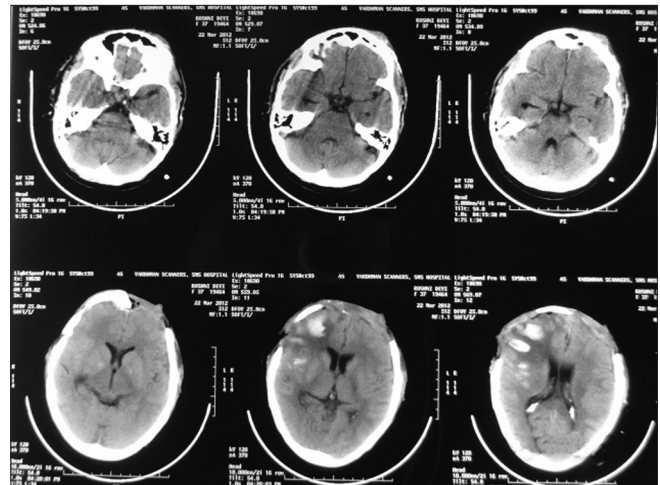


Figure 5: Postoperative computed tomography scan head

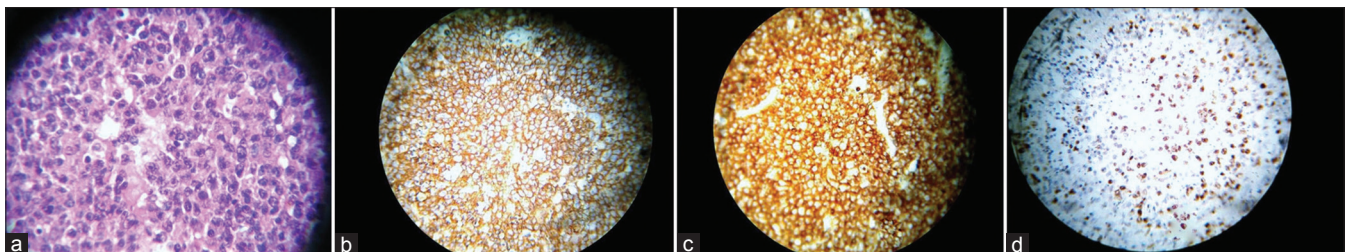


Figure 6: Histopathological and CD marker study: (a) HE x40; (b) CD-20 x40; (c) CD-45 (LCA) x40; (d) Ki-67 x40

involved bone. The prognosis of a lymphoma appearing in the skull vault is uncertain, but any involvement of the cerebral

structures by direct invasion or by leptomenigeal seeding indicates a less favorable prognosis.^[14,15]

Conclusion

Although this condition is rare, NHL diagnosis must be considered in the differential diagnosis in any patient with a scalp mass extending through the skull. Awareness of the characteristic CT and MRI features and aggressive therapy are required for these unusual cases. CD marker study must be performed to confirm the diagnosis as well as for monitoring prognosis.

Declaration of patient consent

The authors certify that they have obtained all appropriate patient consent forms. In the form the patient(s) has/have given his/her/their consent for his/her/their images and other clinical information to be reported in the journal. The patients understand that their names and initials will not be published and due efforts will be made to conceal their identity, but anonymity cannot be guaranteed.

References

1. Agbi CB, Bannister CM, Turnbull IW. Primary cranial vault lymphoma mimicking a meningioma. *Neurochirurgia (Stuttg)* 1983;26:130-2.
2. Aquilina K, O'Brien DF, Phillips JP. Diffuse primary non-Hodgkin's lymphoma of the cranial vault. *Br J Neurosurg* 2004;18:518-23.
3. Baleyrier F, Galambrun C, Manel AM, Guibaud L, Nicolino M, Bertrand Y. Primary lymphoma of the pituitary stalk in an immunocompetent 9-year-old child. *Med Pediatr Oncol* 2001;36:392-5.
4. Braus DF, Schwachheimer K, Muller-Hermelink HK, Schwarzkopf G, Volk B, Munding F. Primary cerebral malignant non-Hodgkin's lymphomas: A retrospective clinical study. *J Neurol* 1992;239:117-24.
5. Braunstein EM, White SJ. Non-Hodgkin's lymphoma of bone. *Radiology* 1980;135:59-63.
6. Curty B, Kernan J, Favre J. Malignant non-Hodgkin's lymphoma of the cranial vault: A case report. *Br J Neurosurg* 1997;11:433-6.
7. Holtas S, Monajati A, Utz R. Computed tomography of malignant lymphoma involving the skull. *J Comput Assist Tomogr* 1985;9:725-7.
8. Jamjoom AB, Jamjoom ZA, Naim-Ur-Rahman, Cheema MA. Primary midline cranial vault lymphoma simulating a parasagittal meningioma: The role of angiography in preoperative diagnosis. *Neurosurg Rev* 1998;21:202-5.
9. Kantarci M, Erdem T, Alper F, Gundogdu C, Okur A, Aktas A. Imaging characteristics of diffuse primary cutaneous B-cell lymphoma of the cranial vault with orbital and brain invasion. *AJNR Am J Neuroradiol* 2003;24:1324-6.
10. Magina S, Mesquita-Guimaraes J, Resende C, Bello M, Dias C. Scalp tumour as a sign of systemic B-cell lymphoma. *J Eur Acad Dermatol Venereol* 2004;18:196-8.
11. Maiuri F, Conero G, Giamundo A. Primary lymphoma of the cranial vault. *J Neurosurg Sci* 1987;31:183-6.
12. Mongia S, Shukla D, Devi BI, Reddy TV. Primary cranial vault non-Hodgkin's lymphoma. *Neurol India* 2003;51:293-4.
13. Parekh HC, Sharma RR, Keogh AJ, Prabhu SS. Primary malignant non-Hodgkin's lymphoma of cranial vault: A case report. *Surg Neurol* 1993;39:286-9.
14. Tanimura A, Adachi Y, Tanda M, Yuasa H, Ishii Y, Katou Y. Primary peripheral B cell lymphoma, Burkitt-like, of the cranial vault. *Acta Haematol* 2005;113:258-61.
15. Wendum D, Sebban C, Gaulard P, Coiffier B, Tilly H, Cazals D, *et al.* Follicular large-cell lymphoma treated with intensive chemotherapy: An analysis of 89 cases included in the LNH87 trial and comparison with the outcome of diffuse large B-cell lymphoma: Grouped Etude des Lymphomes de l'Adulte. *J Clin Oncol* 1997;15:1654-63.

How to cite this article: Jaiswal M, Gandhi A, Purohit D, Singhvi S, Mittal RS. Primary non-Hodgkin's lymphoma of the skull with extra and intracranial extension presenting with bulky scalp mass lesion. *Asian J Neurosurg* 2016;11:444.

Source of Support: Nil, **Conflict of Interest:** None declared.