

# Facial functional outcome in monitored versus not-monitored patients in vestibular schwannomas surgery

Graziano Taddei<sup>1</sup>, Alfonso Marrelli<sup>2</sup>, Donatella Trovarelli<sup>3</sup>, Alessandro Ricci<sup>1</sup>, Renato J. Galzio<sup>1,4</sup>

Departments of <sup>1</sup>Neurosurgery, <sup>2</sup>Neurophysiopathology, <sup>3</sup>Anesthesiology, S. Salvatore Hospital, L'Aquila, <sup>4</sup>University of L'Aquila, Italy

## ABSTRACT

**Objective:** Even though advances in surgical techniques have improved facial nerve outcomes, functional preservation is still an issue because injury to the facial nerve has significant physical and psychological consequences for the patient. We retrospectively review our data in VS surgery to compare the facial outcome in intraoperative facial monitored versus not-monitored patients.

**Materials and Methods:** 51 consecutive patients with unilateral vestibular schwannoma in the period from 2005 to 2010 were treated in our Institution. In according to the type of neurophysiological tool used during surgical procedures, two patients groups were identified: Group 1 (facial stimulator only) and Group 2 (stimulator and facial monitoring). Statistical comparison of the two groups was made with the *t*-test, and facial function results were evaluated with the Fisher's exact test.

**Results:** In the Group 1, of the 22 patients with anatomically preserved facial nerves, 3 (13.6%) showed excellent facial nerve function, 14 (63.6%) showed intermediate function, and 5 (22.7%) showed poor function. In the Group 2, all the 27 patients got anatomically preserved facial nerves, and 18 (66.7%) showed excellent facial nerve function, 9 (33.3%) showed intermediate function, and no one showed poor function.

**Conclusions:** We found that retrosigmoid approach associated with continuous EMG facial monitoring combined with the use of bipolar stimulation is a safe and effective treatment for vestibular schwannomas.

**Key words:** Bipolar stimulator, electromyographic facial nerve monitoring, facial nerve, retrosigmoid approach, vestibular schwannomas

## Introduction

Vestibular schwannoma (VS) is a benign tumor that arises from one or more constituent nerves comprising the eighth cranial nerve complex.<sup>[1-3]</sup> The first objective of its treatment is patient safety, that is, removing the life-threatening risks of an expanding mass in the posterior fossa. The second objective is functional preservation that is, preserving facial function

and, if possible, hearing.<sup>[4]</sup> Even though advances in surgical techniques have improved facial nerve outcomes, functional preservation is still an issue because injury to the facial nerve has significant physical and psychological consequences for the patient.<sup>[5-7]</sup> Intraoperative neurophysiological monitoring plays an important role in modern skull base surgery and in vestibular schwannoma surgery. Facial nerve electromyography (EMG) does not only help to identify the nerve anatomically, but can also preserve the functional integrity and helps to predict the postoperative functional outcome of the nerve.<sup>[8]</sup> In this study, we retrospectively review our data in VS surgery to compare the facial outcome in intraoperative facial monitored versus not-monitored patients.

## Materials and Methods

### Patient population

51 consecutive patients with unilateral vestibular schwannoma were treated in our Institution in the period from 2005 to 2011. The mean age at the time of surgery was 50.1 years (range 26-73 years), with 21 men and 30 women.

### Access this article online

#### Quick Response Code:



#### Website:

www.asianjns.org

#### DOI:

10.4103/1793-5482.144208

### Address for correspondence:

Dr. Graziano Taddei, Department of Neurosurgery, S. Salvatore Hospital, L'Aquila, SS80 67100, Italy.  
E-mail: merut82@gmail.com

The extrameatal diameter of the tumors was >3 cm in 15 of the 51 tumors (large; 29.4%), and <3 cm in 36 (small to medium; 70.6%). Patients with neurofibromatosis type 2 or with a recurrent tumor were excluded from the study.

In according to the type of neurophysiological tool used during surgical procedures, two patients groups were identified: Group 1 (facial stimulator only) and Group 2 (stimulator and facial monitoring) [Table 1].

### Surgical procedure

All operations were done by single neurosurgeon (RJG), using the retrosigmoid suboccipital transmeatal approach in the lateral position. A S-shaped skin incision of 12 cm length was placed 3-4 cm posterior to the mastoid. Irrespective of the tumor size, a retrosigmoid suboccipital craniotomy of 4 cm length and 3 cm width was made to expose the posterior part of the sigmoid sinus and the inferior part of the transverse sinus. The foramen magnum was not usually opened.

The microsurgical removal of the tumors comprised three steps: Cyto-reduction of the large extrameatal cerebello-pontine angle portion of the tumor, the removal of the intrameatal tumor, and the removal of the last lump of tumor remaining in the extrameatal region just outside the porus acusticus. Internal decompression of the large extrameatal tumor was undertaken with an ultrasonic surgical aspirator (Sonopet, Synergetics USA Inc.). The aspirator was so cautiously used as not to rupture the tumor capsule or injure normal structures on the capsule. Dissection of the reduced cerebello-pontine angle tumor from the brainstem in a caudal to rostral direction identified the root entry/exit zone of the facial and acoustic nerves. Resection of the posterior wall of the internal auditory meatus was minimized to prevent related complications, including cerebrospinal fluid (CSF) leak and facial nerve injury.<sup>[9]</sup> The last lump of tumour in the extrameatal region just outside the porus acusticus adhered to the facial nerve most tightly.<sup>[10]</sup> The tumour and facial nerve were dissected bidirectionally. The last piece was resected by sharp dissection in a piecemeal fashion using microscissors and a knife, while

confirming the maintenance of facial nerve function with the stimulator. No bipolar coagulation was applied for hemostasis in this region. After watertight dural closure, the bone flap was secured with microplates. During all the procedures, the facial nerve was identified by intraoperative bipolar stimulator (Athis, Newmedic Systems). In 27 patients (Group 2), EMG responses from mimic muscles were recorded using steel needle electrodes inserted subdermally into the orbicular muscles of the eyes and mouth. In this patients group also trigeminal and brainstem auditory evoked potentials (BAEP) monitoring were used.

### Follow up, outcome measures, and statistical analysis

After tumour removal, all patients were followed up regularly every six months and underwent magnetic resonance imaging (MRI) once a year. In second postoperative day and one year after the tumour removal, facial nerve function and functional outcome were assessed. Facial nerve function was evaluated using House-Brackmann (H-B) grades,<sup>[11]</sup> and was categorized as excellent (H-B grade 1/2), intermediate (H-B grade 3/4), or poor (H-B grade 5/6). Data were retrospectively obtained by reviewing office records, hospitalization records, operative reports, and discharge summaries. Statistical comparison of the two groups was made with the *t*-test, and facial function results were evaluated with the Fisher's exact test.

### Results

Table 1 summarizes the clinical characteristics of two study groups. There were no significant differences in the age, size, and side of tumour. All patients underwent preoperative MRI before and after gadolinium administration. The extrameatal diameter of the tumors ranged from 11.9 to 42.4 mm (mean 24.8 mm). The completeness of tumour removal was judged by surgical records and postoperative MRI. Tumour removal was complete in all patients.

### Facial nerve outcome

The facial nerve was anatomically preserved during the tumour removal in 49 patients (96.1%). Of two patients (both in Group 1) in whom the facial nerve was divided one underwent primary nerve anastomosis using a nerve graft (vestibular not-functional nerve) and one underwent hypoglossal-facial nerve anastomosis. These facial nerve reconstructions resulted in intermediate and poor facial nerve function, respectively. In the Group 1, of the 22 patients with anatomically preserved facial nerves, 3 (13.6%) showed excellent facial nerve function, 14 (63.6%) showed intermediate function, and 5 (22.7%) showed poor function. In the Group 2, all the 27 patients got anatomically preserved facial nerves, and 18 (66.7%) showed excellent facial nerve function, 9 (33.3%) showed intermediate function, and no one showed poor function. The statistical comparison shows a very significant difference in the excellent

**Table 1: Characteristics of the two patients groups in our series**

	Group 1 (not-monitored)						Group 2 (monitored)					
Pts. number	24						27					
Mean age (years)	50, 5 (min 26; max 72)						49, 8 (min 26; max 73)					
Side												
Left	9						24					
Right	15						3					
Mean dimensions (mm)	26.80 (min 11.90; max 42.38)						23.10 (min 14.65; max 32.41)					
H-B grade	I	II	III	IV	V	VI	I	II	III	IV	V	VI
Preoperative (%)	75	12.5	12.5	-	-	-	77.8	22.2	-	-	-	-
Postoperative (%)	-	12.5	12.5	50	12.5	12.5	11.1	55.6	22.2	11.1	-	-

The *t*-test shows not significant differences in the two groups for age ( $P=0.9892$ ), side ( $P=0.9033$ ), and size ( $P=0.8568$ )

and intermediate grade of facial nerve function between the two groups ( $P = 0.0021$ ).

### Postoperative complications and long term follow up

There were no postoperative deaths. One patient developed CSF leak from nose through a very pneumatic mastoid due to the internal meatus opening for surgical tumor removal, which were treated by surgical repair [Figure 1]. The same patient developed a meningococcal meningitis which resolved with antibiotic therapy.

The follow up period after the tumour removal was 6-60 months (mean 33 months). There were no deaths relating to the vestibular schwannoma or tumour recurrence during the follow up period.

### Discussion

The risk of facial nerve palsy after microsurgical removal of VS cannot be entirely eliminated, even with refinements in surgical techniques. In a previous clinical study, Bloch *et al.* found that tumor size is the most important predictor of facial nerve outcome, and that age, extent of resection and surgical approach do not independently predict facial palsy.<sup>[1]</sup> This may be explained by the greater tension of facial nerve due to the tumor growth in patients with large VS.

### Retrosigmoid approach in the lateral position

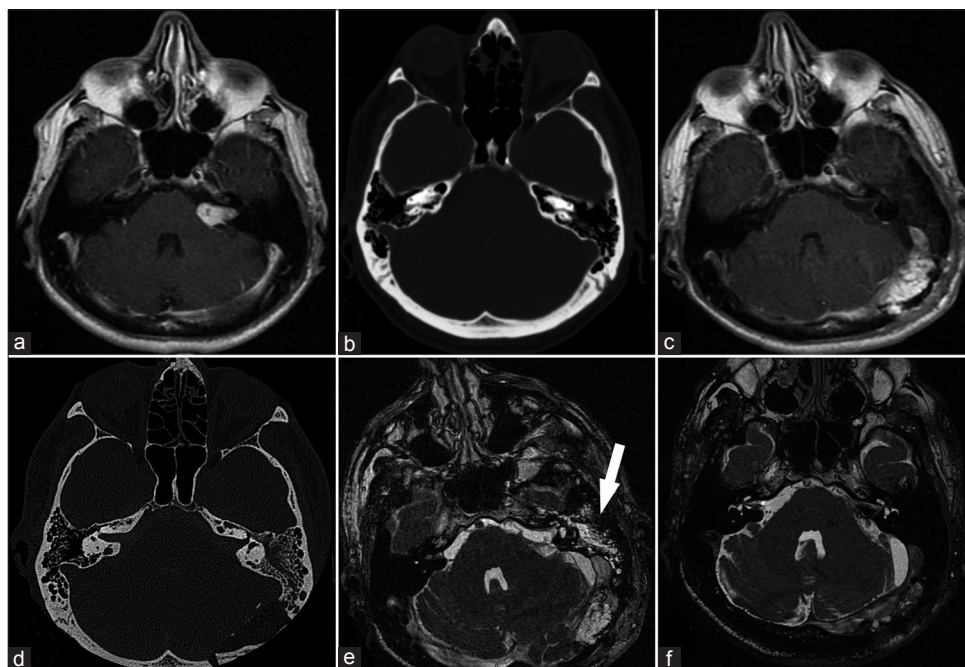
All the operations were performed by small retrosigmoid suboccipital craniotomy, with the patient in the lateral position. Many surgeons prefer the sitting/semisitting position for retrosigmoid removal

because it is more comfortable for the operator.<sup>[10,12-14]</sup> However, the semisitting position risks air embolism irrespective of anaesthetic monitoring to prevent this complication.<sup>[15,16]</sup> In addition, Samii and Matthies. reported a high incidence of haematoma after retrosigmoid removal of cystic tumors in the semisitting position.<sup>[10]</sup> In our series no hematomas developed postoperatively. However, in the semisitting position, the reduced intracranial venous pressure shrinks the peritumoral vein, which prevents troublesome intraoperative bleeding. Thus the vein is likely to be overlooked until a postoperative haematoma develops. In the lateral position, the peritumoral veins cause troublesome intraoperative bleeding, and thus require hemostasis. Finally, it is reported that retrosigmoid approach yields a high rate of facial function preservation<sup>[17]</sup> and we were able to remove 100% of the tumors completely.

### Facial nerve preservation

Various monitoring techniques have been routinely used in the treatment of cranial base lesions.<sup>[18]</sup> EMG is widely used in many neurosurgical centers for identification and monitoring of the facial nerve during operations.<sup>[19-21]</sup>

The facial nerve was anatomically preserved in 96.1% of the patients in our series. The reported anatomical facial nerve preservation rate is 80-90% with the removal of VS by the retrosigmoid approach.<sup>[10,22,23]</sup> Preservation of facial nerve function has been reported to be 70-80% after the removal of VS by the retrosigmoid approach.<sup>[10,22-24]</sup> The definition of a functional facial nerve includes both excellent (H-B grade 1/2) and intermediate (H-B grade 3/4) function. The reported preservation rate of excellent function after the removal of VS is 42-52.6%.<sup>[25,26]</sup>



**Figure 1:** (a) Preoperative magnetic resonance imaging (MRI); (b) preoperative TC showing high pneumatization of mastoids; (c) postoperative MRI; (d) Postoperative TC showing the drilled internal meatus; (e) postoperative MRI showing cerebrospinal fluid (CSF) into the left mastoid (white arrow); (f) MRI after the correction of the fistula

Comparing our own results with and without monitoring of nerve VII (Group 1 vs Group 2), an important functional improvement was achieved with monitoring: Facial nerve functional preservation rate was 77.3% in Group 1 (not-monitored) and 100% in Group 2 (monitored).

The high rate of preserved facial nerve function in our series (45 of the 51 patients; 88.2%) can be attributed to our use of intraoperative monitoring with the facial nerve stimulator-monitor associated to some surgical techniques as described below. In our experience, in fact, the bipolar stimulation of facial nerve during surgery enables the surgeon to localize the nerve at an early stage of the surgical procedure and allows the accurate localization of the unrecognizably distorted nerve. However, functional EMG monitoring is an essential tool when used in a combined step-by-step approach with the bipolar stimulator to achieve the goal of high preservation of functional facial nerve in VS surgery.

Finally, some surgical tricks for preserving facial nerve function must be known. They include the early identification of the root entry/exit zone and do not use the bipolar electrocoagulation when dealing with the tumor in the internal acoustic meatus.

### Postoperative complications

CSF leaks and meningitis are the most common complications after the removal of acoustic neurinomas.<sup>[21]</sup> However, the incidence of CSF leaks was 2% in our series. To prevent CSF leaks it is important to evaluate the pneumatization of the temporal bone using preoperative bone window computed tomography and to perform a watertight dural closure with the absence of an epidural or subcutaneous drain.

There was one case of meningitis in our series, but it is to bring back to the presence of CSF leaks through the nose in the same patient.

### Conclusion

Facial palsy is a debilitating and psychologically devastating condition for the patient. The VS surgery should achieve the goal of remove the lesion with minimal morbidity, that mean facial functional preservation. We found that retrosigmoid approach associated with continuous EMG facial monitoring and with the use of bipolar stimulation is a safe and effective treatment for vestibular schwannomas. As shown above, our step-by-step technique combining the bipolar nerve stimulator and continuous EMG facial monitoring during VS surgery allowed us to achieve a high rate of preserved facial nerve function in our series.

### References

- Bloch O, Sughrue ME, Kaur R, Kane AJ, Rutkowski MJ, Kaur G, et al. Factors associated with preservation of facial nerve function after surgical resection of vestibular schwannoma. *J Neurooncol* 2011;102:281-6.
- Sughrue ME, Yeung AH, Rutkowski MJ, Cheung SW, Parsa AT. Molecular biology of familial and sporadic vestibular schwannomas: Implications for novel therapeutics. *J Neurosurg* 2011;114:359-66.
- Yeung AH, Sughrue ME, Kane AJ, Tihan T, Cheung SW, Parsa AT. Radiobiology of vestibular schwannomas: Mechanisms of radioresistance and potential targets for therapeutic sensitization. *Neurosurg Focus* 2009;27:E2.
- Arriaga MA, Chen DA. Facial function in hearing preservation acoustic neuroma surgery. *Arch Otolaryngol Head Neck Surg* 2001;127:543-6.
- Arriaga MA, Luxford WM, Atkins JS Jr, Kwartler JA. Predicting long-term facial nerve outcome after acoustic neuroma surgery. *Otolaryngol Head Neck Surg* 1993;108:220-4.
- Ferri GG, Modugno GC, Pirodda A, Fioravanti A, Calbucci F, Ceroni AR. Conservative management of vestibular schwannomas: An effective strategy. *Laryngoscope* 2008;118:951-7.
- Marouf R, Noudel R, Roche PH. Facial nerve outcome after microsurgical resection of vestibular schwannoma. *Prog Neurol Surg* 2008;21:103-7.
- Youssef AS, Downes AE. Intraoperative neurophysiological monitoring in vestibular schwannoma surgery: Advances and clinical implications. *Neurosurg Focus* 2009;27:E9.
- Nutik SL, Korol HW. Cerebrospinal fluid leak after acoustic neuroma surgery. *Surg Neurol* 1995;43:553-7; discussion 556-7
- Samii M, Matthies C. Management of 1000 vestibular schwannomas (acoustic neuromas): Surgical management and results with an emphasis on complications and how to avoid them. *Neurosurgery* 1997;40:11-21; discussion 21-3
- House JW, Brackmann DE. Facial nerve grading system. *Otolaryngol Head Neck Surg* 1985;93:146-7.
- Koos WT, Day JD, Matula C, Levy DI. Neurotopographic considerations in the microsurgical treatment of small acoustic neurinomas. *J Neurosurg* 1998;88:506-12.
- Malis LI. Nuances in acoustic neuroma surgery. *Neurosurgery* 2001;49:337-41.
- Tonn JC, Schlake HP, Goldbrunner R, Milewski C, Helms J, Roosen K. Acoustic neuroma surgery as an interdisciplinary approach: A neurosurgical series of 508 patients. *J Neurol Neurosurg Psychiatry* 2000;69:161-6.
- Duke DA, Lynch JJ, Harner SG, Faust RJ, Ebersold MJ. Venous air embolism in sitting and supine patients undergoing vestibular schwannoma resection. *Neurosurgery* 1998;42:1282-6; discussion 1286-7.
- Zentner J, Albrecht T, Hassler W. Prevention of an air embolism by moderate hypoventilation during surgery in the sitting position. *Neurosurgery* 1991;28:705-8.
- Yamakami I, Yoshinori H, Saeki N, Wada M, Oka N. Hearing preservation and intraoperative auditory brainstem response and cochlear nerve compound action potential monitoring in the removal of small acoustic neurinoma via the retrosigmoid approach. *J Neurol Neurosurg Psychiatry* 2009;80:218-27.
- Liu BY, Tian YJ, Liu W, Liu SL, Qiao H, Zhang JT, et al. Intraoperative facial motor evoked potentials monitoring with transcranial electrical stimulation for preservation of facial nerve function in patients with large acoustic neuroma. *Chin Med J (Engl)* 2007;120:323-5.
- Goldbrunner RH, Schlake HP, Milewski C, Tonn JC, Helms J, Roosen K. Quantitative parameters of intraoperative electromyography predict facial nerve outcomes for vestibular schwannoma surgery. *Neurosurgery* 2000;46:1140-6.
- Neff BA, Ting J, Dickinson SL, Welling DB. Facial nerve monitoring parameters as a predictor of postoperative facial nerve outcomes after vestibular schwannoma resection. *Otol Neurotol* 2005;26:728-32.
- Yamakami I, Uchino Y, Kobayashi E, Yamaura A, Oka N. Removal of large acoustic neurinomas (vestibular schwannomas) by the retrosigmoid approach with no mortality and minimal morbidity. *J Neurol Neurosurg Psychiatry* 2004;75:453-8.
- Ebersold MJ, Harner SG, Beatty CW, Harper CM Jr, Quast LM. Current results of the retrosigmoid approach to acoustic neurinoma. *J Neurosurg* 1992;76:901-9.
- Jung S, Kang SS, Kim TS, Kim HJ, Jeong SK, Kim SC, et al. Current surgical results of retrosigmoid approach in extralarge vestibular schwannomas. *Surg Neurol* 2000;53:370-8; discussion 377-8
- Chen L, Chen LH, Ling F, Liu YS, Samii M, Samii A. Removal of vestibular schwannoma and facial nerve preservation using small suboccipital

- retrosigmoid craniotomy. *Chin Med J (Engl)* 2010;123:274-80.
25. Briggs RJ, Luxford WM, Atkins JS Jr, Hitselberger WE. Translabyrinthine removal of large acoustic neuromas. *Neurosurgery* 1994;34:785-90; discussion 790-1.
  26. Haque R, Wojtasiewicz TJ, Gigante PR, Attiah MA, Huang B, Isaacson SR, *et al.* Efficacy of facial nerve-sparing approach in patients with vestibular schwannomas. *J Neurosurg* 2011;115:917-23.

**How to cite this article:** Taddei G, Marrelli A, Trovarelli D, Ricci A, Galzio RJ. Facial functional outcome in monitored versus not-monitored patients in vestibular schwannomas surgery. *Asian J Neurosurg* 2016;11:402-6.

**Source of Support:** Nil, **Conflict of Interest:** None declared.