

## CASE REPORT

# Excision of hypoglossal neurinoma by condyle sparing suboccipital keyhole approach

Harjinder Bhatoe

Department of Neurosurgery, Command Hospital (WC), Chandimandir Cantt, Panchkula, Haryana, India

## ABSTRACT

Hypoglossal neurinomas are rare tumors that present with gradually worsening unilateral wasting of the tongue. The tumors often attain large size prior to detection and often extend into the hypoglossal canal. Large tumors can distort the brainstem and cerebellum. Preoperative diagnosis can often be made by magnetic resonance imaging (MRI) with contrast enhancement. Traditionally, surgery for these tumors has entailed large transcondylar approaches, often necessitating occipitocervical stabilization. We managed one 23-year-old female patient with a large hypoglossal neurinoma. The tumor could be excised completely by a condyle-sparing minimally invasive suboccipital keyhole approach.

**Key words:** Hypoglossal neuronima, intracranial schwannoma, keyhole surgery

## Introduction

Hypoglossal neurinomas are rare tumors that occur in the region of foramen magnum and extend into the hypoglossal canal. Extracranial, dumbbell extension is unusual, occurring in about 30% of these tumors.<sup>[1]</sup> Pure extracranial tumors are extremely rare.<sup>[2]</sup> As the hypoglossal nerve is closely applied to the posterior fossa floor, hypoglossal schwannomas grow towards the cistern magna, displacing the cerebellum cranially and the brainstem contralaterally.<sup>[3]</sup> Midline subtonsillar approach provides adequate approach in most of the cases allowing tumor removal with the brainstem, posterior inferior cerebellar artery and lower cranial nerves under direct vision.<sup>[4]</sup> The goal of tumor removal can be achieved by keeping it simple, and avoiding the morbidity associated with the extensive transcondylar approaches.

## Case Report

A 47-year-old housewife was admitted with seven-month history of difficulty in talking and chewing food. She did not

have lingual or facial pain, dysphagia, dysphonia, ataxia, or headache. Neurological evaluation revealed mild wasting of left side of tongue with deviation of the tongue to the left on protrusion. There was no other sensory loss or motor weakness. Contrast magnetic resonance imaging (MRI) brain revealed a well-defined extra-axial solid mass lesion near the foramen magnum, with the lesion extending into the left hypoglossal canal [Figures 1-3]. She underwent the surgery on 15 April 2010. Patient was placed in right lateral position with the head tilted to the right and fixed in Mayfield head clamp. Retromastoid incision was given and craniectomy about 2.75 cm in size was done posterior to the sigmoid sinus and occipital condyle. Foramen magnum rim was not opened. Dura was opened and cerebellum was relaxed by drainage of cistern magna and cerebellomedullary cistern. Cerebellum margin was gently retracted, revealing well-circumscribed, solid encapsulated tumor arising from the hypoglossal rootlets. Accessory, vagus and glossopharyngeal nerves were normal. Tumor was cored out, debulked and dissected off the brainstem and posterior fossa floor. The part of tumor inside the canal could be teased out and total excision could be achieved, preserving the cranial rootlets of the nerve. Dura was closed, followed by closure of muscle layer and scalp. Postoperative period was uneventful, and she was discharged on the fifth

This is an open access article distributed under the terms of the Creative Commons Attribution-NonCommercial-ShareAlike 3.0 License, which allows others to remix, tweak, and build upon the work non-commercially, as long as the author is credited and the new creations are licensed under the identical terms.

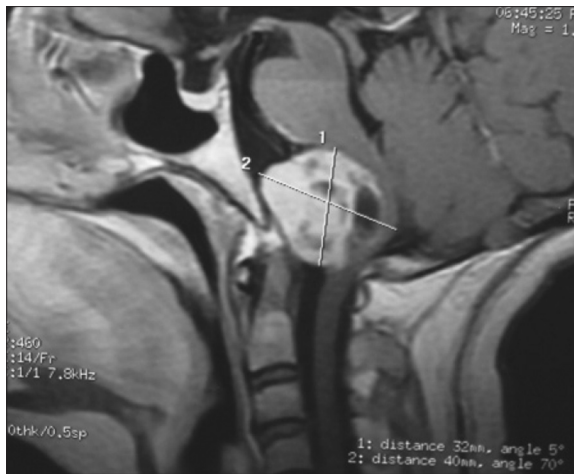
**For reprints contact:** reprints@medknow.com

Access this article online	
Quick Response Code:	Website: www.asianjns.org
	DOI: 10.4103/1793-5482.144203

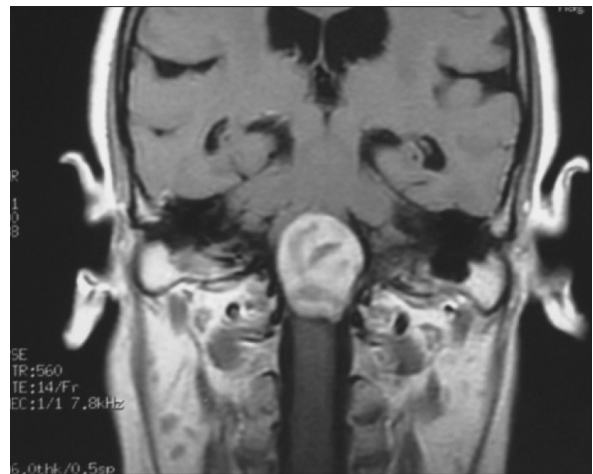## Address for correspondence:

Dr. Harjinder Bhatoe, Department of Neurosurgery, Command Hospital, Chandimandir Cantt, Panchkula, Haryana, India. E-mail: hsbhatoe@gmail.com

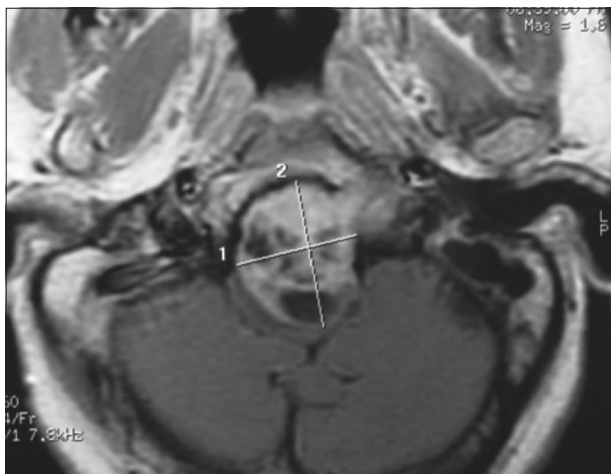
**How to cite this article:** Bhatoe H. Excision of hypoglossal neurinoma by condyle sparing suboccipital keyhole approach. Asian J Neurosurg 2017;12:120-2.



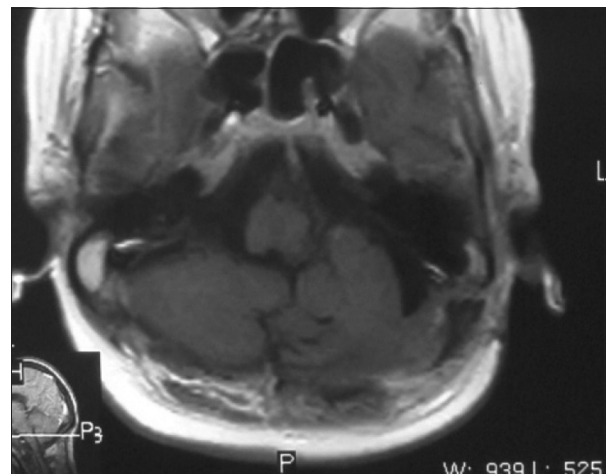
**Figure 1:** Contrast enhanced sagittal MRI (T1-weighted) showing hypoglossal schwannoma



**Figure 2:** Contrast enhanced coronal MRI (T1-weighted) showing hypoglossal schwannoma



**Figure 3:** Contrast enhanced axial MRI (T1-weighted) showing hypoglossal schwannoma



**Figure 4:** Postoperative contrast enhanced axial MRI (T1-weighted) showing complete excision

postoperative day. Histopathology revealed the tumor to be World Health Organization (WHO) grade I schwannoma. Patient has remained well for six months after surgery. Tongue wasting has remained static. Contrast MRI of posterior fossa did not reveal any residual tumor [Figure 4].

## Discussion

The first description of hypoglossal schwannoma was given by De Martel in 1933.<sup>[5]</sup> Since then, nearly 100 cases of hypoglossal schwannoma have been described.<sup>[6]</sup> These intracranial tumors can extend extracranially through the hypoglossal canal. The occipital condyle is bordered on three sides by rim of foramen magnum,<sup>[6]</sup> and approaches to hypoglossal neurinoma have transgressed the condyle or the rim of foramen magnum. The approaches have been lateral transcondylar, suboccipital or midline suboccipital subtonsillar.<sup>[1,4,7]</sup> Ichimura *et al.* preserved the FM and condyle in one out of seven patients; this patient had largely extradural tumor eroding the jugular foramen.<sup>[6]</sup>

Tumor excision by transcondylar and transmastoid routes has been followed with nerve grafting with sural nerve, which resulted in recovery of tongue function.<sup>[8]</sup> All these approaches give wide exposure of the tumor, and can be called as 'ideal'. However, with experience, these tumors can be removed through limited access.

With the availability of magnification and good illumination together with better brain relaxation, principles of keyhole surgery can be applied to these tumors, as they occur intradurally, and are surrounded by cerebrospinal fluid (CSF) spaces. Cerebellar retraction is not significant in view of the large tumor displacing the cerebellum and providing adequate working space after it has been internally debulked. Drainage of CSF from cistern magna, cerebellomedullary, and prepontine cisterns aids in relaxation of cerebellum and obtaining adequate exposure. Once CSF has been suctioned, cerebellum can be gently lifted with the retractor placed just lateral to the tonsil. The direction of cerebellar retraction has to be more cranial than medial. Vertebral

artery and spinal rootlets of accessory nerve can be displaced away, while the tumor is being debulked. Since the approach is essentially caudal to the tumor, the cranial nerves IX – XI are safeguarded. Preservation of arachnoid over these structures is the key to their safety, and frequent shifting of the viewing angle of the microscope aids in its complete visualization, debulking and complete excision using tube shaft instruments. Extension into the hypoglossal canal too can be removed with gentle retraction and teasing the tumor off the hypoglossal nerve. Although not required in the abovementioned report, intracanalicular portion can be removed by limited drilling of the condylar canal through the same approach.

### **Conclusion**

Traditionally, approaches to hypoglossal neuronima have involved large craniotomies with violation or excision of occipital condyle. These approaches may require occipitocervical stabilization. These tumors can be excised by minimally invasive suboccipital approach with application of principles of keyhole microneurosurgery. The neurinoma can be completely excised even from its intracanalicular part.

### **Financial support and sponsorship**

Nil.

### **Conflicts of interest**

There are no conflicts of interest.

### **References**

1. Kachhara R, Nair S, Radhakrishnan VV. Large dumbbell neurinoma of hypoglossal nerve. Case report. *Br J Neurosurg* 1999;13:338-40.
2. Attallah M, Maier H, Altmannsberger M. Peripheral neurinoma of the hypoglossal nerve. *HNO* 1988;36:255-6.
3. Sato M, Kanai N, Fukushima Y, Matsumoto S, Tatsumi C, Kitamura K, *et al.* Hypoglossal neurinoma extending intra- and extracranially: Case report. *Surg Neurol* 1996;45:172-5.
4. Tatagiba M, Koerbel A, Roser F. The midline suboccipital approach to the hypoglossal canal: Surgical anatomy and clinical application. *Acta Neurochir (Wien)* 2006;148:965-9.
5. De Martel T, Subirana A, Guillaune J. Los tumores de la fosa cerebral posterior: Voluminoso neurinoma del hipogloso con desarrollo juxta-bulbo-protuberancial. *Operacioncuracion Ars Med* 1933;9:416-9.
6. Ichimura Shinya, Yoshida K, Kawase T. Surgical approach for hypoglossal schwannomas to prevent deformity of the atlantooccipital joint. *Acta Neurochir (Wien)* 2009;151:575-9.
7. Spinnato S, Talacchi A, Musumeci A, Turazzi S, Bricolo A. Dumbbell-shaped hypoglossal neurinoma: Surgical removal via a dorsolateral transcondylar approach. A case report and review of the literature. *Acta neurochi (Wien)* 1998;140:827-32.
8. Mathiesen T, Svensson M, Lundgren J, Kihlström L, Parisotto R, Bagger-Sjöbäck D. Hypoglossal schwannoma – successful reinnervation and functional recovery of the tongue following tumour removal and nerve grafting. *Acta Neurochir (Wien)* 2009;151:837-41.