

## CASE REPORT

# Alveolar soft part sarcoma with brain metastases

Vinodh Vayara Perumall, Rahmat Harun, Pulivendhan Sellamuthu, Mohd Shariman Md Shah<sup>1</sup>

Departments of Neurosurgery and <sup>1</sup>Pathology, Queen Elizabeth Hospital, Kota Kinabalu, Sabah, Malaysia

## ABSTRACT

Metastatic tumors are the most common mass lesions in the brain. This case reports a rare form of sarcoma with metastasis to the brain. The appropriate management of a patient with metastatic alveolar soft part sarcoma to the brain is discussed. Author describes a 32-year-old gentleman diagnosed with primary tumor at gluteus and distant metastases at lower lobe of right lung and the brain. Histopathology proves diagnosis as alveolar soft part sarcoma. Craniotomy with excision of brain lesion was done. Repeated magnetic resonance imaging of the brain after 2 months showed rapidly growing new lesions. The next step of management was made by the oncology team as recurrence rate was high and due to multi-systemic involvement. Patient was planned for palliative chemotherapy and to be reassessed later. This case report discusses the appropriate approach to any form of brain metastases and the role of early follow-up especially after surgery for better outcome and choice of post operative management such as radiotherapy or chemotherapy or both for malignant tumors. Based on this report, it was concluded that every brain tumor patient should be frequently monitored even in the outpatient setting as most of them are metastatic and rapidly spreading. The patient should be considered for radiotherapy or chemotherapy or both after surgery if the histopathology result is suggestive of malignancy.

**Key words:** Alveolar soft part sarcoma, brain metastases, central nervous system neoplasm, combined therapy, tumor recurrence

## Introduction

Metastatic tumors are among the most common mass lesions in the brain.<sup>[1]</sup> Alveolar soft-part sarcoma (ASPS) was first described as a separate entity in 1952.<sup>[2]</sup> The average age at diagnosis is 20 years for women and 30 years for men. All ASPS tumors are considered high grade, and in the long run ASPS is usually a fatal disease.<sup>[3]</sup> Brain metastases have been reported to be a common feature of Stage IV, and recent practice guidelines recommend routine intracranial imaging as part of the staging evaluation in all patients who present with ASPS.<sup>[4]</sup> ASPS is a slow-growing, indolent tumor with metastases that may appear late.<sup>[5]</sup> Even though its progression is indolent, it is considered to be a malignant tumor. Death has occurred from disseminated sarcoma as late as 20 years

after diagnosis. After surgical excision of the primary tumor, local recurrence occurs in 11-50% of patients.<sup>[4]</sup> Children have better overall survival compared with adults.<sup>[6]</sup> It is accepted that patients with single brain metastasis and with controlled or absent extra cranial tumor activity should be treated with surgery and radiotherapy, especially when they are younger than 60 years.<sup>[7]</sup> Surgical excision with an attempt at obtaining tumor-free margins is accepted as the treatment of choice for both primary tumors and metastatic tumors in the brain and lung.<sup>[8,9]</sup>

We report a unique case of alveolar soft part sarcoma with primary at the gluteus region and the distant metastases to the brain and lungs of a 32-year-old gentleman.

## Case Report

A 32-year-old gentleman was referred for left frontal brain lesion for further management. He presented with headache,

This is an open access article distributed under the terms of the Creative Commons Attribution-NonCommercial-ShareAlike 3.0 License, which allows others to remix, tweak, and build upon the work non-commercially, as long as the author is credited and the new creations are licensed under the identical terms.

**For reprints contact:** reprints@medknow.com

| Access this article online  |                                  |
|---|----------------------------------|
| Quick Response Code:  | Website:<br>www.asianjns.org     |
|  | DOI:<br>10.4103/1793-5482.144197 |

### Address for correspondence:

Dr. Vinodh Vayara Perumall, Level 8, Lorong Bersatu,  
Off Jalan Damai, 88300 Luyang, Kota Kinabalu, Sabah, Malaysia.  
E-mail: vinodhvayara@gmail.com

**How to cite this article:** Perumall VV, Harun R, Sellamuthu P, Shah MS. Alveolar soft part sarcoma with brain metastases. Asian J Neurosurg 2017;12:112-5.

giddiness, and blurring of vision at left eye for the past 2 months. All symptoms progressively worsened over time. He has no other known medical illnesses nor complained of anything else. There is no significant family history of tuberculosis (TB) exposure or malignancy. History of smoker about 15 pack years, not alcoholic and denies other social issues. He has neither drug allergies nor drug adverse effects during his stay in the ward.

On examination, his Glasgow Coma Scale (GCS) was full. He is orientated to time, place, and person. Vital signs were stable throughout admission. No palpable lymph nodes were observed. There were unremarkable cardiovascular, respiratory, neurological, and gastrointestinal system findings. Fundoscopy reveals left eye papilloedema. Karnofsky performance status (KPS) is 80% in which patient is able to perform normal activity with some difficulty due to symptoms such as headache, giddiness, and blurring of vision.

Metastasis was made as one of the differential diagnosis from the computed tomography (CT) brain findings. Screening was done by means of CT thorax-abdomen-pelvis for distant metastases and lung lesions were found. Bronchoscopy revealed abnormal lower tracheal mucosa and right hilar-carina region appears widened. Biopsy result was not suggestive as there is no diagnostic material received. He also later complained of left sided upper thigh pain radiating to the front and we noted left gluteal mass from which biopsy was taken and the result is mesenchymal tumor suggestive of alveolar soft part sarcoma.

Patient was operated due to a good life expectancy as the left frontal brain lesion was solitary. Craniotomy with complete excision of tumor was done in December 2011. Intra-operative findings were vascularized tumor with a mix of solid-cystic-friable lesion and total excision was done.

Results of diagnostic imaging are as below:

### Chest X-ray (October 2011)

Noted multiple hypodense lesions (cannon ball lesions) and huge radio opaque lesion at mediastinum [Figure 1].

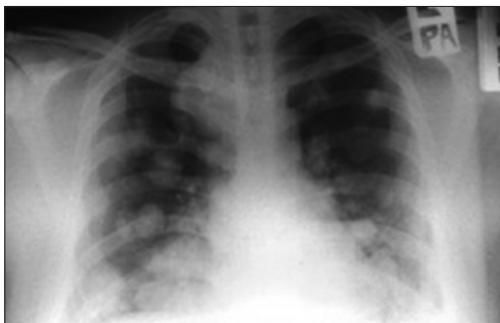

Figure 1: Chest x-ray (October 2011)

### MRI BRAIN (November 2011)

Left frontal lobe mass with significant mass effect and small lesion at occipital lobe [Figure 2].

### CT scan Thorax-Abdomen-Pelvis (November 2011)

Right lower lobe lung mass (7.5 × 8 cm) extending to mediastinum, multiple lung metastases, normal CT abdomen and pelvis. Left gluteus mass is probably metastasis. T4 N2 M1, Stage IV Carcinoma. Conclusion made as advanced carcinoma of the right lower lobe with multiple lung metastases and left gluteal metastasis [Figure 3].

Results of histopathological examination are as below:

### Bronchoscopy (December 2011)

No diagnostic material or inadequate for interpretation.

### Gluteus mass biopsy histopathology examination (December 2011)

Mesenchymal tumor suggestive of alveolar soft part sarcoma [Figure 4].

### Left frontal brain tumor histopathology examination (December 2011)

Features are compatible with metastatic tumor, request to correlate with gluteus mass biopsy result [Figure 5].

He is asymptomatic at his next review but repeated scan shows multiple new brain lesions in just 2 months post operative period. He is planned for palliative chemotherapy due to high recurrence rate and multi-systemic involvement.

### MRI BRAIN (February 2012) - Post operative

Left frontal lesion, right occipital lesion, right parietal lesion, and midline intraventricular lesion. Features show local spread to the surrounding brain tissue [Figure 6].

### Discussion

Alveolar soft part sarcoma is a malignant neoplasm designated in the past as organoid granular cell myoblastoma and malignant non chromaffin paraganglioma. It is seen in the younger age of <30 years, with an age range of 0-74 years. Most of the patients are young females. This tumor is very

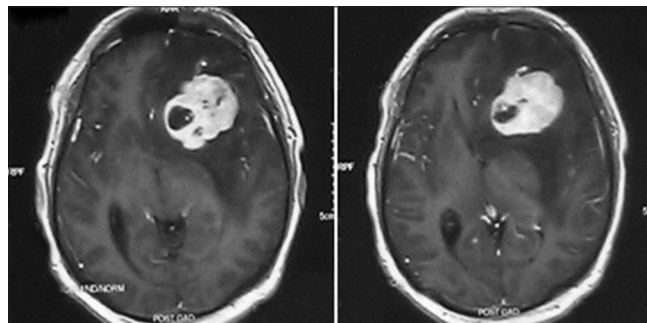
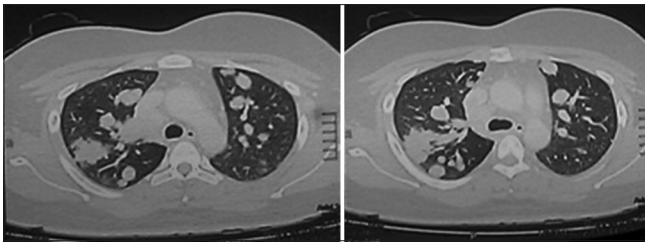
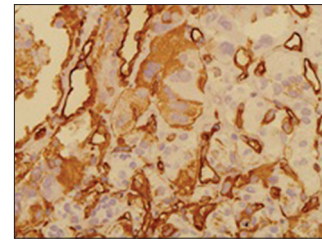


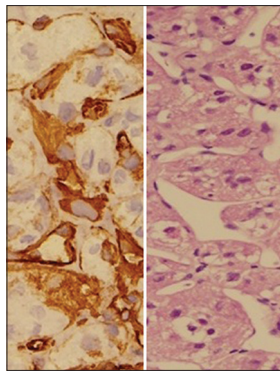
Figure 2: Magnetic resonance imaging BRAIN (November 2011)



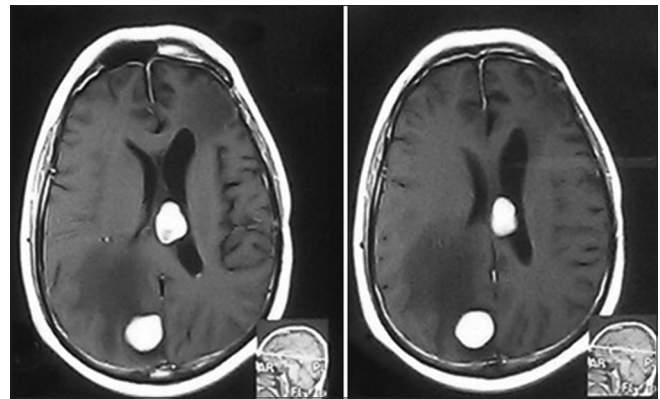
**Figure 3:** Computed tomography scan Thorax-Abdomen-Pelvis (November 2011)



**Figure 4:** Gluteus mass biopsy histopathology examination (December 2011)



**Figure 5:** Left frontal brain tumor histopathology examination (December 2011)



**Figure 6:** Magnetic resonance imaging BRAIN (February 2012)

vascular and bruit is usually present. Local recurrence rate is 20-33%. It is known to have late recurrences.<sup>[4,10]</sup> Incidence of metastasis is 66%. It usually occurs in extremities especially thigh, buttock, oral cavity, pharynx, including tongue, mediastinum, sometimes from pulmonary vein, stomach, retroperitoneum, uterus, vagina, and orbit. The five years survival is quoted to be 59-67% and 10 years survival is 47%. Most of the patients eventually die of the disease.<sup>[11,12]</sup>

The differential diagnosis includes paraganglioma, rhabdomyosarcoma, renal cell carcinoma, metastatic adrenal carcinoma, clear cell carcinoma, and melanoma.<sup>[7]</sup>

In this case, recurrence occurred 2 months after tumor excision. Any cases of brain tumors should be on regular follow up at shorter intervals and treatment should be optimized as the incidence of metastatic brain tumors exceeds that of primary brain tumors, accounting for 50% of total brain tumors and for as many as 30% of tumors seen on imaging studies alone. An estimated 100,000 new cases are diagnosed per year in the United States; about 60% of patients are aged 50-70 years.<sup>[1]</sup>

Although radiotherapy and chemotherapy have occasionally been reported to produce regression or slow the spread of metastases, no results of controlled studies are available.<sup>[13,14]</sup> Long term outcome is unable to be proven as more time is needed to follow up on this case. As the patient is still young, probably aggressive measures should be advised such as chemotherapy or radiotherapy or both. Probably combined therapy can contribute towards increase in quality of life

or survival years. As this is a rare form of tumor, such low numbers of occurrence seriously impede the search for a cure by making it hard to gather any meaningful statistics about the disease. As a result, finding the best treatment option often involves making a lot of educated guesses.

Surgery is effective in treating selected patients with sarcoma metastatic to the brain and that patients with metastasis from alveolar soft-part sarcoma may have a relatively good prognosis if they are surgically treated.<sup>[15]</sup> It is also believed that radiosurgery plus whole brain radiotherapy (WBRT) would provide improved local brain tumor control over WBRT alone in patients with two to four brain metastases.<sup>[16]</sup> Surgical resection of brain metastasis could be considered for solitary brain metastasis in non-eloquent areas. Palliative radiotherapy is appropriate for patients with multiple brain metastases or other co-existing extra-cranial pathology. Long term follow-up of patients with localized ASPS reveals a relatively indolent clinical course with relatively low rates of local and distant recurrence. In patients with Stage IV ASPS, brain metastases were observed only as part of more disseminated disease.<sup>[4]</sup>

## Conclusion

Early surgery and regular follow up with shorter intervals for alveolar soft part sarcoma patients are essential as new brain lesions were found two months after the first surgery which proves it to be a rapidly spreading cancer and eventually lead to a bad prognosis. As for our centre, this case report proves the role of early intervention and the need of additional

modalities of therapy besides surgery. In general, appropriate therapy is chosen based on the extent of the primary disease, other systemic involvements, histopathological result, patient age and current status. The number, size and location of the brain metastases are also important in determining the appropriate management. Available modalities of treatment include radiotherapy, stereotactic radiosurgery (SRS), surgery, and chemotherapy. Combined therapy with surgery and radiotherapy or chemotherapy or both is believed to improve the survival and quality of life but is less clear. More studies can be done to prove the efficacy of combined surgery and radiotherapy or chemotherapy or both in cases of metastatic brain tumors especially in alveolar soft part sarcoma. It is hoped that further advances which are currently under study and combined therapies as stated above will result in better patient outcomes.

### Financial support and sponsorship

Nil.

### Conflicts of interest

There are no conflicts of interest.

### References

- Brain Metastasis online article from Medscape reference by Victor Tse-MD, PhD Department of Neurosurgery, Stanford University Medical Center, Santa Clara Valley Medical Center. Available from: <http://emedicine.medscape.com/article/1157902-overview>. [Last accessed on 2011 Oct 7].
- Christopherson WM, Foote FM Jr, Stewart FW. Alveolar soft part sarcoma; Structurally characteristic tumors of uncertain histogenesis. *Cancer* 1952;5:100-11.
- Nickerson HJ, Silberman T, Jacobsen FS, Krawisz BR, Maki HS, Arndt CA. Alveolar soft-part sarcoma responsive to intensive chemotherapy. *J Pediatr Hematol Oncol* 2004;26:233-53.
- Portera CA Jr, Ho V, Patel SR, Hunt KK, Feig BW, Respondek PM, *et al.* Alveolar soft part sarcoma: Clinical course and patterns of metastasis in 70 patients treated at a single institution. *Cancer* 2001;91:585-91.
- Auerbach HE, Brooks JJ. Alveolar soft part sarcoma. A clinicopathologic and immunohistochemical study. *Cancer* 1987;60:66-73.
- Pappo AS, Parham DM, Cain A, Luo X, Bowman LC, Furman WL, *et al.* Alveolar soft part sarcoma in children and adolescents: Clinical features and outcome of 11 patients. *Med Pediatr Oncol* 1996;26:81-4.
- Noordijk EM, Vecht CJ, Haaxma-Reiche H, Padberg GW, Voormolen JH, Hoekstra FH, *et al.* The choice of treatment of single brain metastasis should be based on extracranial tumor activity and age. *Int J Radiat Oncol Biol Phys* 1994;29:711-7.
- Kodama K, Doi O, Higashiyama M, Yokouchi H, Kuriyama K, Ueda T, *et al.* Surgery for multiple lung metastases from alveolar soft-part sarcoma. *Surg Today* 1997;27:806-11.
- Simmons WB, Haggerty HS, Ngan B, Anonsen CK. Alveolar soft part sarcoma of the head and neck. A disease of children and young adults. *Int J Pediatr Otorhinolaryngol* 1989;17:139-53.
- Anderson ME, Hornicek FJ, Gebhardt MC, Raskin KA, Mankin HJ. Alveolar soft part sarcoma: A rare and enigmatic entity. *Clin Orthop Relat Res* 2005;438:144-8.
- Rosai J, Ackerman LV. *Soft tissues. Surgical Pathology*, 9<sup>th</sup> ed. New Delhi: Elsevier; 2004. p. 2237-330.
- Almansoori M, Turner AR, Girgis S, Vethanayagam D. Alveolar soft part sarcoma presenting with eosinophilia and shunt. *Can Respir J* 2005;12:389-91.
- Raney RB Jr. Proceedings of the tumor board of the Children's Hospital of Philadelphia: Alveolar soft-part sarcoma. *Med Pediatr Oncol* 1979;6:367-70.
- Berman TM, Fuhrman SA, Johnson FE. Prolonged survival after bilateral thoracotomy for metastatic alveolar soft-part sarcoma. *Minn Med* 1984;67:261-2.
- Bindal RK, Sawaya RE, Leavens ME, Taylor SH, Guinee VF. Sarcoma metastatic to the brain: Results of surgical treatment. *Neurosurgery* 1994;35:185-91.
- Kondziolka D, Patel A, Lunsford LD, Kassam A, Flickinger JC. Stereotactic radiosurgery plus whole brain radiotherapy versus radiotherapy alone for patients with multiple brain metastases. *Int J Radiat Oncol Biol Phys* 1999;45:427-34.