

CASE REPORT

A common case with an unusual association: Chiari I malformation with holocord syrinx

Sumit Bansal, Sachin A. Borkar, Ashok K. Mahapatra

Department of Neurosurgery, All India Institute of Medical Sciences, New Delhi, India

ABSTRACT

Authors are presenting a common case of Chiari malformation but with a very unusual associated finding, holocord syringomyelia, which responded to posterior fossa decompression. An 11-year-old male patient presented with progressive left hemiparesis and numbness on left half of the body for 4 years. Magnetic resonance imaging of the spine revealed peg-shaped herniation of tonsils 8 mm below the foramen magnum and holocord syringomyelia. No focal intraspinal mass was seen. Chiari I malformation with holocord syrinx was diagnosed. The patient underwent posterior fossa decompression with subpial resection of both tonsils with augmentation duraplasty. Post-operatively, patient improved clinically as well as radiologically.

Key words: Chiari I malformation, holocord syringomyelia, posterior fossa decompression

Introduction

Chiari malformation is a congenital hindbrain abnormality, where the occipital hypoplasia leads to an overcrowding and deformation of brain stem and cerebellum. The subsequent alteration of cerebrospinal fluid (CSF) may be responsible for the development of syringomyelia and hydrocephalus. Authors are presenting a common case of Chiari I malformation but with a very unusual associated finding, holocord syringomyelia, which responded to posterior fossa decompression.

Case Report

Clinical presentation

An 11-year-old male patient presented with complaints of progressive left hemiparesis and numbness on left half of the body for 4 years. On examination, he had spastic hemiparesis with motor power of 4/5 (Medical Research Council Grading) in both upper and lower limbs on the left side. He also had

dissociative sensory loss with pain and temperature being affected more than touch and vibration sensations on left side of the body below C2 dermatome.

Imaging

Magnetic resonance imaging (MRI) of the brain and spine revealed peg-shaped herniation of tonsils 8 mm below the foramen magnum. There was no hydrocephalus. Screening of the whole spine showed holocord syringohydromyelia [Figure 1]. No focal intraspinal mass was seen on contrast MRI. Chiari I malformation with a holocord syrinx was diagnosed.

Operative procedure

The patient underwent posterior fossa decompression with subpial resection of both tonsils with augmentation duraplasty.

Follow-up

He was doing well at the last 6-month follow-up after surgery. He had subjective improvement in numbness on examination. Spasticity had also improved. Follow-up MRI spine showed significant but partial resolution of syrinx [Figure 2].

Access this article online	
Quick Response Code:	Website: www.asianjns.org
	DOI: 10.4103/1793-5482.144169

Address for correspondence:

Dr. Sachin A. Borkar, Department of Neurosurgery, Room No. 720, Neurosciences Center, All India Institute of Medical Sciences, New Delhi - 110 029, India.
E-mail: sachin.aiims@gmail.com

This is an open access article distributed under the terms of the Creative Commons Attribution-NonCommercial-ShareAlike 3.0 License, which allows others to remix, tweak, and build upon the work non-commercially, as long as the author is credited and the new creations are licensed under the identical terms.

For reprints contact: reprints@medknow.com

How to cite this article: Bansal S, Borkar SA, Mahapatra AK. A common case with an unusual association: Chiari I malformation with holocord syrinx. Asian J Neurosurg 2017;12:241-3.

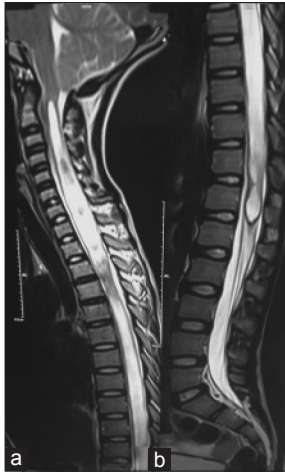

Figure 1: (a,b) Sagittal T2-weighted images show herniation of peg-shaped cerebellar tonsils 8 mm below the level of the foramen magnum with mild expansion of cervical spinal cord with hydrosyringomyelia and extension upto upper border of L1

Discussion

A detailed description of the various hindbrain herniation was published by Chiari,^[1] hence they are called as Chiari malformations. Chiari I malformation is traditionally defined as downward displacement of the cerebellar tonsils and, sometimes, the inferior vermis through the foramen magnum into the rostral cervical canal. Between the ages of 5 and 15 years, descent of upto 6 mm is not considered pathological. However, in older patients, tonsillar protrusion >5 mm is associated with onset of clinical symptoms.^[2]

It has been shown in several studies that Chiari I malformation is, most of all, a disorder related to a small posterior fossa forcing the tonsils into the spinal canal^[3] with a possible genetic predisposition.^[3] Apart from a small posterior fossa volume, additional anomalies may involve the joints and discs of the craniocervical junction. Assimilations of the atlas to the occiput, basilar invagination, or Klippel–Feil syndrome are features to look for pre-operative imaging because they may indicate craniospinal instability.^[4,5] Bony anomalies are seen in about one-quarter of all patients with Chiari I malformation and include atlanto-occipital assimilation, platybasia, basilar invagination, and fused cervical vertebrae. These are thought to be caused by an underdeveloped occipital bone, possibly due to underdevelopment of the occipital somite.^[6]

Symptoms of Chiari malformations are related to age: In infancy, signs of brainstem compression predominate with apnea spells, cyanosis attacks, and swallowing problems, whereas in later childhood, scoliosis becomes the most common presenting sign. The typical clinical features of occipital headache, gait ataxia, sensory disturbances, and motor weakness are uncommon in children and observed predominantly in adults.^[7,8]

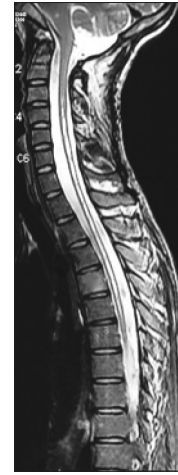


Figure 2: Post-operative magnetic resonance imaging sagittal T2-weighted image of the whole spine shows the significant but partial resolution of syrinx

The term syringohydromyelia is credited to Ollivier d'Angers,^[9] though the presence of such cavities was recognized much earlier.^[10,11] Ollivier d'Angers and others recognized the association of such syrinxes with hindbrain anomalies. Syringomyelia is associated with Chiari malformation in 25-65% cases.^[9] This results from obstruction of CSF circulation in the cisterna magna. The presence of a syrinx is more commonly associated with symptoms.^[3] However, holocord syringomyelia is rarely reported in literature.^[12,13]

Gardner and Goodall^[14] are credited for bringing the attention to manage the hindbrain anomaly with suboccipital decompression as a method of treatment of the syringohydromyelia. Their hydrodynamic theory was widely accepted. This theory was questioned by Williams,^[15] who put forth a craniospinal pressure dissociation theory. It too presumed a patency of the fourth ventricle and the syringohydromyelia cavity. Later, Oldfield *et al.*^[16] have looked at CSF pressure waves in the basal cisterns and spinal subarachnoid space during systole and diastole. Spinal fluid is seen to enter the cavity from the subarachnoid space via the Virchow–Robin spaces. This theory does not assume a patency between the fourth ventricle and the syrinx cavity. Another theory which explains the pathophysiology of syringohydromyelia associated with Chiari malformations comes from Milhorat *et al.*,^[17] whose studies suggest that constriction of the aperture of the upper end of the central canal leads to non-communicating syringohydromyelia.^[17]

Surgical treatment has been recommended only for symptomatic patients.^[18,19] The selection of operative intervention to be performed is multifactorial. It depends mainly on the surgeon's choice, the information obtained from the pre-operative neuroimaging, and the age of the patient at the time of presentation.

The standard surgical treatment for the Chiari 1 malformation is suboccipital craniectomy ± upper cervical laminectomy.^[12,20]

Most neurosurgeons open the dura mater routinely.^[12,20] Some do not open the dura^[21] to avoid complications, such as meningitis, CSF leakage, and pseudomeningocele and rely on adequate bony decompression.^[12,22] Some do open the dura matter but avoid opening the arachnoids.^[12,23] Overall, consensus is toward doing bony as well as dural decompression.

Conclusion

Holocord syringomyelia associated with Chiari malformation is very rare. In our case, patient improved both clinically and radiologically with foramen magnum decompression with resection of tonsils with augmentation duraplasty with significant but partial resolution of syrinx on follow-up, thereby supporting the need for intradural procedure in management of holocord syringomyelia associated with Chiari malformation.

Financial support and sponsorship

Nil.

Conflicts of interest

There are no conflicts of interest.

References

- Chiari H. Über Veränderungen des kleinhirns in folge von hydrocephalie des grosshirns. *Deutsch Med Wochenschr* 1891;17:1171-75.
- Robertson R, Caruso PA, Truwit CL, Barkovich AJ. Disorders of brain development. In: Atlas SW, editor. *Magnetic resonance imaging of the brain and spine*. Philadelphia, PA: Lippincott Williams and Wilkins; 2002. p. 279-369.
- Milhorat TH, Chou MW, Trinidad EM, Kula RW, Mandell M, Wolpert C, et al. Chiari I malformation redefined: Clinical and radiographic findings for 364 symptomatic patients. *Neurosurgery* 1999;44:1005-17.
- Tubbs RS, Lyster MJ, Loukas M, Shoja MM, Oakes WJ. The pediatric Chiari I malformation: A review. *Childs Nerv Syst* 2007;23:1239-50.
- Tubbs RS, Beckman J, Naftel RP, Chern JJ, Wellons JC 3rd, Rozzelle CJ, et al. Institutional experience with 500 cases of surgically treated pediatric Chiari malformation type I. *J Neurosurg Pediatr* 2011;7:248-56.
- Caldarelli M, Di Rocco C. Diagnosis of Chiari I malformation and related syringomyelia: Radiological and neurophysiological studies. *Childs Nerv Syst* 2004;20:332-5.
- Rauzzino M, Oakes WJ. Chiari II malformation and syringomyelia. *Neurosurg Clin N Am* 1995;6:293-309.
- Menezes AH, Greenlee JD, Donovan KA. Honored guest presentation: Lifetime experiences and where we are going: Chiari I with syringohydromyelia: Controversies and development of decision trees. *Clin Neurosurg* 2005;52:297-305.
- Ollivier d'Angers CP. *Traité de la moelle epinaré et de ses maladies*. Paris, Chez Crevot 1827;178-83.
- Brunner JC. De hydrocephalo, sive hydrops capitis. In: Bonneti T, editor. *Sepulchretum, Book I*. 2nd ed. Geneva: Cramer and Perachon; 1700. p. 396.
- Morgagni GB. Letter XII, article 9. The seats and causes of disease. London: Millar and Cadel; 1769. p. 370.
- Feldstein NA, Choudhri TF. Management of Chiari I malformations with holocord syringohydromyelia. *Pediatr Neurosurg* 1999;31:143-9.
- Kumar J, Kumar A, Gupta S. Neurological pictures. Chiari I malformation with holocord syrinx. *J Neurol Neurosurg Psychiatry* 2007;78:146.
- Gardner WJ, Goodall RJ. The surgical treatment of Arnold-Chiari malformation in adults; an explanation of its mechanism and importance of encephalography in diagnosis. *J Neurosurg* 1950;7:199-206.
- Williams B. On the pathogenesis of syringomyelia: A review. *J R Soc Med* 1980;73:798-806.
- Oldfield EH, Muraszko K, Shawker TH, Patronas NJ. Pathophysiology of syringomyelia associated with Chiari I malformation of the cerebellar tonsils. Implications for diagnosis and treatment. *J Neurosurg* 1994;80:3-15.
- Milhorat TH, Miller JI, Johnson WD, Adler DE, Heger IM. Anatomical basis of syringomyelia occurring with hindbrain lesions. *Neurosurgery* 1993;32:748-54.
- Venes JL, Black KL, Latack JT. Preoperative evaluation and surgical management of the Arnold-Chiari II malformation. *J Neurosurg* 1986;64:363-70.
- Park JK, Gleason PL, Madsen JR, Goumnerova LC, Scott RM. Presentation and management of Chiari I malformation in children. *Pediatr Neurosurg* 1997;26:190-6.
- Krieger MD, McComb JG, Levy ML. Toward a simpler surgical management of Chiari I malformation in a pediatric population. *Pediatr Neurosurg* 1999;30:113-21.
- James HE, Brant A. Treatment of the Chiari malformation with bone decompression without durotomy in children and young adults. *Childs Nerv Syst* 2002;18:202-6.
- Koyanagi I, Iwasaki Y, Ysu T, Akino M, Abe H, Ikota T, et al. Surgical treatment of syringomyelia with Chiari malformation. Effect of foramen magnum decompression. *Spinal Surg (Tokyo)* 1991;5:43-9.
- Sahuquillo J, Rubio E, Poca MA, Rovira A, Rodriguez-Baeza A, Cervera C. Posterior fossa reconstruction: A surgical technique for the treatment of Chiari I malformation and Chiari I/syringomyelia complex: Preliminary results and magnetic resonance imaging quantitative assessment of hindbrain migration. *Neurosurgery* 1994;35:874-84.