

CASE REPORT

Intra-axial chondroblastoma: A bony tumor in the cerebral hemisphere – A case report and review of literature

Mayur Sharma, Shadma W. Khan, Vernon Velho, Rahul Mally

Department of Neurosurgery, Grant Medical College and Sir J. J. Group of Hospitals, Byculla, Mumbai, Maharashtra, India

ABSTRACT

This case highlights a rare possibility of occurrence of chondroblastoma, a bony tumor, at an uncommon location. Extrasosseous, soft tissue location of this bony tumor is rare and more so for intracranial intra-axial location. We report a case of an intra-axial frontal lobe lesion, histologically proven to be an extrasosseous chondroblastoma. A 23-year-old male presented with a history of headache and vomiting of 1 month duration. Imaging was suggestive of left frontal lobe intra-axial calcified lesion suggestive of oligodendroglioma. Patient was operated upon by left frontal craniotomy with complete excision of the lesion. The patient recovered well postoperatively. Left sixth nerve paresis improved and ataxia decreased. Intra-axial chondroblastomas are extremely rare tumors. Differential diagnosis should be kept in mind, especially in cases of calcified lesions. Complete excision should be the aim to achieve cure.

Key words: Chondroblastoma, extrasosseous, intra-axial

Introduction

Chondroblastomas are rare bony tumors, most commonly found at the epiphyseal ends of long bones and less commonly in other bones like skull^[1-4] and pelvic bones. They are rare at extrasosseous, soft tissue locations.^[5,6] An extrasosseous intracranial location^[7] for this bony tumor is a rare entity. We report a case of an intracranial intra-axial chondroblastoma in a young patient.

Case Report

A 23-year-old, right-handed male was admitted with complaints of headache and vomiting of 1 month duration. There was history of drowsiness and lack of interest in surroundings. On examination, the patient was conscious but disoriented. Immediate registration and recall was impaired, attention

span was reduced, and mini-mental state examination (MMSE) was 24/30. He had a left sixth nerve paresis. Visual acuity was 6/9 in the right eye and 6/18 in the left eye. Gait was ataxic, spastic, and tandem walk was impaired.

The contrast-enhanced computed tomography (CT) scan [Figure 1] showed a hyperdense, well-demarcated lesion with peripheral calcification in the left frontal lobe.

MRI brain showed a well-defined, lobulated, intra-axial mass lesion in the left frontal lobe. It was hypointense with areas of hyperintensity at places on T1W images. On T2W images, the lesion was predominantly hyperintense. On postcontrast study, the lesion showed thick peripheral enhancement [Figure 2]. There was perilesional edema and mass effect on the underlying left lateral ventricle. The findings were suggestive of oligodendroglioma.

The patient was operated by a left frontal craniotomy. Tumor was reaching the surface of left frontal lobe, and with the

This is an open access article distributed under the terms of the Creative Commons Attribution-NonCommercial-ShareAlike 3.0 License, which allows others to remix, tweak, and build upon the work non-commercially, as long as the author is credited and the new creations are licensed under the identical terms.

For reprints contact: reprints@medknow.com

Access this article online	
Quick Response Code:	Website: www.asianjns.org
	DOI: 10.4103/1793-5482.144168

Address for correspondence:

Dr. Mayur Sharma, Department of Neurosurgery, Grant Medical College and Sir J.J. Group of Hospitals, Byculla, Mumbai, Maharashtra - 400 008, India.
E-mail: drmayursharmaneuro@gmail.com

How to cite this article: Sharma M, Khan SW, Velho V, Mally R. Intra-axial chondroblastoma: A bony tumor in the cerebral hemisphere – A case report and review of literature. Asian J Neurosurg 2017;12:266-9.

transcortical approach, complete excision was achieved. The tumor was encapsulated, with thick calcified wall containing caseous, necrotic, and calcified material [Figure 3]. Intratumoral debulking followed by complete excision of the tumor was done.

Postoperatively, the patient recovered well. There was no apparent new neurological deficit. Left sixth nerve paresis improved and ataxia decreased. Patient was discharged on the 6th day following surgery.

The postoperative CT scan [Figure 4] showed complete tumor excision.

On histopathologic examination, the tumor revealed varying degree of cellularity. There were sheets of polyhedral tumor cells, having round to oval grooved nuclei and prominent nucleoli. Occasional mitotic activity and few giant cells were seen. Interspersed among these cells were sheets of cartilaginous tissue. There was extensive calcification, varying

from delicate lace like (chicken wire appearance) to blotchy areas [Figure 5].

The tumor was reported as “benign cartilage forming tumor – Intracranial extrasosseous chondroblastoma.”

Discussion

Chondroblastoma is a cartilage-forming, benign bone tumor. Ewing first described this calcifying giant cell tumor, subsequently designated as “epiphyseal chondromatous giant cell tumor” by Codman in 1931.^[8] The term chondroblastoma was coined by Jaffe and Lichtenstein^[9] in 1942.

Chondroblastoma accounts for less than 1% of all bone tumors. It occurs most commonly at the epiphysis of long bones in young boys in the first and second decades of life. It may uncommonly occur in other bones like pelvis and skull. The skull and facial bones^[1] which develop from enchondral ossification may harbor cartilaginous rests

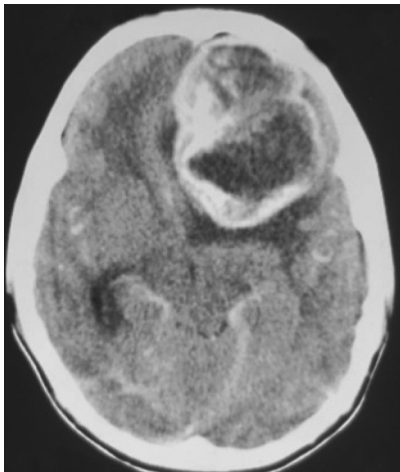


Figure 1: The contrast-enhanced CT scan showing a hyperdense, well-demarcated lesion with peripheral calcification in the left frontal lobe

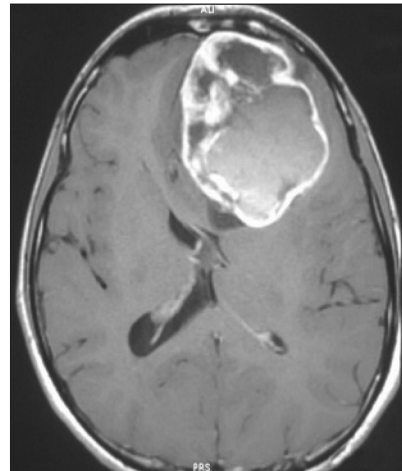


Figure 2: MRI brain showed a well-defined, lobulated, intra-axial mass lesion in the left frontal lobe. On post contrast study, the lesion showed thick peripheral enhancement with perilesional edema and mass effect on the underlying left lateral ventricle

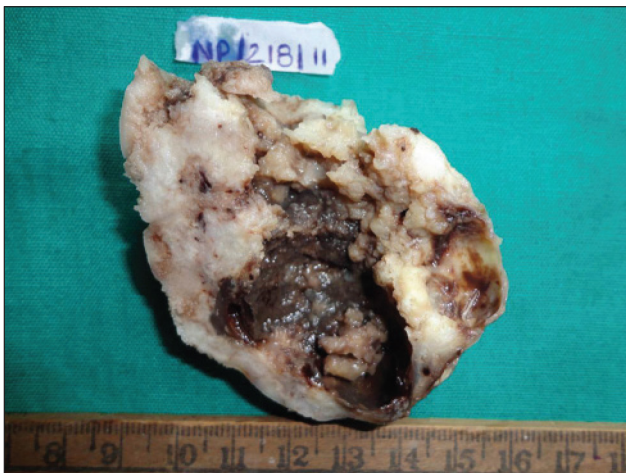


Figure 3: The tumor was encapsulated with thick calcified wall containing caseous, necrotic, and calcified material

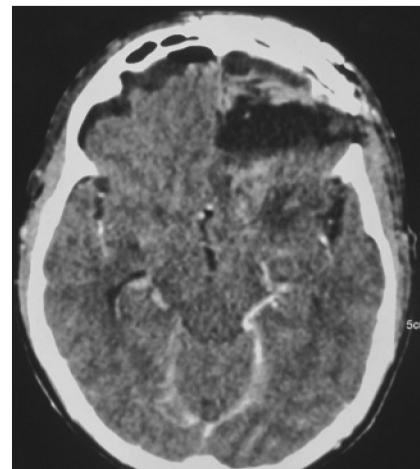


Figure 4: Postoperative CT scan showing complete tumor excision

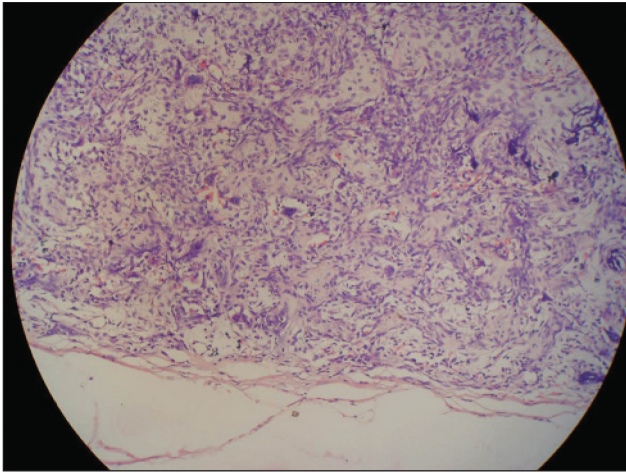


Figure 5: Histopathologic examination showing the tumor cells with varying degree of cellularity. There are sheets of polyhedral tumor cells, having round to oval grooved nuclei and prominent nucleoli. Interspersed among these cells were sheets of cartilaginous tissue. There is extensive calcification, varying from delicate lace like (chicken wire appearance) to blotchy areas

which are the source of cranial chondroblastomas. Among the skull bones, the squamous portion of the temporal bone^[1-4] accounts for more than 70% of the cases. Rarely chondroblastomas may occur in extraosseous locations like in the soft tissue of different parts of the body.^[5,6] However, there is only one case report of an extraosseous intracranial chondroblastoma.^[7]

Most chondroblastomas have a benign course. However, local recurrence, malignant transformation to sarcoma (often after radiation therapy), and distant metastasis have all been reported,^[10,11] thus necessitating a close follow-up.

Radiographically, chondroblastoma in the long bones is characterized by a well-defined osteolytic lesion involving the epiphysis. CT scan depicts a lytic lesion involving the skull bone with areas of calcifications in the center and the periphery of the tumor. Magnetic resonance (MR) imaging demonstrates variable patterns. The tumor can show hypointensity on T1-weighted images, hyperintensity on T2-weighted images, and marked contrast enhancement.^[2] It may show heterogeneous, intensely enhancing solid and multilobulated cystic components.

Histologically, on gross examination, these tumors are lobulated, round, containing friable, soft, grayish pink tissue that may be gritty. If present, the cystic fluid is rust or straw colored. On microscopic examination, there are uniform, polygonal, closely packed cells with abundant cytoplasm and oval-shaped nuclei with a prominent groove (coffee bean). There may be little mitotic activity and scant chondroid matrix. Pericellular deposit of calcification that appears like “chicken wire” is the hallmark of histopathologic diagnosis. Microscopically, the tumor can be confused with chondrosarcoma or giant cell tumor. Though the tumor

may present extreme cellularity, yet it is benign as mitosis is scanty. Extraosseous chondroblastoma occurring in soft tissues is a rare entity with only few case reports in the literature.^[5,6] The first and only case of an extraosseous intracranial chondroblastoma involving the cavernous sinus was reported by Al Mestady *et al.*^[7] We report the first case of extraosseous chondroblastoma of the cerebral hemisphere. The imaging findings were suggestive of oligodendroglioma. However, the tumor was histologically diagnosed as a chondroblastoma.

The tumor was resected completely in this case, which amounts to cure in view of the benign nature of the lesion. However, since there is literature highlighting the fact that sometimes these tumors may recur and even metastasize,^[10-12] the patient has been put on regular follow-up to detect any such transformation at the earliest. On 1 year follow-up, there is no evidence of recurrence and the patient is completely asymptomatic.

Conclusion

Intra-axial chondroblastomas are extremely rare tumors; only one case has been reported in the literature so far. High degree of suspicion is required for the diagnosis, especially in cases of calcified lesions. Complete excision should be the aim to achieve cure, due to the benign nature of the lesion.

Acknowledgment

We would like to thank our Dean, Sir J. J. Group of Hospitals, for allowing us to publish the hospital record.

Financial support and sponsorship

Nil.

Conflicts of interest

There are no conflicts of interest.

References

- Bertoni F, Unni KK, Beabout JW, Harner SG, Dahlin DC. Chondroblastoma of the skull and facial bones. *Am J Clin Pathol* 1987;88:1-9.
- Selesnick SH, Levine JM. Chondroblastoma of the temporal bone: Consistent middle fossa involvement. *Skull Base Surg* 1999;9:301.
- Tsutsumi S, Mishima Y, Nonaka Y, Abe Y, Yasumoto Y, Ito M. A case of chondroblastoma arising from the temporal bone. *No Shinkei Geka* 2010;38:1019-24.
- Hatano M, De Donato G, Falcioni M, Sanna M. Chondroblastoma of the temporal bone. *Acta Otolaryngol* 2011;131:890-5.
- Abdul Karim FW, Ayala AG, Spjut HJ. Extra osseous chondroblastoma in the subcutaneous tissues of right shoulder. *Skeletal Radiol* 1985;14:73-5.
- Granados R, Martín-Hita A, Rodríguez-Barbero JM, Murillo N. Fine-needle aspiration cytology of chondroblastoma of soft parts: Case report and differential diagnosis with other soft tissue tumors. *Diagn Cytopathol* 2003;28:76-81.
- Al Mestady RM, Alorainy IA, El Watidy SM, Arafah MM. Intracranial extraosseous chondroblastoma simulating meningioma. *AJNR Am J Neuroradiol* 2007;28:1880-1.
- Codman EA. Epiphyseal chondromatous giant cell tumors of the upper

- end of the humerus. Surg Gynecol Obstet 1931;52:543-8.
9. Jaffe HL, Lichtenstein L. Benign chondroblastoma of bone. Am J Pathol 1942;18:969-91.
 10. Jambhekar NA, Desai PB, Chitale DA, Patil P, Arya S. Benign metastasizing chondroblastoma. Cancer 1998;82:675-8.
 11. Ozkoc G, Gonlusen G, Ozalay M, Kayaselcuk F, Pourbagher A, Tandogan RN. Giant chondroblastoma of the scapula with pulmonary metastases. Skeletal Radiol 2006;35:42-8.
 12. Kyriakos M, Land VJ, Penning HL, Parker SG. Metastatic chondroblastoma. Report of a fatal case with a review of the literature on atypical, aggressive, and malignant chondroblastoma. Cancer. 1985;55:1770-89.