

## CASE REPORT

# A rare case of recurrent primary spinal echinococcosis

Aabid Ashraf, Altaf R. Kirmani, Abdul R. Bhat, Arif H. Sarmast

Department of Neurosurgery, Sher-i-Kashmir Institute of Medical Sciences, Soura, Srinagar, Jammu and Kashmir, India

## ABSTRACT

Spinal hydatid disease, though rare, is one of the differential diagnosis of spinal cord compression syndrome especially in endemic areas. Surgery is the treatment of choice but surgery alone is not curative. Adjuvant drug therapy as well as intraoperative prophylaxis are indicated. Despite all measures, the disease has high recurrence rates and overall outcome is still poor. We report a case of 65 year old male with lumbosacral hydatidosis recurring after 13 years.

**Key words:** Cyst, hydatid, spine

## Introduction

Spinal hydatidosis is rare, affecting the vertebral column in 0.2-1% of all patients of which spine is involved in approximately 45% of cases.<sup>[1,2]</sup> Vertebral hydatidosis commonly involves the thoracic vertebrae and the cervical, lumbar vertebrae, and sacrum are rare sites to be involved.<sup>[3-5]</sup> Surgery is the treatment of choice however recurrence rates are high.

## Case Presentation

We report a 65 year old man who presented to us with complaints of low backache radiating to left hip for 3 years and urge incontinence for 20 days. Patient had underwent laminectomy with excision of hydatid cysts 13 years back [Figure 1]. Postoperatively patient had received albendazole therapy. On examination, all forms of sensations were decreased bilaterally and symmetrically in the saddle distribution. Motor deficit was not marked but ankle reflex was absent on both sides. Local examination revealed midline scar in lumbosacral region with prominent left paraspinal area. Total blood cell counts, erythrocyte sedimentation rate (ESR), complete biochemical

serum, and urine parameters, coagulation tests, ultrasonography abdomen and chest radiograph were within normal ranges. ELISA for *Echinococcus granulosus* was positive. MRI revealed multiple loculated cystic swelling in left paraspinal area with extension into extradural space at S2 level causing thecal sac compression [Figures 2 and 3]. Patient was put on albendazole preoperatively and underwent re-exploration with excision of multiple hydatid cysts in lumbosacral spine [Figures 4 and 5]. Histopathological examinations confirmed hydatidosis. Postoperatively patient was put on combination therapy of albendazole and praziquantel. Patient recovered uneventfully with good bladder control and without new deficits.

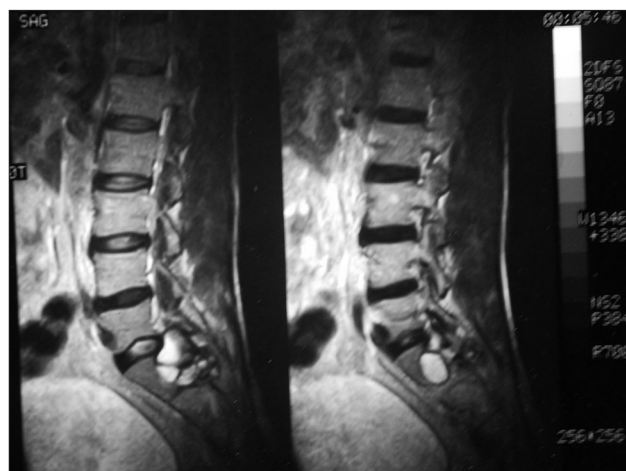## Discussion

Hydatid disease of the spine is a rare form of parasitic infection, commonly observed in Mediterranean areas, such as North Africa, Spain, Greece, Turkey, Portugal, Middle East, Australia, New Zealand, South America, Baltic areas, the Philippines, Northern China and the Indian sub-continent.<sup>[6,7]</sup> The vertebral

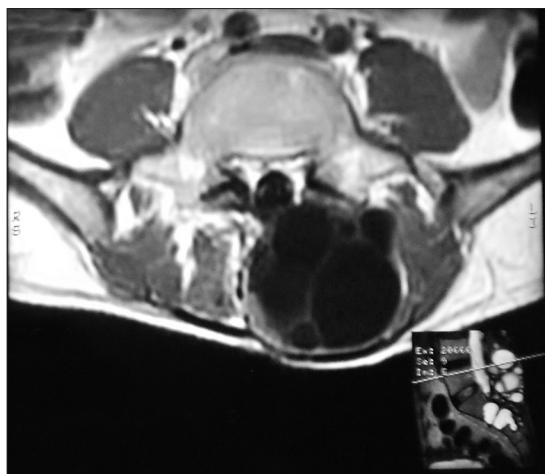
Access this article online	
Quick Response Code:	Website: www.asianjns.org
	DOI: 10.4103/1793-5482.125679

## Address for correspondence:

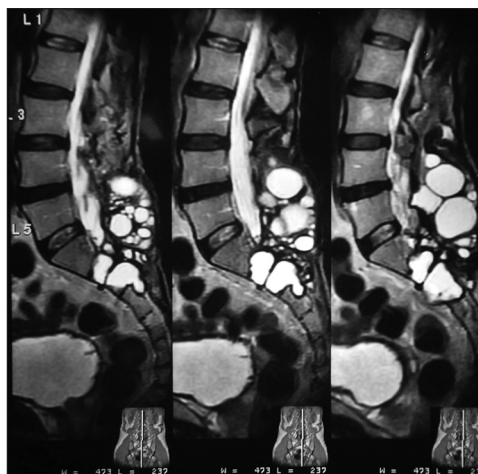
Dr. Aabid Ashraf, Department of Neurosurgery, Sher-i-Kashmir Institute of Medical Sciences, Soura, Srinagar, Jammu and Kashmir, India. E-mail: dr.aabid.ashraf@gmail.com



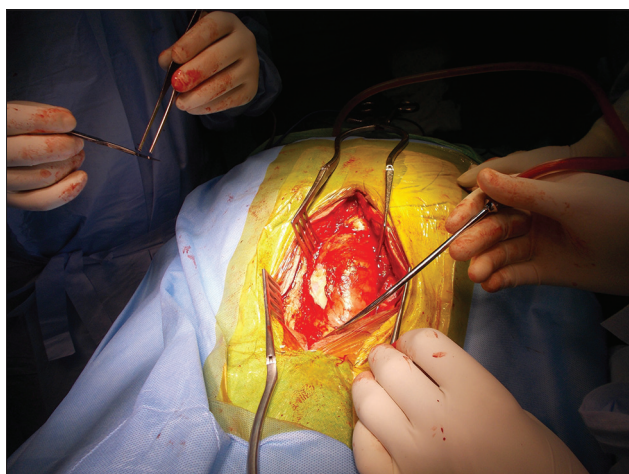**Figure 1:** Hydatid cyst in sacrum (13 years back)



**Figure 2:** Recurrence after 13 years, multiple hydatid cysts causing compression of cauda equina



**Figure 3:** Saggital view



**Figure 4:** Cyst being removed



**Figure 5:** Removed cysts

column is involved in 0.2-1% of all patients, of which spine is involved in approximately 45% of cases.<sup>[1,2]</sup> The thoracic vertebrae are commonly involved and the involvement of cervical, lumbar vertebrae, and sacrum is rare.<sup>[3-5]</sup> However, it remains controversial as to which region is more commonly involved. Spinal hydatid disease causes symptoms and signs related to compression of the cysts on other structures, no specific pathognomonic symptoms or signs exist.<sup>[8]</sup> Usual presentation is radiculopathy, myelopathy, and/or local pain owing to bony destructive lesions, pathological fracture, and consequent cord compression.<sup>[1]</sup> Hydatid cysts of the sacrum are characterized by chronicity without any clinical manifestation and usually misdiagnosed in the early stage, resulting in significant loss of bone and destruction of surrounding tissue.<sup>[9]</sup> Sometimes the spinal hydatid cysts can grow to enormous size and remain asymptomatic for years.<sup>[1]</sup> Routine laboratory tests do not show specific values. Eosinophilia is mostly limited (<15%) or absent. In spinal involvement, the serological sensitivity of antigens is 25%.<sup>[10]</sup>

Magnetic resonance imaging (MRI) is the preferred imaging modality in the diagnosis of hydatid cysts. Some imaging characteristics have been described as typical of spinal hydatid disease. These include lack of osteoporosis and sclerosis in host bone, absence of damage to the disk spaces, and vertebral bodies and spread of the disease *via* a subperiosteal and subligamentous path,<sup>[11]</sup> paraspinous extension, and, particularly, involvement of a contiguous rib.<sup>[11]</sup> Although CT allows precise assessment of osseous lesions and clearly depicts hydatid cyst calcification, MR imaging is superior in demonstrating involvement of neural structures. Hydatid cysts have an almost unique appearance on MRI.<sup>[12]</sup> They have a sausage-like shape with two dome-shaped ends and no debris in the lumen. Occasionally they are spherical. Their walls are very thin and regular with no septation. Extradurally they are always multiple and involve the bone. Intradurally they may be single or multiple. On T1-weighted images, the cyst wall may be isointense or give slightly lower signal than its contents, and T2-weighted images demonstrates a low-intensity rim surrounding the homogeneous high-signal

cyst content. The cyst wall demonstrates the slight contrast enhancement.<sup>[13]</sup> Braithwaite and Lees have classified this disease into 5 types:<sup>[11]</sup> 1) primary intramedullary hydatid cyst; 2) intradural extramedullary hydatid cyst; 3) extradural intraspinal hydatid cyst; 4) hydatid disease of the vertebrae; and 5) paraspinal hydatid disease. The treatment of choice is surgical excision for neural decompression, and establishing diagnosis.<sup>[8]</sup> Albendazole is the preferred antihelminthic agent in the treatment of hydatid disease; preoperative use of albendazole in echinococcus infestations reduces risk of recurrence, and/or facilitates surgery by reducing intracystic pressure,<sup>[14]</sup> but the duration of treatment is controversial.<sup>[14]</sup> Despite optimal and medical therapy, recurrence rate is high and thus repeat surgeries are generally needed.<sup>[15]</sup> Overall recurrence rate of 30-40%<sup>[16]</sup> and a 50% recurrence rate after posterior decompression alone are reported.<sup>[16]</sup>

## Conclusion

Spinal echinococcosis is one of the differential diagnosis of spinal cord compression syndrome especially in endemic areas. Surgical decompression is the treatment of choice but surgery alone is not curative. Adjuvant drug therapy as well as intraoperative prophylaxis are indicated. Despite all measures, the disease has high recurrence rates and leads to progressive destruction of the vertebral column and neurological deterioration. In spite of aggressive surgical and medical treatment overall outcome is still poor.

## References

- Abbassioun K, Amirjamshidi A. Diagnosis and management of hydatid cyst of the central nervous system: Part 2: Hydatid cysts of the skull, orbit, and spine. *Neurosurg Q* 2001;11:10-6.
- Turgut M. Hydatid disease of the spine: A survey study from Turkey. *Infection* 1997;25:221-6.
- Song X, Liu D, Wen H. Diagnostic pitfalls of spinal echinococcosis. *J Spinal Disord Tech* 2007;20:180-5.
- Işlekel S, Erşahin Y, Zileli M, Oktar N, Oner K, Ovül I, et al. Spinal hydatid disease. *Spinal Cord* 1998;36:166-70.
- Patel D, Shukla D. Back bugged: A case of sacral hydatid cyst. *J Neurosci Rural Pract* 2010;1:43-5.
- Herrera A, Martinez AA, Rodriguez J. Spinal hydatidosis. *Spine (Phila Pa 1976)* 2005;30:2439-44.
- Papanikolaou A. Osseous hydatid disease. *Trans R Soc Trop Med Hyg* 2008;102:233-8.
- Berk C, Ciftci E, Erdogan A. MRI in primary intraspinal extradural hydatid disease: Case report. *Neuroradiology* 1998;40:390-2.
- Dogra PN, Nabi G. Sacral hydatid cysts: An uncommon cause of neurogenic bladder. *Urol Int* 2000;65:214-5.
- Kotil K, Tatar T, Bilge T. Spinal hydatidosis accompanied by a secondary infection: Case report. *J Neurosurg Spine* 2007;6:585-90.
- Braithwaite PA, Lees RF. Vertebral hydatid disease: Radiological assessment. *Radiology* 1981;140:763-6.
- Fahl M, Haddad F, Huballah M, Kana'an S, Husheimi I, Azizi T. Magnetic resonance imaging in intradural and extradural spinal echinococcosis. *Clin Imaging* 1994;18:179-83.
- Von Sinner W, Strake L, Clark D, Sharif H. MR imaging in hydatid disease. *AJR Am J Roentgenol* 1991;157:741-5.
- Garcia-Vicuna R, Carvajal I, Ortiz-Garcia A, Lopez-Robledillo JC, Laffon A, Sabando P. Primary solitary Echinococcosis in cervical spine: Postsurgical successful outcome after long-term albendazole treatment. *Spine (Phila Pa 1976)* 2000;25:520-3.
- Fares Y, Khazim R, El Zaatari MM, Haddad GF, Barnes PR. Spinal hydatid disease and its neurological complications. *Scand J Infect Dis* 2003;35:394-6.
- Turtas S, Viale ES, Pau A. Long-term results of surgery for hydatid disease of the spine. *Surg Neurol* 1980;13:468-70.

**How to cite this article:** Ashraf A, Kirmani AR, Bhat AR, Sarmast AH. A rare case of recurrent primary spinal echinococcosis. *Asian J Neurosurg* 2013;8:206-8.

**Source of Support:** Nil, **Conflict of Interest:** None declared.