

## CASE REPORT

# Schwannomatous components in a recurrent lipomyelocele: Report of a rare case

Santosh Kumar Mondal

Department of Pathology, Medical College, 88 College Street, Kolkata, West Bengal, India

## ABSTRACT

Congenital lipomatous malformations of spinal cord constitute a diverse group of lesions and lipomyelocele is one of them. Here, we report a case of congenital lipomyelocele in a male child who presented at 7 years of age. Magnetic resonance imaging (MRI) revealed a lesion in lumbosacral region. The patient was operated and histologic examination diagnosed the case to be lipomyelocele. But after 8 years, recurrence of the lesion occurred and MRI revealed the lesion at the same location. This time histologic examination detected another new component (schwannomatous areas) in the lesion. The child was on 1-year follow-up which was uneventful.

**Key words:** Lipomyelocele, recurrence, schwannoma, spinal cord

## Introduction

Congenital spinal lipomatous lesions constitute a diverse group of malformations. There is much confusion in the literature regarding their terminology and a proper classification is needed. Recently, it has been classified by Muthukumar into two groups.<sup>[1]</sup> Group I consists of lipomas without dural defect. The lesions in this group are intramedullary lipoma, caudal lipoma without dural defect, and filum lipoma. Group II consists of lipomas with dural defect. Included in this group are caudal lipoma with dural defect, dorsal lipoma, transitional lipoma, lipomyelocele, and lipomyelomeningocele. Lipomyelocele is an intraspinal lipoma which is tightly attached to the dorsal surface of an open spinal cord and spina bifida.<sup>[2]</sup> Unlike the lipomyelomeningocele in which the thecal sac herniates through spina bifida, lipomyelocele confines within spinal canal.

## Case Report

A 7-year-old male child presented with low back pain and difficulty in walking for last 6 months in 2003. The child had malaise, but without any neurologic deficits. Magnetic

resonance imaging (MRI) revealed a lipomatous tumor at L<sub>4</sub>-L<sub>5</sub> and L<sub>5</sub>-S<sub>1</sub> intervertebral disc. The patient was operated under general anesthesia and the specimen was sent for histopathologic examination. Microscopic examination of the resected specimen confirmed a diagnosis of lipomyelocele.

The patient was followed up subsequently. At first, the patient was followed up at 3 months interval for 2 years and then at 6 months interval. During the follow-up period, in the year 2011, after 8 years of first operation, the patient again complained of low back pain and difficulty in walking. MRI examination revealed a lipomatous tumor at the previous location [Figure 1]. Mild bulge of L<sub>4</sub>-L<sub>5</sub> and L<sub>5</sub>-L<sub>5</sub>-S<sub>1</sub> intervertebral disc was seen causing slight pressure on thecal sac and existing perineural fat planes. Evidence of laminectomy was seen involving sacral segment as a sign of previous operation. The patient was operated again under general anesthesia and the resected specimen was sent for histopathologic examination. Microscopic examination revealed admixture of neural elements of spinal cord and fatty areas [Figure 2]. Focal area was showing features of schwannoma with hypocellular and hypercellular areas and Verocay bodies [Figure 3]. Thus, a histologic diagnosis of lipomyelocele with schwannomatous component was made.

The patient was on follow-up for 1 year. During this period, he was symptom free and no recurrence occurred.

## Discussion

Congenital spinal lipomatous malformations constitute a heterogeneous entity and are broadly classified into two groups depending on the presence or absence of dural defect.<sup>[1]</sup> Spinal cord development occurs through the three consecutive periods in early embryogenesis: Firstly, the

### Access this article online

#### Quick Response Code:



#### Website:

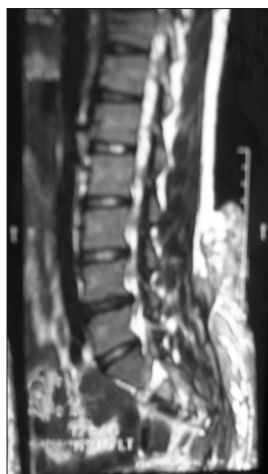www.asianjns.org

#### DOI:

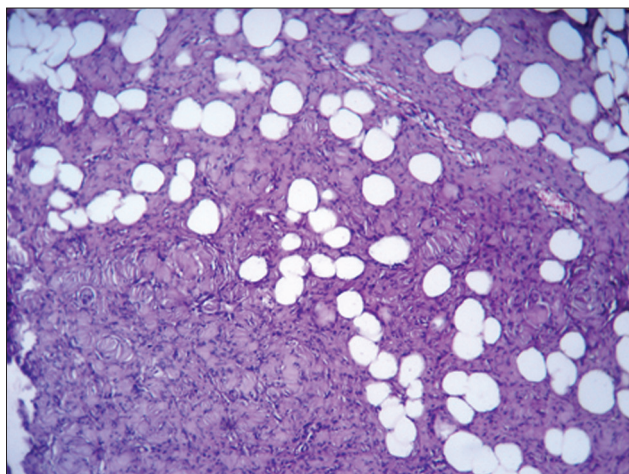
10.4103/1793-5482.125676

### Address for correspondence:

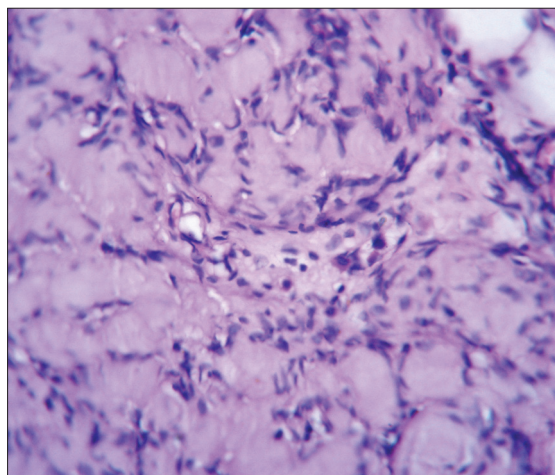
Dr. Santosh Kumar Mondal, "Teenkanya Complex," Flat 1B, Block B, 204 R. N. Guha Road, Dum Dum, Kolkata – 28, West Bengal, India.  
E-mail: dr\_santoshkumar@hotmail.com



**Figure 1:** Sagittal T1-weighted magnetic resonance image showing lipomyelocele in the lumbosacral region and disruption of the overlying bony elements



**Figure 2:** Photomicrograph showing admixture of neural and fat elements in lipomyelocele. A schwannomatous component is also evident in left lower region (H and E  $\times 100$ )



**Figure 3:** Photomicrograph showing compact groups of spindle-shaped cells with eosinophilic cytoplasm in the center and palisaded nuclei at periphery (Verocay bodies) in schwannomatous component (H and E  $\times 400$ )

gastrulation period (weeks 2-3), then primary neurulation period (weeks 3-4), and lastly secondary neurulation period (weeks 5-6). Malformations of spinal cord occur due to defects in these three early embryonic stages and are collectively known as spinal dysraphisms.<sup>[3]</sup> Clinically, it may be classified into open and closed spinal dysraphisms, based on whether the abnormal neuronal tissue is exposed to the environment or covered by skin. Open spinal dysraphisms constitute myelomeningocele and other rare abnormalities like hemimyelocele, hemimyelomeningocele, and myelocele which are almost always associated with Chiari II malformation. Closed spinal dysraphisms include lipomyelocele, lipomyelomeningocele, meningocele, myelocystocele, filar and intradural lipomas, etc.

Lipomyeloceles are benign tumors and are associated with tethering of the cord but not with malignancy.<sup>[4]</sup> However, rarely malignant transformation may occur in lipomyelocele. O'Connell *et al.* described lipomyelocele in a 3-month-old male child, which later on transformed into rhabdomyosarcoma when the baby was 3 years of age and was under follow-up.<sup>[2]</sup> The authors suggested that development of rhabdomyosarcoma in that rare case might be embryonal in origin.<sup>[2]</sup> Rarely, other mature tissue such as bone may be present with lipomatous component of lipomyelocele. Zuppani *et al.* reported one such rarest malformation in an 8-year-old girl and the authors preferred to call it as dysraphic hamartoma.<sup>[5]</sup> The case reported here was detected when the patient was 7 years old. Unlike most of the reported cases of lipomyelocele in the literature, we found schwannomatous component in our case. But malignant component or hamartomatous element was absent in our case.

According to Muthukumar's proposed classification of congenital spinal lipomatous malformation, treatment modalities are different in these two groups.<sup>[1,6]</sup> Surgery in Group I is straightforward and consists of sectioning of the filum in filum lipomas, and debulking and untethering in caudal lipomas. Duroplasty is usually not required. But in Group II, duroplasty is required in most of the cases.<sup>[6]</sup> Neurologic deficit and CSF leak are commoner in Group II patients than in Group I patients. In our case, duroplasty was done during the operation. But neurologic deficit and CSF leak were not detected. Spinal bifida in lipomyelocele is due to failure of the neural arch to close during early embryogenesis, which results in herniation of meninges or neural elements.<sup>[7]</sup> As the surgical techniques have advanced, the number of surviving children with lipomyelocele has dramatically improved.<sup>[8]</sup>

Our case is unique as the lesion recurred after 8 years which is not so common and secondly due to the presence of a schwannomatous component along with lipomyelocele in the recurrent lesion.

## References

1. Muthukumar N. Congenital spinal lipomatous malformations: Part I—Classification. *Acta Neurochir (Wien)* 2009;151:179-88.
2. O'Connell AM, Allcutt D, Brett F, Ryan S. Malignant transformation of a lipomyelocele into a rhabdomyosarcoma? *AJNR Am J Neuroradiol* 2008;29:434-5.
3. Rossi A, Cama A, Piatelli G, Ravegnani M, Biancheri R, Tortori-Donati P. Spinal dysraphism: MR imaging rationale. *J Neuroradiol* 2004;31:3-24.
4. Rossi A, Biancheri R, Cama A, Piatelli G, Ravegnani M, Tortori-Donati P. Imaging in spine and spinal cord malformations. *Eur J Radiol* 2004;50:177-200.
5. Zuppani HB, GuedesBde V, de Silva CJ, da Rocha AJ. Lipomyelocele with osseous dysraphicharmartoma in a child: A care report. *J Pediatr Orthop B* 2010;19:382-4.
6. Muthukumar N. Congenital spinal lipomatous malformations: Part II—Clinical presentation, operative findings and outcome. *Acta Neurochir (Wien)* 2009;151:189-97.
7. Ardon H, Plets C, Sciôt R, Calenbergh FV. Paraganglioma of the cauda angina region: A report of three cases. *Surg Neurol Int* 2011;2:96.
8. Thompson MD, Vasdev GM, Findlay JY. Epidural blockade for labor and cesarean section with associated L4-5lipomyelocele. *Anesthesiology* 1999;90:1217-8.

**How to cite this article:** Mondal SK. Schwannomatous components in a recurrent lipomyelocele: Report of a rare case. *Asian J Neurosurg* 2013;8:199-201.

**Source of Support:** Nil, **Conflict of Interest:** None declared.