

CASE REPORT

Giant orbital oncocytoma

 Rebecca J. Limb, Jeffrey V. Rosenfeld², Catriona McLean¹

 Departments of Neurosurgery, ¹Anatomical Pathology, The Alfred Hospital, ²Department of Surgery, Monash University, Melbourne, Australia

ABSTRACT

Background and Importance: Oncocytomas are rare benign tumours often arising from the lacrimal or salivary glands, usually small in size.

Clinical Presentation: We report a giant unilateral orbital oncocytoma in a 19-year-old male from Papua New Guinea, presenting with progressive proptosis-threatening vision. Due to retro-ocular extension of the lesion, surgical excision was performed via a fronto-orbitozygomatic craniotomy and orbitotomy. A sub-total excision of the lesion was achieved, with overall improvement in proptosis and cosmesis.

Conclusion: This appears to be the first documented case of a giant intra-orbital oncocytoma being resected neurosurgically via craniotomy.

Key words: Ocular, oncocytoma, orbitozygomatic craniotomy

Introduction

Oncocytoma is a rare pathological finding in lesions of the head and neck. It is generally accepted to be benign and slow-growing in nature, often arising from salivary or lacrimal glands, or rarely thyroid and parathyroid tissue.^[1] Complete surgical excision where possible can be curative. Orbital oncocytoma usually arises in the orbital adnexa, in the region of the caruncle, deriving from accessory lacrimal tissue.^[1] This subgroup tend to be small and superficial lesions which are easily accessible to the ophthalmic surgeon. We report an unusual case of a giant intra-orbital oncocytoma, successfully treated via craniotomy and orbitotomy.

Case Report

A 19-year-old male from Papua New Guinea (PNG) presented with the long-standing complaint of left-sided proptosis which had slowly progressed over a period of 10 years. Visual acuity was preserved although lid retraction due to the degree of

exophthalmos was causing exposure keratitis which could become sight-threatening. Computed tomography (CT) scan of the brain and orbits in PNG identified the cause to be a large soft tissue mass which was retro-ocular but entirely confined to the left orbit. The patient could not be treated in PNG and was subsequently referred to a tertiary hospital in Melbourne, Australia, for further assessment and specialist surgical treatment. On clinical examination, visual acuity was found to be 6/12 in the left eye and 6/5 in the right eye. Range of movement in the left eye was well preserved with very slight limitation of upward and downward gaze [Figure 1]. The cranial nerves were intact, Humphrey visual field testing revealed no deficit, and fundoscopy was unremarkable with normal appearances of the optic discs bilaterally.

Magnetic resonance (MR) imaging of the brain and orbits demonstrated the lesion to be non-enhancing, multi-cystic, both intra- and extra-conal and infiltrating the left superior and inferior rectus muscles. The optic nerve was displaced by the mass but there was no radiological evidence of intracranial extension [Figures 2 and 3]. The most likely diagnosis based on the radiological findings was lymphangioma, oncocytoma was not considered. Surgical excision of the lesion was indicated to correct proptosis, reverse the corneal irritation, preserve vision and to obtain histology. Due to the retro-ocular location of the lesion, the planned approach was via a left fronto-orbitozygomatic craniotomy to maximize access and reduce the likelihood of injury to the globe and associated structures.

Intraoperatively, the cystic mass was found to be diffusely infiltrating the superior and inferior recti, with no plane between tumour and normal tissue. Identification of the divisions of the oculomotor nerve and the abducens nerve was

Access this article online	
Quick Response Code:	Website: www.asianjns.org
	DOI: 10.4103/1793-5482.125668

Address for correspondence:

Dr. Rebecca J. Limb, Department of Neurosurgery, Level 1 Old Baker Building, The Alfred Hospital, Commercial Road, Prahran VIC 3004, Australia. E-mail: r.limb@alfred.org.au

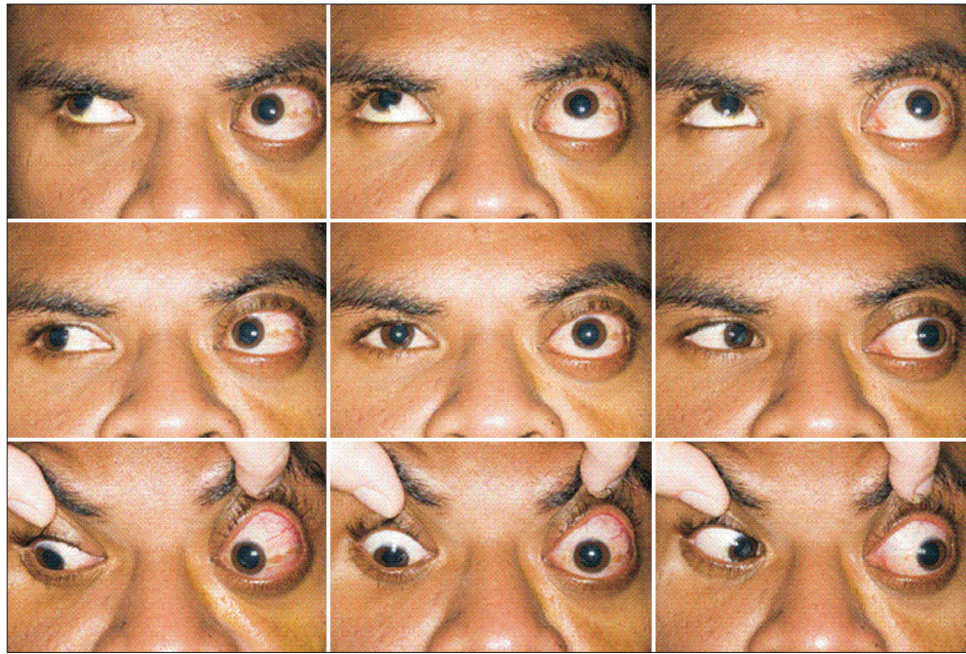
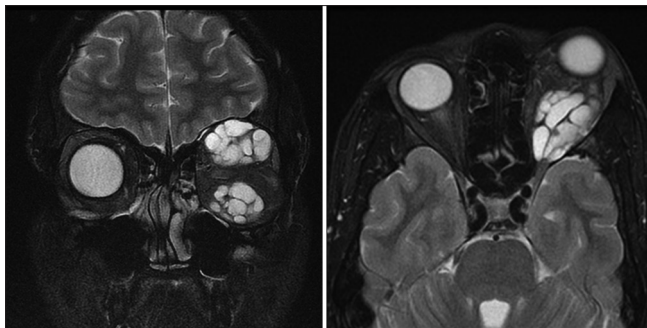


Figure 1: Clinical photograph demonstrating left proptosis and lid retraction, mild limitation of upward and downward gaze



Figures 2 and 3: T2-weighted coronal and axial MR imaging of the cystic left intra-orbital oncocyoma

impossible due to the grossly distorted orbital anatomy and infiltrating tumour. The intraconal portion of the lesion was adherent to the optic nerve, displacing it laterally. The cystic elements containing a milky, turbid fluid were opened and the intraconal tumour was extensively debulked. A sub-total excision of the lesion was obtained.

Post-operatively, there was initially significant periorbital swelling which improved rapidly. Formal ophthalmological review 11 days post-operatively revealed a dramatic improvement in the degree of exophthalmos although there was a complete ptosis possibly indicating deficit of the superior division of the oculomotor nerve, as well as a complete left lateral rectus palsy. Visual acuity remained unchanged.

At 1-month post-operatively, the previously noted ptosis and ophthalmoplegia remained unchanged with mild intortion of the eye in a resting state although acuity remained preserved. Delayed surgical correction of the ptosis and strabismus may be indicated in the future.

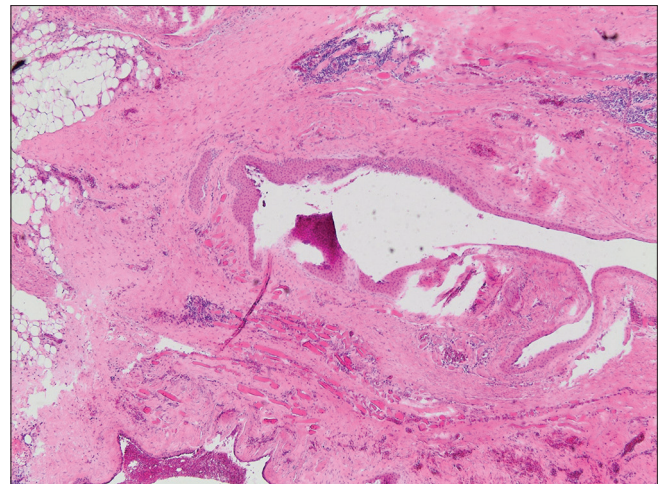


Figure 4: Haematoxylin and eosin x40 – Cystic tumour within connective tissue lined by a bilayered oncocytic epithelium showing no cytologic atypia

Histological findings demonstrated fibrous connective tissue with multiple cystic spaces lined with a bi-layered cuboidal epithelium. Some fragments of normal lacrimal gland were also identified. The histological features were felt to be most consistent with a benign cystic oncocyoma, arising from the lacrimal gland [Figure 4].

Discussion

There are no reports in the literature of an intra-orbital oncocyoma of this size being resected neurosurgically via craniotomy. In addition, recent case series and case reports of ocular oncocytomas indicate that these lesions are usually much smaller and located more superficially within the orbital region.^[2,3] However, given its size and the degree of posterior

intra-orbital extension such an aggressive surgical debulking would not have been possible via an alternative approach (i.e., lateral orbitotomy). This is an unusual example of a rare although benign ocular lesion posing a significant threat to vision and cosmesis, with a primarily neurosurgical solution.

References

1. Biggs SL, Font RL. Oncocytic lesions of the caruncle and other ocular adnexa. *Arch Ophthalmol* 1977;95:474-8.
2. Ostergaard J, Prause J. Oncocytic lesions of the ophthalmic region: A clinicopathological study with emphasis on cytokeratin expression. *Acta Ophthalmol* 2011;89:263-7.
3. Say EA, Shields CL, Bianciotto C, Eagle RC Jr, Shields JA. Oncocytic Lesions (Oncocytoma) of the ocular adnexa: Report of 15 cases and review of literature. *Ophthal Plast Reconstr Surg* 2012;28:14-21

How to cite this article: Limb RJ, Rosenfeld JV, McLean C. Giant orbital oncocytoma. *Asian J Neurosurg* 2013;8:192-4.

Source of Support: Nil, **Conflict of Interest:** None declared.