

CASE REPORT

Grave's disease with transverse and sigmoid sinus thrombosis needing surgical intervention

Banumathy Srikant, Srikant Balasubramaniam¹Department of General Medicine, ESIC Model Hospital, Andheri, ¹Department of Neurosurgery, BYL Nair Hospital, Mumbai, India

ABSTRACT

Thrombosis of venous sinuses associated with thyrotoxicosis is rare, and isolated transverse and sigmoid sinus thrombosis is rarer and reported only once previously. We present a case of Graves disease, who suffered unilateral sigmoid and transverse sinus thrombosis with intracranial hemorrhage. A 42-year-old female, a diagnosed case of Graves disease, presented to us with headache, drowsiness, and hemiparesis. Computed Tomography revealed a large right temporo-parieto-occipital venous infarct. The patient needed surgical intervention in the form of decompressive craniotomy following which she improved, and on follow-up is having no deficits. Thrombophilia profile showed a low Protein S and Anti thrombin III (AT III) levels. Deranged thrombophilia profile in combination with the hypercoagulable state in thyrotoxicosis, most likely precipitated the thrombotic event. Timely surgical intervention can be offered in selective cases with a good clinical outcome.

Key words: Cerebral sinus thrombosis, decompressive craniotomy, factor S deficiency, graves disease, thyrotoxicosis

Introduction

Thrombosis of venous sinuses associated with thyrotoxicosis is rare.^[1,2] There have been few reported cases of superior sagittal sinus thrombosis associated with thyrotoxicosis in literature, but isolated transverse and sigmoid sinus thrombosis in a case of thyrotoxicosis has been reported only once previously and ours is the second such report.^[3] We present a case, who had suffered unilateral sigmoid and transverse sinus thrombosis with intracranial hemorrhage. Unlike previously reported cases which were treated by thrombolysis, our case needed surgical intervention in the form of decompressive craniotomy. The case details, possible pathogenesis, and treatment modalities have been discussed in this paper.

Case Report

A 42-year-old female, a diagnosed case of Graves disease, was on treatment for thyrotoxicosis. Her thyroid profile was as mentioned in Table 1. She was on Tab. Neomercazole 10 mg

tds and Tab. Propranolol 10 mg tds. Serum Anti Microsomal Antibody (AMA) and Anti Nuclear Antibodies (ANA) levels were negative. Ultrasound (USG) thyroid showed increased size of both lobes of thyroid suggestive of goiter. Radio isotope thyroid uptake study showed a 33.6% thyroid uptake of ^{99m}TcO₄ (Normal 1-4%) suggestive of multinodular goiter with increased trapping function. Her thyroid hormone levels were controlled on anti thyroid medications.

She presented to us with headache, drowsiness, and decreased ability to move the left side of her body since three days. Computed Tomography (CT) of the brain showed a large right sided parietoccipital hypodense region with areas of hyperdensity suggestive of venous infarct with hemorrhagic transformation [Figure 1]. A right temporo-parietal craniotomy was performed. On opening the dura the brain was seen to be tense. A lax duroplasty was performed. Post-operatively, she was ventilated electively for 48 hours and then extubated. There were no added neurological deficits. She was given intravenous Mannitol 100 cc 8 hourly (for 3 days), Phenytoin Sodium 100 mg 8 hourly, along with other pre operative medicines. Three days (72 hours) after the surgery, she was started on injection Enoxaparin 0.6 mg subcutaneously 12 hourly for 6 days followed by Tab. Aspirin 150 mg once a day for 6 months.

Post operative CT scan performed after five days showed an organized infarct in the right parieto occipital region with no midline shift [Figure 2]. Magnetic Resonance Imaging (MRI) performed three weeks after the surgery showed well defined areas of altered signal intensity involving grey and white matter in right parieto occipital region with gyriform

Access this article online

Quick Response Code:



Website:
www.asianjns.org

DOI:
10.4103/1793-5482.121690

Address for correspondence:

Dr. Srikant Balasubramaniam, 202/A, Swapna Mahal, Swapna Nagari, Mulund (W), Mumbai – 400 080, India.
E-mail: srikantbala@yahoo.com

Table 1: Serial thyroid profile at 2 weekly intervals with the normal values mentioned in the bracket

Sr. No.	T3 (ng/dl)	T4 (µg/dl)	Free T3 (pg/ml)	Free T4 (ng/dl)	TSH (µIU/ml)
1	-	-	>4 (1.4- 4.4)	> 20 (0.8-2.7)	0.0 (0.5- 4.7)
2	-	13.0 (4.5-10.9)	-	-	0.06 (0.5- 4.7)
3	-	4.9 (4.5-10.9)	-	-	0.38 (0.5- 4.7)
4	-	7.3 (4.5-10.9)	-	-	1.0 (0.5- 4.7)
5	-	-	2.4 (1.4- 4.4)	0.86 (0.8-2.7)	1.7 (0.5- 4.7)
6	102.2 (60-181)	5.2 (4.5-10.9)	-	-	1.27 (0.5- 4.7)

and adjacent dural enhancement [Figure 3]. Magnetic Resonance Venography (MRV) showed absent signals in right transverse and sigmoid sinus suggestive of thrombosis of these sinuses.

She gradually improved in her power in left sided limbs. At three months follow-up, the power in all four limbs was grade 5/5. Delayed (6 months post operative) MRV showed partial recanalization of the right transverse and sigmoid sinuses with evidence of collaterals [Figure 4]. These sinuses were opacified on post contrast images as well.

Her thrombophilia profile which was sent on admission indicated low levels of Protein S and Antithrombin (AT) III. Other parameters were normal [Table 2].

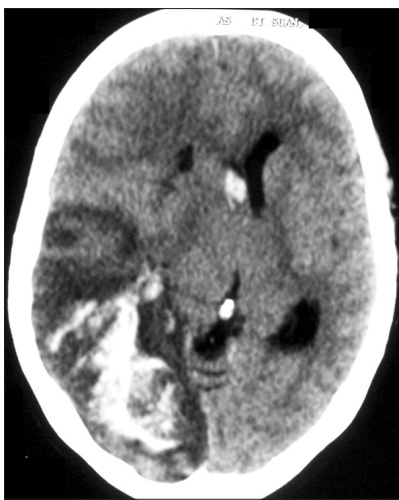

Figure 1: Plain axial CT scan shows a large right sided temporo-parieto-occipital hypodense area with foci of hyper attenuation within, suggestive of hemorrhagic transformation. The right lateral ventricle is effaced and there is evidence of subfalcine herniation and midline shift

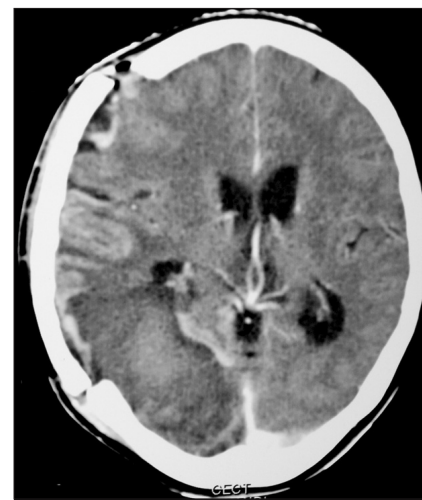

Figure 2: Post contrast axial CT scan on post operative day 5 showing extensive leptomeningeal and peripheral enhancement of the infarct. The mass effect has decreased but the occipital horn is still mildly effaced

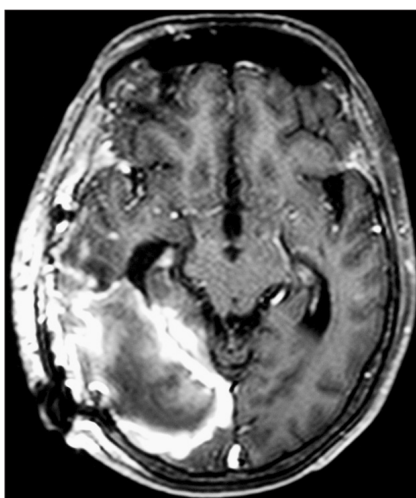


Figure 3: MRI 3 weeks after surgery showing peripheral and gyriform enhancement in the area of venous infarct. The infarct is well matured and there is no mass effect

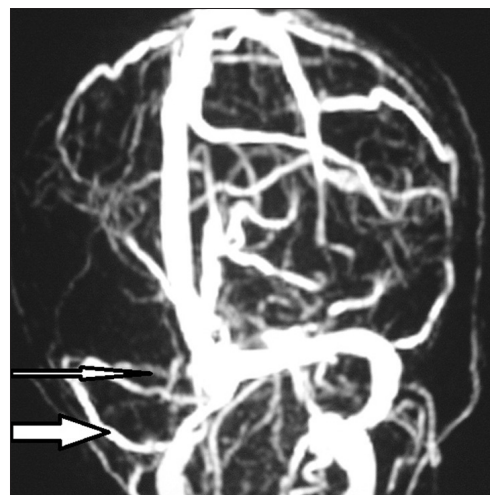


Figure 4: Delayed MR venography (6 months post op) showing recanalization of right sigmoid and transverse sinus with development of significant collaterals. The longer, thinner arrow shows the collaterals and the shorter, stouter arrow indicates the recanalized sigmoid sinus

Discussion

Cerebral sinus thrombosis is an uncommon cause of stroke.^[2] Superior sagittal, transverse and sigmoid sinuses are the commonest involved veins.^[4] Isolated transverse and sigmoid sinus thrombosis is rarer. Headache, hemiparesis, and focal epilepsy in a relatively young patient are indicative of sinus thrombosis.^[2,5] Our patient had drowsiness, headache, and hemiparesis, but no seizure. The diagnosis is established by CT scan or magnetic resonance imaging (MRI) and confirmed by angiography (Digital Subtraction Angiography or Magnetic Resonance Angiography).^[1,2]

A wide variety of diseases may be associated with sinus thrombosis, including infectious disease and non-infectious conditions such as vasculitis, hypercoagulable states, and pregnancy.^[1,2,6,7] Erem *et al.* found in their study that Graves disease patients had increased levels of Thrombin Activatable Fibrinolysis Inhibitor (TAFI) and decreased levels of Factor V, Protein C, Protein S, and Tissue Factor Pathway Inhibitor (TFPI). They concluded that this potentiated a hypercoagulable and hypofibrinolytic state which might increase the risk of atherosclerotic and atherothrombotic complications.^[8] In our patient, there was an evidence of hypercoagulable state in the form of deficiency of Protein S and Antithrombin III. Some studies have mentioned that the presence of Protein C, Protein S, and AT III deficiency in ischemic strokes is seen in up to 23% of cases.^[9] Moster in his study, had established that all Protein S deficiency patients had elevated anticardiolipin antibodies and hence he suggested an association between Protein S deficiency and antiphospholipidic syndrome in stroke patients.^[10] A meta analysis performed by Soare *et al.* could not establish a strong link between isolated AT III deficiency and stroke.^[11]

Despite these associations, approximately 25% of the cases of sinus thrombosis are still considered to be idiopathic.^[5] In general, venous sinus thrombosis can be promoted by three factors: hypercoagulability, stasis of the blood stream, and abnormalities of the vessel wall.^[1,2] Possible predisposing factors for the development of sinus thrombosis in our patient with thyrotoxicosis are also in line with this triad. As first hypothesized by Seigert *et al.*, hypercoagulability during thyrotoxicosis and venous stasis in the goiter may promote the development of sinus thrombosis.^[2]

Previously reported cases of cerebral venous sinus thrombosis in case of thyrotoxicosis are mentioned in Table 3. Our case is different from previously mentioned cases on three counts. Firstly, all of them had been managed conservatively and ours is the first needing surgical decompression. In our case, due to acute thrombosis of the right transverse and sigmoid sinus, there was significant cerebral edema which manifested as drowsiness and limb weakness. Hence, our patient needed emergency decompressive craniotomy following which she improved significantly.

Table 2: Patient's thrombophilia profile

Profile	Patient value (%)	Normal Range (%)
Protein C level	85 %	70 – 140
Protein S level	51 %	70 – 140
AT- III level	15 %	70 – 140

Factor V Leiden mutation not detected

Table 3: Mentions previous series of conservatively managed cases of cerebral venous sinus thrombosis with thyrotoxicosis

Author, Year	No. of cases	Involvement of sinus	Thrombophilia profile
Siebert <i>et al.</i> , ^[2]	2	Superior sagittal sinus	Normal
Verberne <i>et al.</i> , ^[3]	1	Sigmoid and Transverse	Increased Factor VIII activity
Rau <i>et al.</i> , ^[1]	1	Superior sagittal sinus	Raised plasma fibrinogen; Low protein C activity
Molloy <i>et al.</i> , ^[12]	1	Superior sagittal sinus	Factor V Leiden mutation
Kasuga <i>et al.</i> , ^[13]	1	SSS and bilateral transverse sinus	Increased Factor VIII activity
Nagumo <i>et al.</i> , ^[14]	1	Superior sagittal sinus	Increased Factor VIII activity; Protein C deficiency

Even with conservative management, treatment has varied among authors from no anticoagulant to oral anticoagulants to direct thrombolysis with urokinase.^[1-3,12-14] Even though our patient was started on Low Molecular weight Heparin (Enoxaparin) followed by Aspirin, role of anticoagulant medications remain controversial because of risk of provoking hemorrhagic transformation of infarction.^[2] Secondly, ours is the first case associated with Protein S and AT III deficiency, whereas other cases have been associated with Protein C or factor VIII which was normal in our case.^[1-3,12-14] Thirdly, there were no additional co-morbid factors such as Atrial fibrillation as reported by Rau *et al.*^[1]

Conclusion

Cerebral sinus thrombosis is associated with thyrotoxicosis due to hypercoagulability and venous stasis. A high index of suspicion should be maintained in all cases of Graves disease to detect this potentially treatable condition. Cerebral sinus thrombosis can be treated conservatively if patient is neurologically stable. However, in case of neurological deterioration or deficits, timely surgical decompression provides very good results.

References

1. Rau CS, Lui CC, Liang CL, Chen HJ, Kuo YL, Chen WF. Superior sagittal sinus thrombosis induced by thyrotoxicosis. *J Neurosurg* 2001;94:130-2.
2. Siebert CE, Smelt AH, De Bruin TW. Superior sagittal sinus thrombosis and thyrotoxicosis: Possible association in two cases.

- Stroke 1995;26:496-7.
3. Verberne HJ, Fliers E, Prummel MF, Stam J, Brandjes DP, Wiersinga WM. Thyrotoxicosis as a predisposing factor for cerebral venous thrombosis. *Thyroid* 2000;10:607-10.
 4. Giancarlo A, Melina V. Epidemiology of Cerebral Vein and Sinus Thrombosis: In: Braunwald E, Editor. *Heart Disease*(4th ed) Philadelphia: W.B. Saunders; 1992. p. 1832.
 5. Bousser MG, Chiras J, Bories J, Castaigne P. Cerebral venous thrombosis: A review of 38 cases. *Stroke* 1985;16:199-213.
 6. Averbach P. Primary cerebral venous thrombosis in young adults: the diverse manifestations of an underrecognized disease. *Ann Neurol* 1978;3:81-6.
 7. Southwick FS, Richardson EP, Swartz MN. Septic thrombosis of the dural venous sinuses. *Medicine (Baltimore)* 1986;65:82-106.
 8. Erem C, Ucunco O, Yilmaz M, Kocak M, Nuhoglu I, Ersoz HO. Increase thrombin-activatable fibrinolysis inhibitor and decreased tissue factor pathway inhibitor in patients with hyperthyroidism. *Endocr* 2009;36:473-8.
 9. Bushnell CD, Goldstein LB. Diagnostic testing for coagulopathies in patients with ischemic stroke. *Stroke* 2000;31:3067-78.
 10. Moster ML. Coagulopathies and arterial stroke. *J Neuroophthalmol* 2003;23:63-71.
 11. Soare AM, Popa C. Deficiencies of Protein C, S and Antithrombin and Factor V Leiden and the risk of ischemic strokes. *J Med Life* 2010;3:235-8.
 12. Molloy E, Cahill M, O'Hare JA. Cerebral venous sinus thrombosis precipitated by Graves' disease and Factor V Leiden mutation. *Ir Med J* 2003;96:46-7.
 13. Kasuga K, Naruse S, Umeda M, Tanaka M, Fujita N. Case of cerebral venous thrombosis due to graves' disease with increased factor VIII activity. *Rinsho Shinkeigaku* 2006;46:270-3.
 14. Nagumo K, Fukushima T, Takahashi H, Sakakibara Y, Kojima S, Akikusa B. Thyroid crisis and protein C deficiency in a case of superior sagittal sinus thrombosis. *Brain Nerve* 2007;59:271-6.

How to cite this article: Srikant B, Balasubramaniam S. Grave's disease with transverse and sigmoid sinus thrombosis needing surgical intervention. *Asian J Neurosurg* 2013;8:166-9.

Source of Support: Nil, **Conflict of Interest:** None declared.