

# Success rate of endoscopic third ventriculostomy in infants below six months of age with congenital obstructive hydrocephalus (a preliminary study of eight cases)

Ahmed Z. M. Zohdi, Ahmed M. El Damaty, Khaled B. Aly, Ehab A. El Refaee

Neurosurgery Department, Kasr Al Ainy School of Medicine, Cairo University, Egypt

## ABSTRACT

**Aim:** In this study, we were assessing the outcome of Endoscopic Third Ventriculostomy (ETV) in infants below six months of age in cases of congenital obstructive hydrocephalus.

**Materials and Methods:** The study was done prospectively on eight cases of obstructive hydrocephalus in infants younger than six months of age to assess the success rate of ETV as a primary treatment for hydrocephalus in this age group; in cases of evident failure, a ventriculo-peritoneal (VP) shunt was applied.

**Results:** Despite eliminating the factors suggested as causes of ETV failure in infants below six months; the type, as with the communicating hydrocephalus, the thickness of the third ventricular floor, history of previous intracranial hemorrhage or central nervous system infection, still the success rate did not exceed 12.5%.

**Conclusions:** The complication rate following ETV was low in comparison to the high frequency (20–80%) and seriousness of the possible postoperative complications following VP shunt with a significant decrease in the quality of patients' lives. Hence the decision-making as well as the parental counselling were in a trial to estimate the ETV success or the need to perform a shunt in the treatment of obstructive hydrocephalus.

**Key words:** Congenital hydrocephalus, endoscopic third ventriculostomy, obstructive hydrocephalus, pediatric neurosurgery

## Introduction

Placement of a ventriculo-peritoneal (V-P) shunt is still the standard for management of hydrocephalus; yet shunt infection and failure are common problems. Potential risks and complications exist with shunt surgery especially among infants during their first year of life.<sup>[1-4]</sup>

Endoscopic third ventriculostomy (ETV) presents an alternative to shunt insertion. According to published data from several

groups, infants younger than one year of age have a higher failure rate for ETVs compared with older children.<sup>[5-8]</sup> The conclusion has been drawn that patients younger than one year of age are not candidates for ETV and should undergo placement of a V-P shunt instead.<sup>[9]</sup>

## Materials and Methods

The study was done prospectively in the Neurosurgery Department, Pediatric Unit of the Specialized Children University Hospital, on infants admitted in the period from September 2009 through April 2010, suffering from obstructive hydrocephalus. The study was carried out to study the success rate of ETV as a treatment for hydrocephalus in such age group, in cases of evident failure clinically by progressive head enlargement or cerebrospinal fluid (CSF) leak proved radiologically by enlargement of the ventricles and/or periventricular permeation, a V-P shunt is applied.

## Inclusion criteria

- i. Age of six months or less.
- ii. Obstructive hydrocephalus (Aqueductal stenosis).
- iii. Normal or collapsed fourth ventricle.

### Access this article online

#### Quick Response Code:



#### Website:

www.asianjns.org

#### DOI:

10.4103/1793-5482.121686

### Address for correspondence:

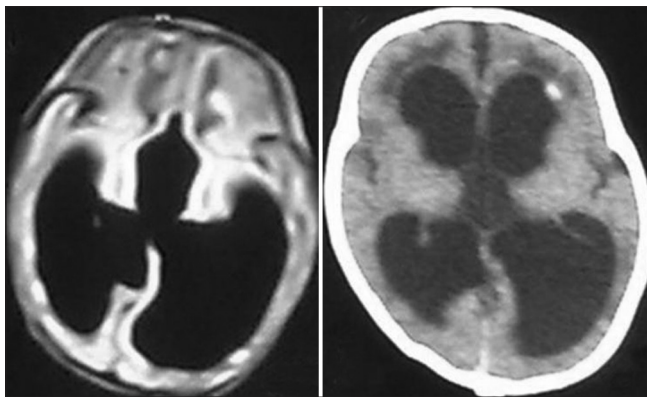
Ahmed Mostafa El Damaty, 14 AbdelRahman ElGuideily st., New Nozha, Cairo, Egypt. E-mail: ahmedeldamaty@kasralainy.edu.eg

### Exclusion criteria

- i. History of CNS infection or septicemia
- ii. History of intracranial hemorrhage
- iii. History of previous CSF diversion procedure
- iv. Associated myelomeningocele (Chiari malformation type II).

Out of 150 patients reviewed in our hospital over a period of six months, only eight patients succeeded to fulfill the highly selective inclusion criteria. With exclusion of any case with history of intracranial hemorrhage, CNS infection, previous CSF diversion or element of communicating hydrocephalus, just cases of purely congenital obstructive hydrocephalus were included. Patients were followed-up postoperatively from day 1 through day 7; then weekly assessment for 24 months of the head circumference, anterior fontanelle, CSF leak, wound infection, and fever. Control neuroimaging studies were done whenever needed.

Illustrative case 1 [Figure 1]: A female patient aged three months old presented to us by the mother's complaint of

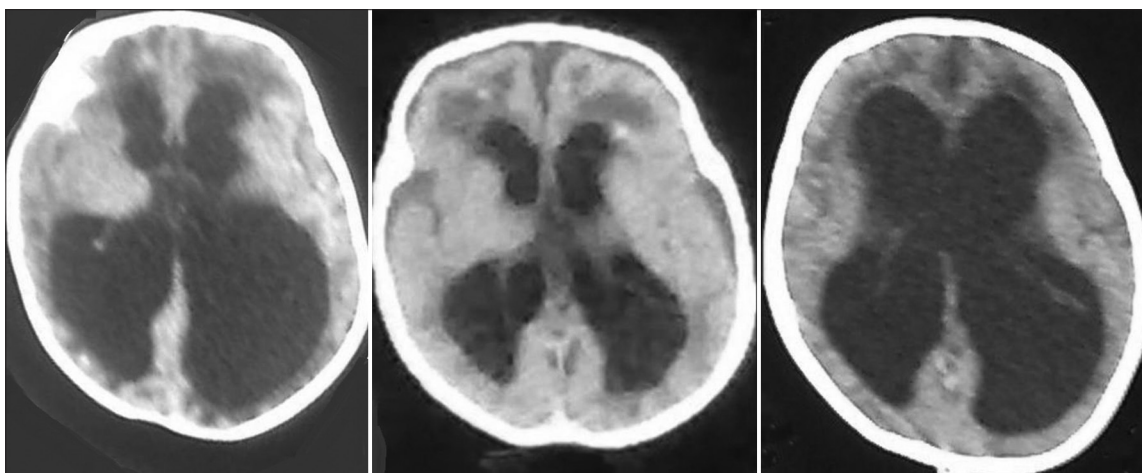


**Figure 1:** (Left) Axial T1 MRI cuts showing obstructive hydrocephalus with dilated lateral and 3<sup>rd</sup> ventricles. (Right) Control CT brain 3 weeks after ETV showing dilated 3<sup>rd</sup> ventricle and periventricular permeation denoting failure of ETV

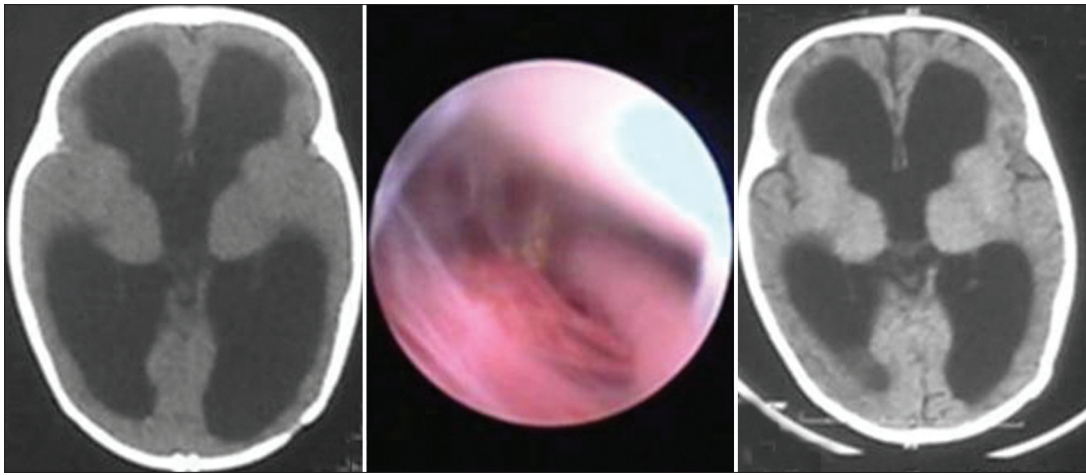
progressive head enlargement, history of preterm pregnancy and admission in incubator for three weeks due to prematurity with no reported complications, head circumference was 39.5 cm (on the 90<sup>th</sup> percentile), anterior fontanelle was 3.5 fingers wide, elevated and tense, magnetic resonance imaging (MRI) brain was done revealing triventricular hydrocephalus and Evan's ratio was 0.7. ETV was done followed by decrease in the head circumference and laxity of anterior fontanelle, during the postoperative period the condition was stable for three weeks till on the fourth week the head circumference started to re-increase and the anterior fontanelle became elevated again, control CT brain was done which revealed increased ventricular size and periventricular permeation denoting failure of ETV. Accordingly, a VP-shunt was applied on the fifth week.

Illustrative case 2 [Figure 2]: A female patient aged one month old presented to us by the mother's complaint of intrauterine diagnosis of fetal hydrocephalus, history of admission in incubator for one week due to neonatal jaundice with no reported complications, head circumference was 37.5 cm (on the 90<sup>th</sup> percentile), anterior fontanelle was 3.5 fingers wide, elevated and tense, CT brain was done revealing triventricular hydrocephalus and Evan's ratio was 0.7. ETV was done followed by decrease in the head circumference and laxity of anterior fontanelle, during the postoperative period the condition was stable for three weeks till on the fourth week the head circumference started to re-increase and the anterior fontanelle became elevated again, control CT brain was done one week and after four weeks which revealed decrease in ventricular size and periventricular permeation after one week and then re-increase in ventricular size after four weeks denoting failure of ETV. Accordingly, a VP-shunt was applied on the fourth week.

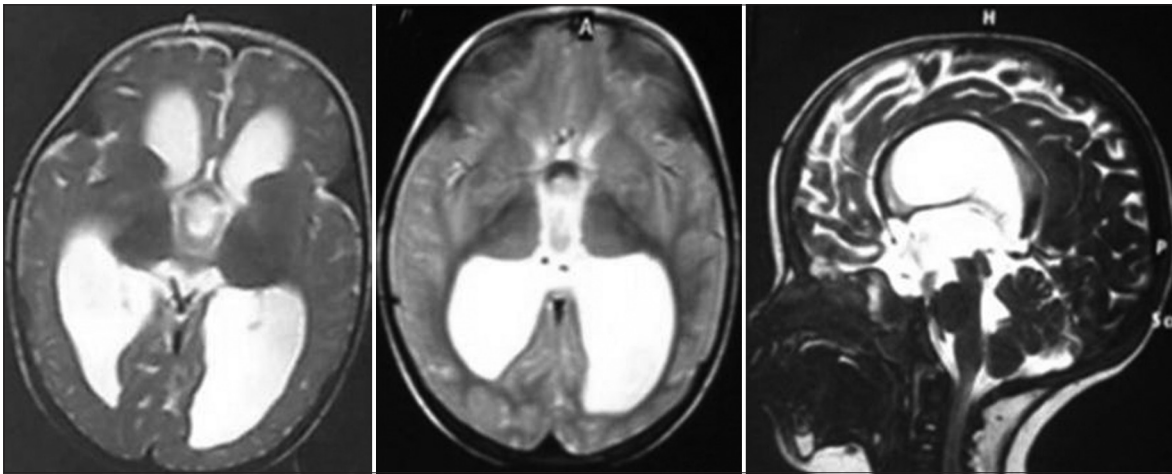
Illustrative case 3 [Figures 3 and 4]: A female patient aged four months old presented to us with the mother complaining of progressive head enlargement, head circumference was 47 cm



**Figure 2:** (Left) CT brain showing obstructive hydrocephalus with dilated lateral and 3<sup>rd</sup> ventricles. (Middle) Control CT brain after 1 week of ETV revealing decreased ventricular size and prominent subarachnoid space denoting functioning ETV. (Right) Control CT brain 4 weeks after ETV showing re-increase in ventricular size denoting failure of ETV



**Figure 3:** (Left) CT brain showing obstructive hydrocephalus with dilated lateral and 3<sup>rd</sup> ventricles. (Middle) Endoscopic view of the floor of the third ventricle after ETV showing opened Lilliequist membrane and Basilar artery. (Right) Control CT brain 1 month after ETV showing slight reduction in ventricular size with no periventricular permeation and opened subarachnoid spaces



**Figure 4:** (Left) Control MRI 3 months after ETV, axial T2 cuts showing signal void in 3<sup>rd</sup> ventricular floor. (Middle and right) Control MRI 20 months after ETV, axial and sagittal T2 cuts showing signal void in 3<sup>rd</sup> ventricular floor denoting functioning ventriculostomy

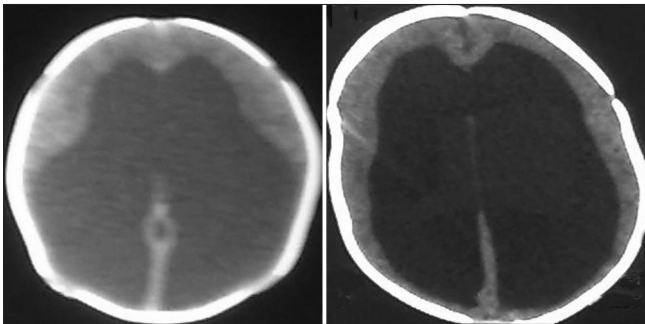
(larger than 98<sup>th</sup> percentile), anterior fontanelle had four fingers width, was elevated and tense. CT brain was done revealing triventricular hydrocephalus with Evan's ratio 0.7. ETV was done followed by decrease in head circumference and lax anterior fontanelle. During the follow-up period, the condition was stable - up till now - for a period of 24 months. Postoperatively, control CT brain after 1 month, MRI after three months followed by control CT, MRI and MRI CSF flowmetry after 20 months were done which confirmed a functioning ETV with a head circumference now 50 cm at age of two years, closed anterior fontanelle and normal developmental milestones.

Illustrative case 4 [Figure 5]: A male patient aged one month old presented to us by the mother's complaint of progressive head enlargement, history of preterm pregnancy and admission in incubator for two weeks due to prematurity with no reported complications, head circumference was 39.5 cm (on the 90<sup>th</sup> percentile), anterior fontanelle was 4 fingers wide, elevated and tense, CT brain was done revealing

triventricular hydrocephalus and Evan's ratio was 0.7. ETV was done followed by decrease in the head circumference and laxity of anterior fontanelle, during the postoperative period the condition was stable for two weeks till on the third week the head circumference started to re-increase and the anterior fontanelle became elevated again, control CT brain was done which revealed increased ventricular size and periventricular permeation denoting failure of ETV. Accordingly, a VP-shunt was applied on the third week.

## Results

ETV was done in eight cases only of obstructive hydrocephalus due to congenital aqueductal stenosis that were fulfilling the highly selective inclusion criteria out of 150 patients with obstructive hydrocephalus managed in our hospital, their age was ranging from one to six months with no apparent history of previous CNS infection or septicemia as a primary treatment for their disease. It was successful in controlling the disease



**Figure 5:** (Left) CT brain showing obstructive hydrocephalus with dilated lateral ventricles. (Right) Control CT brain 2 weeks after ETV showing redilatation of the lateral ventricles with obliterated subarachnoid space denoting failure of ETV

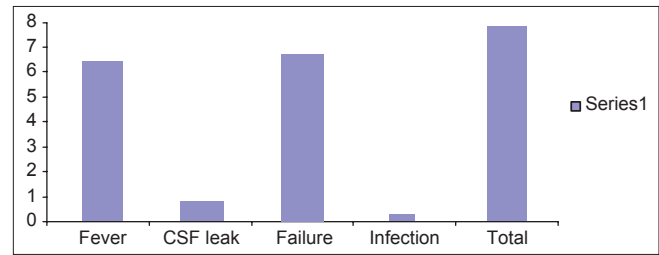
clinically and radiologically in one case only, during a follow-up period of 24 months after the procedure. Seven cases suffered from fever on the same day of the procedure and the next day only. One case had CSF leakage five days after the procedure and was considered a sign of failure; accordingly VP-shunt was applied. Failure occurred within a period ranging from one week through six weeks with an average of 3.29 weeks. No cases of CNS infection as a complication of the procedure were detected. There was one mortality case after failure of ETV and applying a V-P shunt due to associated cardiac anomaly (atrial and ventricular septal defects) [Figure 6], [Table 1].

The only successful case was the fifth one in order and no other single case of success was detected till the eighth case, then we decided to stop the series and report this failure rate despite the highly selective inclusion criteria and our aim at a better success rate. We decided to counsel the parents of the next coming cases and inform them about the low success rate we have achieved so far. Hence, most of the parents refused the ETV and preferred to apply a VP shunt directly.

## Discussion

Shunt placement, due to its effectiveness in the early postoperative period, has become a widespread method of treating both obstructive and non-obstructive hydrocephalus. However, the high frequency (20-80%) and seriousness of postoperative complications lead to a significant decrease in the quality of patients' lives. Each of these complications requires at least one surgical procedure for its treatment and can cause significant morbidity and mortality.<sup>[10,11]</sup> Treatment of this morbid condition remains an unsolved problem in neurosurgery.

There have been several studies of the effectiveness of ETV in children under two years of age. Kadrian *et al.* reported a strong effect of patient age on outcome.<sup>[12]</sup> They reported that the reliability of ETV in infants younger than one month was extremely low. The maximum observed reliability of ETV in this group was 3.5 years. The authors reported the percentages of patients "presumed to have a functioning ETV after five



**Figure 6:** Bar chart showing incidence of complications in relation to total no. of cases

**Table 1: summary of 8 patients**

Case	Age	Diagnosis	Follow-up	Fever	CSF leak	Outcome	Mortality
1	3 m	Aqueductal stenosis	4 weeks	Yes	No	Failure	No
2	3 m	Aqueductal stenosis	1 week	Yes	No	Failure	No
3	2 m	Aqueductal stenosis	4 weeks	Yes	No	Failure	No
4	4 m	Aqueductal stenosis	2 weeks	Yes	No	Failure	No
5	4 m	Aqueductal stenosis	24 months	Yes	No	Success	No
6	2 m	Aqueductal stenosis	6 weeks	No	No	Failure	No
7	1 m	Aqueductal stenosis	4 weeks	Yes	No	Failure	No
8	1 m	Aqueductal stenosis	2 weeks	Yes	Yes	Failure	Cardiac failure

years" as follows: 41% in patients one to six months old at the time of surgery, 58% in patients 6 to 24 months old, and more than 70% in patients older than 24 months. These results correspond to the data reported by other authors.<sup>[13]</sup>

However, Javadpour *et al.*<sup>[14]</sup> reported an ETV success rate of 33% (continued patency during follow-up in 7 of 21 patients) and found that success depended on etiology rather than on patient age.

Baldauf *et al.*<sup>[15]</sup> - the most similar study to ours, but with less selective inclusion criteria - The series consisted of 21 patients collected over a period of 10 years treated with ETV. The mean age of the patients was 6.7 months, ranging from 9 days to 15 months (16 patients were younger than 1 year). The study included hydrocephalus due to idiopathic aqueductal stenosis (eight) and other congenital anomalies (four) as well as posthemorrhagic (three) and tumor-related occlusive hydrocephalus (three). Two patients presented with shunt infection and one with a shunt failure. ETV was considered to be successful when shunting could be avoided. They reported that ETV was successful in nine patients, with a mean follow-up period of 26.2 months. The procedure was successful in four patients with idiopathic aqueductal stenosis - success rate with such etiology was 50% -, in two

with other congenital anomalies, in one posthemorrhagic, and in two with a tumor-related hydrocephalus. In 12 patients, the ETV was unsuccessful after a mean follow-up of 3.3 months. These patients required a shunt. Ten of them were less than one year old when ETV was performed. In one tumor-related hydrocephalus, a shunt was inserted after meningitis after tumor removal. They concluded that the success of ETV in children younger than two years of age suffering from non-communicating hydrocephalus seems to be dependent on both age and etiology. Their results show an overall success rate of 43%. In 37.5% of the children younger than 1 year of age, ETV was successful. ETV in patients with hydrocephalus due to idiopathic aqueductal stenosis seems to be more beneficial than in other causes of hydrocephalus.

Analysis of the success and failure of ETV in infants in the Netherlands confirmed that ETV should be considered as an initial treatment that carries a low risk of morbidity in these infants. As the immune system rapidly matures, postponing shunt implantation for several months or even weeks would make ETV worthwhile. Moreover, the authors noted that a second ETV should always be considered before shunt placement in young patients with a failed ETV, as the probability of ETV success rapidly increases four months after birth.<sup>[16]</sup>

The largest study of ETV success in very young children was conducted in Uganda and involved 153 children younger than one year.<sup>[17]</sup> The ETV success rate among these patients was 53%. The surgery success rates for patients with myelomeningocele and aqueductal obstruction were 40 and 70%, respectively.

Analysis of data supplied by 22 identified Canadian pediatric neurosurgeons from nine centers about ETV cases during the period from January 1989 through December 2004 showed that age was the primary determinant of ETV outcome in pediatric patients and that failure rates are particularly high in neonates and young infants.<sup>[18,19]</sup>

Fritsch *et al.*,<sup>[9]</sup> reporting a 39% ETV success rate, present ETV as an effective alternative for the treatment of obstructive hydrocephalus in infants younger than one year. The authors note that age does not present a contraindication for ETV or increase the perioperative risk. They conclude that the success of ETV is determined by the cause of hydrocephalus.

There are data showing that ETV is highly successful (a success rate of 100% in 13 patients) in infants born prematurely who have posthemorrhagic hydrocephalus and have previously undergone shunt placement.<sup>[20]</sup> The lowest success rate in that series (23%) was in patients who had sustained both hemorrhage and infection.

Korean authors have reported simultaneous implantation of a ventriculoperitoneal shunt and ETV as the first choice of

treatment for hydrocephalic patients younger than one year old (83.9% success rate). Maybe placement of the ventricular catheter in the prepontine cistern under endoscopic guidance reduces the risk of stoma closure and development of new arachnoid membranes.<sup>[21]</sup> On the other hand, these combined procedures do not provide patients with shunt independence and or freedom from shunt complications. More effective may be the routine placement of a ventricular reservoir during ETV in patients at great risk of ETV failure (for subsequent emergency access to the ventricular system or diagnosis of ETV failure)<sup>[22]</sup> or bilateral choroid plexus cauterization in combination with ETV in patients with a myelomeningocele or hydrocephalus that is not postinfectious in origin.<sup>[23]</sup>

According to Mohanty *et al.*,<sup>[24]</sup> reclosure of the stoma because of gliosis and scarring has been observed in 6–15% of ETV failures. They reported ETV failure in 13 of 72 patients, with 8 of the 13 being infants. Repeated endoscopic surgery was performed in 7 infants. In 3 of these 7, the stoma was found to be closed and was reopened. In 4 cases, the stoma was found to be open, necessitating insertion of a ventriculoperitoneal shunt. The high rate of reclosure in infants can be explained as follows: as CSF absorption is impeded,<sup>[25,26]</sup> there is a greater tendency for the development of new arachnoid membranes in infants,<sup>[14,27]</sup> and there is also growth of gliotic, ependymal, and scar tissue.<sup>[28]</sup>

In our study, we were aiming to discuss the success rate of endoscopic third ventriculostomy as a primary treatment of congenital obstructive hydrocephalus due to aqueductal stenosis in infants younger than six months with no previous history of CNS infection, septicemia, or intracranial hemorrhage and not associated with myelomeningocele. The selective inclusion criteria in spite of the high flow rate of our hospital limited our cases to 8 out of 150 hydrocephalic infants over a period of 6 months. We tried to eliminate the factors that may affect the subarachnoid space and may contribute to the failure of the procedure in order to clearly assess the outcome of this procedure in such age group. Although the literature reported very low success rate in such age group<sup>[29-31]</sup> which may be due to the open cranial sutures that does not permit an intraventricular pressure sufficient to drive the CSF across the ventriculostomy to the basal cisterns, many authors recently published higher success rates in the same age group and correlated the failure to other factors such as the etiology regarding the communicating type, thickness of the third ventricular floor, history of previous intracranial hemorrhage or CNS infection.

In our study, despite eliminating these factors, still the success rate did not exceed 12.5%. After review of literature no single study was done with the same inclusion criteria. This was due to the difficulty in collection of such cases. The false presumed high success rate in such group gave us the privilege to proceed with this study and report the low success rate. The fact that

the complication rate was low, we recommend that families be given the opportunity to decide whether the procedure should be attempted or a V-P shunt is directly applied.

## Conclusion

In our study, we were strictly confined to the preset highly selective inclusion criteria. This selection eliminated the factors suggested as causes of failure of ETV in infants below six months such as the etiology regarding the communicating type, thickness of the third ventricular floor, history of previous intracranial hemorrhage or CNS infection, still the success rate did not exceed 12.5%. We were urged to stop the study after the first eight cases due to this low success rate. The counselling of the patients' parents and their refusal to have first the option of ETV lead to their preference to apply immediately a VP shunt. We were obliged to report –due to high selection of both etiology and age- our limited experience with such an order of preference to CSF diversion procedures. In spite of the small number of cases in the study it was obvious that we can assess the preliminary success of ETV within the first six weeks after surgery and proven by a follow-up period of 24 months. But due to the fact that the complication rate was low, and due to the high frequency (20-80%)<sup>[11,24]</sup> and seriousness of postoperative complications following VP shunt that lead to a significant decrease in the quality of patients' lives compared to the low complication rate following ETV, the consequence of these findings for decision-making as well as parental counselling is to try to estimate the ETV success with other factors guiding the decision to perform ETV or shunt in the treatment of obstructive hydrocephalus. A multicenter extended study with a higher number of cases and exchange of experience is definitely advised.

## References

- Brownlee RD, Dold ON, Myles ST. Intraventricular hemorrhage complicating ventricular catheter revision: Incidence and effect on shunt survival. *Pediatr Neurosurg* 1995;22:315-20.
- Caldarelli M, Di Rocco C, La Marca F. Shunt complications in the first postoperative year in children with meningomyelocele. *Childs Nerv Syst* 1996;12:748-54.
- Piatt JH Jr. Cerebrospinal fluid shunt failure: Late is different from early. *Pediatr Neurosurg* 1995;23:133-9.
- Sgouros S, Mallucci C, Walsh AR, Hockley AD. Long-term complications of hydrocephalus. *Pediatr Neurosurg* 1995;23:127-32.
- Buxton N, Macarthur D, Mallucci C, Punt J, Vloeberghs M. Neuroendoscopic third ventriculostomy in patients less than 1 year old. *Pediatr Neurosurg* 1998;29:73-6.
- Goumnerova LC, Frim DM. Treatment of hydrocephalus with third ventriculocisternostomy: Outcome and CSF flow patterns. *Pediatr Neurosurg* 1997;27:149-52.
- Hopf NJ, Grunert P, Fries G, Resch KD, Perneczky A. Endoscopic third ventriculostomy: Outcome analysis of 100 consecutive procedures. *Neurosurgery* 1999;44:795-806.
- Jones RF, Kwok BC, Stening WA, Vonau M. Neuroendoscopic third ventriculostomy. A practical alternative to extracranial shunts in non-communicating hydrocephalus. *Acta Neurochir Suppl* 1994;61:79-83.
- Fritsch M, Kienke S, Ankermann T, Padion M, Mehdorn M. Endoscopic third ventriculostomy in infants. *J Neurosurg* 2005;103:50-3.
- Güzelbağ E, Erşahin Y, Mutluer S. Cerebrospinal fluid shunt complications. *Turk J Pediatr* 1997;39:363-71.
- Punt J, Vloeberghs M. Endoscopy in neurosurgery. *Minim Invasive Ther Allied Technol* 1998;7:159-70.
- Kadrian D, van Gelder J, Florida D, Jones R, Vonau M, Teo C, *et al.* Long-term reliability of endoscopic third ventriculostomy. *Neurosurgery* 2008;62:614-21.
- Koch-Wiewrodt D, Wagner W. Success and failure of endoscopic third ventriculostomy in young infants: Are there different age distributions? *Childs Nerv Syst* 2006;22:1537-41.
- Javadpour M, Mallucci C, Brodbelt A, Golash A, May P. The impact of endoscopic third ventriculostomy on the management of newly diagnosed hydrocephalus in infants. *Pediatr Neurosurg* 2001;35:131-5.
- Baldauf J, Oertel J, Gaab MR, Schroeder HW. Endoscopic third ventriculostomy in children younger than 2 years of age. *Childs Nerv Syst* 2007;23:623-6.
- Balthasar AJ, Kort H, Cornips EM, Beuls EA, Weber JW, Vles JS. Analysis of the success and failure of endoscopic third ventriculostomy in infants less than 1 year of age. *Childs Nerv Syst* 2007;23:151-5.
- Warf BC. Hydrocephalus in Uganda: The predominance of infectious origin and primary management with endoscopic third ventriculostomy. *J Neurosurg* 2005;102:1-15.
- Drake JM. Endoscopic third ventriculostomy in pediatric patients: The Canadian experience. *Neurosurgery* 2007;60:881-6.
- Drake JM. The surgical management of pediatric hydrocephalus. *Neurosurgery* 2008;62:633-42.
- Siomin V, Cinalli G, Grotenhuis A, Golash A, Oi S, Kothbauer K, *et al.* Endoscopic third ventriculostomy in patients with cerebrospinal fluid infection and/or hemorrhage. *J Neurosurg* 2002;97:519-24.
- Stan H, Popa C, Iosif A, Nistor S. Combined endoscopically guided third ventriculostomy with prepontine cistern placement of the ventricular catheter in a ventriculo-peritoneal shunt: Technical note. *Minim Invasive Neurosurg* 2007;50:247-50.
- Aquilina K, Edwards RJ, Pople IK. Routine placement of a ventricular reservoir at endoscopic third ventriculostomy. *Neurosurgery* 2003;53:91-7.
- Warf BC. Comparison of endoscopic third ventriculostomy alone and combined with choroid plexus cauterization in infants younger than 1 year of age: A prospective study in 550 African children. *J Neurosurg* 2005;103:475-81.
- Mohanty A, Vasudev MK, Sampath S, Radhesh S, Sastry Kolluri VR. Failed endoscopic third ventriculostomy in children: Management options. *Pediatr Neurosurg* 2002;37:304-9.
- Jones RF, Kwok BC, Stening WA, Vonau M. Third ventriculostomy for hydrocephalus associated with spinal dysraphism: Indications and contraindications. *Eur J Pediatr Surg* 1996;6:5-6.
- Teo C. Third ventriculostomy in the treatment of hydrocephalus: Experience with more than 120 cases. In: Hellwig D, editor. *Minimally Invasive Techniques for Neurosurgery*. Berlin: Springer; 1998. p. 73-6.
- Koch D, Wagner W. Endoscopic third ventriculostomy in infants of less than 1 year of age: Which factors influence the outcome? *Childs Nerv Syst* 2004;20:405-11.
- Hader WJ, Drake J, Cochrane D, Sparrow O, Johnson ES, Kestle J. Death after late failure of third ventriculostomy in children. Report of three cases. *J Neurosurg* 2002;97:211-5.
- Jones RF, Kwok BC, Stening WA, Vonau M. The current status of endoscopic third ventriculostomy in the management of non-communicating hydrocephalus. *Minim Invasive Neurosurg* 1994;37:28-36.
- Jones RF, Stening WA, Brydon M. Endoscopic third ventriculostomy. *Neurosurgery* 1990;26:86-91.
- Teo C, Jones R. Management of hydrocephalus by endoscopic third ventriculostomy in patients with myelomeningocele. *Pediatr Neurosurg* 1996;25:57-63.

**How to cite this article:** Zohdi AZ, El Damaty AM, Aly KB, El Refaee EA. Success rate of endoscopic third ventriculostomy in infants below six months of age with congenital obstructive hydrocephalus (a preliminary study of eight cases). *Asian J Neurosurg* 2013;8:147-52.

**Source of Support:** Nil, **Conflict of Interest:** None declared.