

# Decompressive craniectomy with multi-dural stabs – A combined (SKIMS) technique to evacuate acute subdural hematoma with underlying severe traumatic brain edema

Abdul Rashid Bhat, Altaf Rehman Kirmani, Mohammed Afzal Wani

Department of Neurosurgery, Sher-I-Kashmir Institute of Medical Sciences (SKIMS), Srinagar, Kashmir, India

## ABSTRACT

**Context:** The decompressive craniotomy alone or with dural flap opening to evacuate acute subdural hematoma with underlying brain edema in severe traumatic brain injury has proved either insufficient in the first place or has fatal complications secondly.

**Aims:** To reduce the fatality of conventional procedures and to evacuate acute subdural hematoma with severe brain edema by a combination of decompressive craniotomy and multi-dural stabs (SKIMS-Technique) without brain pouting and lacerations in low Glasgow coma scale (GCS) score patients.

**Settings and Design:** The prospective study was conducted in the Department of Neurosurgery, from June, 2006 to June 2011, under a uniform protocol.

**Materials and Methods:** A total of 225 patients of severe brain trauma were admitted to the accident and emergency unit of Neurosurgery and after initial resuscitation a CT brain was performed. All patients had a GCS score of 8 and below. All patients were ventilated postoperatively and ICP was monitored.

**Statistical Analysis Used:** The data was analyzed and evaluated by the statistical methods like student's *T*-test. The analysis of Variance was used where-ever applicable.

**Results:** The survival of multi-dural stab group was 77.31% (92/119) with good recovery in 42.02% (50/119) and a mortality of 22.69% (27/119) as compared with 46.23% (49/106) survival in open dural flap (control) group with 15.09% (16/106) good recovery and mortality of 53.77% (57/106).

**Conclusions:** This new approach, known as SKIMS-Technique or Combined Technique i.e., "decompressive craniectomy with multi-dural stabs", proved much effective in increasing survival of low GCS and severe traumatic brain edema patients with acute subdural hematoma.

**Key words:** Acute subdural hematoma, decompressive craniectomy, multi-dural stabs, outcome, severe brain edema, SKIMS-technique

### Access this article online

#### Quick Response Code:



#### Website:

www.asianjns.org

#### DOI:

10.4103/1793-5482.110275

### Address for correspondence:

Dr. Abdul Rashid Bhat, B-4 Faculty Quarters, Sher-I-Kashmir Institute of Medical Sciences, Srinagar, Kashmir - 190 011, India.  
E-mail: seven\_rashid@rediffmail.com

## Introduction

The concept of wide decompressive craniectomy in severe traumatic brain swelling is based on the principle of Monro-Kellie Doctrine that 'total intracranial volume is fixed because of rigid and inelastic nature of skull which contains brain.'<sup>[1,2]</sup> Kocher T in 1901 and Harvey Cushing in 1905 were the first to describe decompressive craniectomy for the relief of increased intracranial pressure.<sup>[3,4]</sup> The decompressive craniectomy is one of the treatment modalities which can be performed in the worsening and low Glasgow coma scale (GCS) score patients with dilated pupils and resisting maximal decongestant therapy because of acute subdural hematoma, contusions, and

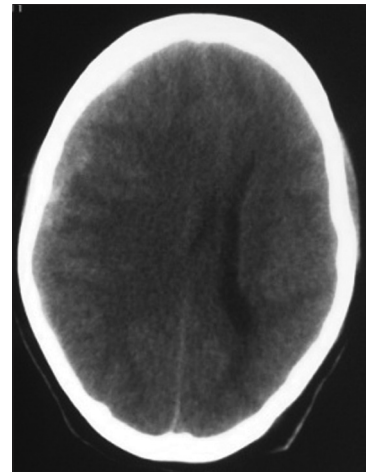
acute brain swelling.<sup>[5]</sup> The surgical decompression after severe traumatic brain injury by open dural flaps, removal of contused and infarcted brain, removal of acute subdural and extradural hematomas is an effective practice.<sup>[6]</sup> However, in all these procedures the aim is to gain intracranial extraspaces by way of decompression to change the constant of “fixed intracranial volume in rigid and inelastic skull” to quickly relieve the raised intracranial pressure (ICP). The Division of Neurosurgery, SKIMS Srinagar, Kashmir, prospectively evaluated all the standard procedures against a new indigenous technique (multi-dural stabs or SKIMS-Technique) and found promising results. The main objective of this study was to evaluate the effect of “Multi-dural stabs” in the complete removal of acute subdural hematoma for quick relief of raised ICP and to prevent any further secondary brain damage due to opening of dural flaps where superficial clots and contused brain could be removed with ease but the deeper edematous white matter swelling, which pushes itself and the overlying cortex with vital vasculature out of the cranial cavity causing lacerations to further compound the brain insult.

## Materials and Methods

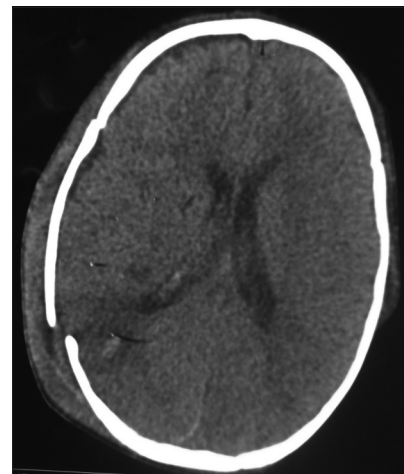
The study to evaluate the efficacy of the “multi-dural stabs” SKIMS-Technique after wide craniectomy in 119 cases against the conventional open dural flap after wide craniectomy in 106 controls to decompress acute subdural hematomas in low GCS<sup>[7]</sup> score 3-8 in presence of severe brain edema, took place in the Division of Neurosurgery, SKIMS Kashmir from Jun. 2006 to Jun. 2011. All 225 patients of GCS score 3-8 following trauma were received in the accident and emergency room within 30 minutes to 6 hours of trauma. Immediate intubation and resuscitation followed non-contrast CT-scan brain with bone windows. Patients with significant acute subdural hematoma (>25 ml volume) causing midline shift (>5 mm) and severe brain edema [Figure 1] due to underlying multiple hemorrhagic and non-hemorrhagic contusions, subarachnoid hemorrhages and diffuse axonal injury were randomly allotted to the multi-dural stabs (cases) and open dural flap (controls) decompressive procedures. Postoperatively, all patients were electively ventilated, subjected to ICP monitoring, serial arterial blood gas (ABG) analysis and serial CT-scans to evaluate intracranial extraspaces gain [Figure 2] and whenever indicated such as the worsening of GCS score. The outcome was assessed by applying Glasgow Outcome Scale<sup>[8]</sup> at the time of discharge and up to six months after discharge, however, the results drawn here are of at the time of discharge. Initially, bone flaps were implanted in the abdominal fat, now these are stored at  $-80^{\circ}\text{C}$  for next four weeks to three months for reimplantation. The data was analyzed and evaluated by the statistical methods like student’s *T*-test. The analysis of Variance was used, where ever applicable.

## Technique of “multi-dural stabs” or SKIMS-technique

This is a decompressive procedure for acute subdural hematoma in the presence of severe brain edema and midline



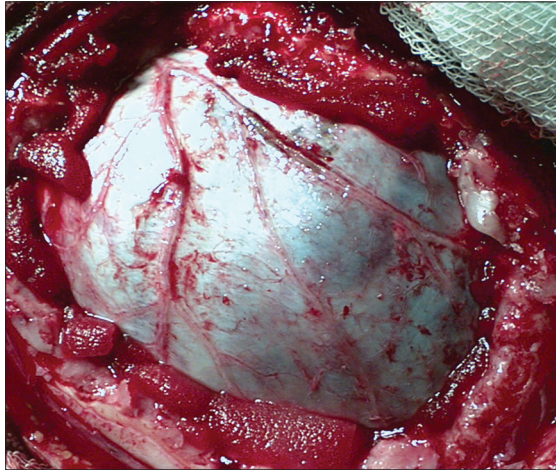
**Figure 1:** Plain CT-scan brain in a closed head injury shows acute subdural hematoma, midline shift, obliteration of cisterns and ventricles due to brain edema



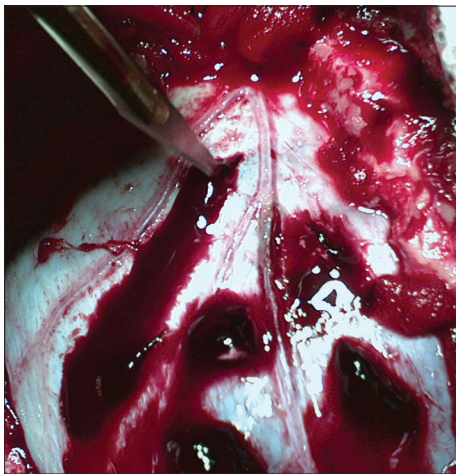**Figure 2:** Plain CT-scan at 4 weeks of multi-dural stabs, resolving contusion after severe brain edema, and acute subdural hematoma with replaced bone flap

shift [Figure 1] to preserve the anatomical integration of the arachnoid, pia, brain tissue, and its vasculature by opening dura less than or equal to a gyral size at one place. The blue, intact and tense dura is completely defined after wide craniectomy [Figure 3]. A no.11 stab knife is used to apply multiple linear dural incisions of about 5-8 mms long, in horizontal lines, parallel to vessels and 2-2.5 cm apart from each other. The caution is that knife tip should not penetrate the dura more than 0.5 to 1.0 mm [Figure 4]. The initial gush of the hematoma is forceful and venous-like but subsequent incisions reduce the gush force. The normal saline is used continuously to wash the dura off the blood and clots. A soft 6F silastic catheter is passed through the stab, horizontal to and its eye facing, the dura, to wash and remove any stuck up clots on the surface of brain. The completion of the procedure is indicated by the change in the color, consistency, and the flattening of dura [Figure 5]. Although most of the times the dura continues to be tense even after the drainage of the

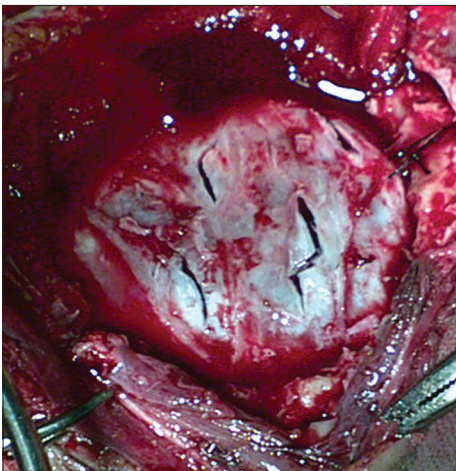
subdural hematoma, only small blebs of arachnoid covered brain tissue incarcerate through and slightly widen the stab openings without any brain lacerations. Since most of the



**Figure 3:** Bluish, bulging and tense dura, overlying severe brain edema and acute subdural hematoma, after wide craniectomy



**Figure 4:** Technique of multi-dural stabs parallel to vessels leading to gradual decompression



**Figure 5:** The multi-stabbed, relaxed, depressed and grayish-blue dura after evacuation of subdural hematoma

liquefied blood and the clot accumulate in the centre of the craniectomy site causing central dural bulge, the periphery of the craniectomy is preferred as the site for the first few incisions. This is to avoid incisional injury to the peripheral brain which is close to the overlying dura, in case the hematoma is first drained in the thickest and usually central part of craniectomy. However, if the dura is torn with tensely pouting brain, the procedure is still ideal but in large tears if the brain is lax and still inside the edges or margins of the excised cranial vault, the open dural flap is carried out. Also in the wake of any bleeding from brain, which usually stops with continuous saline washes, it is mandatory to locate the site of bleed and apply a longer incision rather than a stab to achieve complete hemostasis. The dura can always be cauterized locally for any bleeding. Thus, acute subdural hematoma is removed through dural-stabs while at the same time the integrity of the dura, arachnoid, pia, brain and its vasculature, in the presence of the severe ‘vent-searching’ brain edema, is largely preserved. Thus, extra-space is gained intracranially by craniectomy and dural relaxation in addition to removal of acute subdural hemorrhage, changing the fixed coefficient of “total intracranial volume” [Figure 2]. Though solid clot may stick to the brain at the end of the procedure but the liquid and semi-solid blood evacuation leads to the quick relief of the raised ICP, much needed to save the patient.

**Results**

The comparative results of the cases (multi-dural stabs) and the controls (open-dural flap) revealed similar demographic variables in both the groups. But the GCS and the outcome of case study and control groups varied. A total of 19 patients were operated on the posterior fossa, 8 from multi-dural stabs, and 11 from control group. Bilateral decompressive craniectomy was performed in a total of 15 patients, 9 from multi-dural stabs, and 6 from open-dural flap group. Most patients reached the emergency room within four to six hours of the injury. Both the groups had more than 80% males

**Table 1: GCS related to age multi-dural stabs (cases)**

	Age – group in years				Total
	No. of cases				
	0-20	21-40	41-60	61-80	
<b>GCS</b>					
3-4	4	20	4	2	30
5-6	5	29	5	3	42
7-8	14	26	5	2	47
Total	23	75	14	7	119
<b>Open-dural flap (Controls)</b>					
3-4	5	19	1	2	27
5-6	7	23	4	1	35
7-8	9	29	6	0	44
Total	21	71	11	2	106

GCS – Glasgow coma scale

[Table 1]. Most patients (approximately 65%) were in the age group of 21-40 years both from case as well as control groups. Of the multi-dural stabs group, 25.21% (30/119) patients were in the GCS 3-4 group and also 25.47% (27/106) of the open dural flap group had GCS 3-4. In comparison to only 39.50% (47/119) patients of GCS 7-8 in the multi-dural stab group, most of the open-dural flap patients, 41.51% (44/106), were in the in GCS 7-8 group. Noteworthy was maximum number of patients, 27.36% (29/106), of open-dural flap (controls) being in the age group of 21-40 years with GCS 7-8. However, only 21.85% (26/119) patients of multi-dural stabs had such an age group and GCS. Conversely, most 24.37% (29/119) of the multi-dural stab group with age 21-40 had GCS of only 5-6 [Table 1]. While comparing outcome to the age and sex, the multi-dural stab (case study group) had an overall and better survival of 77.31% (92/119) and a good-recovery of 42.02% (50/119), especially 30.25% (36/119) good recovery in the age group 21-40 years. This proved effective as compared to an overall 46.23% (49/106) survival and 15.09% (16/106) good recovery in the open-dural flap (control group), while age group of 21-40 years also showed a mere 7.55% (8/106) good recovery. The children and age group 0-20 years alone had only 21.74% (5/23) mortality in the multi-dural stabs as compared with the open-dural flap group with 61.90% (13/21) deaths [Table 2]. Of all 18 females in the multi-dural stab group, 6 died with a mortality of 33.33% (6/18), and there were 20.79% (21/101) deaths in 101 males as compared with the 57.14% (12/21) deaths in females and 52.94% (45/85) deaths of males in the open-dural flap group [Table 3]. The GCS and outcome relationship shows that multi-dural stab group has better survival of 77.31% (92/119) than open dural flap (control group) with 46.23% (49/106). The multi-dural-stab group depicted higher survival for all GCS groups, GCS 3-4 had 15.97% (19/119) survival and 9.24% (11/119) mortality, 5-6 revealed 30.25% (36/119) survival and 5.04 (6/119) mortality, 7-8 carries 31.09% (37/119) survival and 8.40% (10/119) mortality and an overall good recovery of 42.02% (50/119), most for GCS 7-8: 23.52% (28/119). Comparatively, open-dural flap group revealed lower survival in all GCS groups, GCS 3-4: 10.38% (11/106), 5-6: 14.15% (15/106), 7-8: 21.70% (23/106) and an overall good recovery of 15.09% (16/106) with 6.60% (7/106) in GCS 7-8 group [Table 3]. An overall lower mortality of 22.69% (27/119) for all patients of, with 9.24% (11/119) in GCS 3-4, multi-dural stabs (cases) than patients of open dural flaps (controls) was evident [Table 3]. The open-dural flap group showed a mortality of 53.77% (57/106) and it was highest 59.26% (16/27) for the GCS 3-4. At the time of discharge the multi-dural stabs had favorable outcome (good recovery and moderate disability) in 48.74% (58/119) and poor outcome (severe disability, vegetative state, and deaths) in 51.26% (61/119) patients, while in open-dural flap, 22.64% (24/106) had favorable outcome and 77.36% (82/106) poor outcome. This improved over six months. There were many

**Table 2: Age related to outcome multi-dural stabs (cases)**

	Age – group				Total
	No. of cases				
	0-20	21-40	41-60	61-80	
<b>Survival/Mortality</b>					
Good recovery	8	36	4	2	50
Moderate disability	1	4	2	1	8
Severe disability	1	8	4	1	14
Vegetative state	8	10	1	1	20
Mortality	5	17	3	2	27
Total	23	75	14	7	119
<b>Open-dural flap (controls)</b>					
Good recovery	1	8	5	2	16
Moderate disability	4	1	2	1	8
Severe disability	1	9	1	0	11
Vegetative state	2	11	1	0	14
Mortality	13	42	2	0	57
Total	21	71	11	3	106

(P<0.0001)

**Table 3: GCS and sex related to outcome multi-dural stabs (cases)**

	Outcome								Total		
	Survival										
	Good recovery		Moderate disability		Severe disability		Vegetative state			Mortality	
	M	F	M	F	M	F	M	F	M	F	
<b>GCS</b>											
3-4	5	0	4	0	2	1	6	1	10	1	30
5-6	14	3	3	0	6	1	8	1	3	1	42
7-8	23	5	1	0	4	0	4	0	8	4	47
Total	42	8	8	0	12	2	18	2	21	6	119
	50		8		14		20		27		
<b>Open-dural flap (controls)</b>											
3-4	4	0	1	0	2	1	2	1	12	4	27
5-6	5	0	2	1	3	0	3	1	15	5	35
7-8	6	1	3	1	4	1	5	2	18	3	44
Total	15	1	6	2	9	2	10	4	45	12	106
	16		8		11		14		57		

(P<0.0001); GCS – Glasgow coma scale

cases whose condition, due to the associated injuries, did not allow major brain surgery, the multi-dural stabs made itself an alternative procedure for such patients. The complications like wound infection, seizures, hygromas, hydrocephalus, and cerebral atrophy (in most of the surviving patients in both groups) were not related to the surgical decompression but primary trauma. These were managed without causing any deaths.

## Discussion

Traumatic acute subdural hematoma is one of the most lethal of all head injuries in which primary brain injury is more

critical factor than a clot. The outcome depends upon the ability to control ICP rather than removal of subdural clot. Although timing of clot removal within four hours of injury has lowered mortality to 30% with functional rate of 65%, but ICP control has been a critical factor.<sup>[9]</sup> The high mortality of acute subdural hematoma is largely explained by its frequent association with primary brain damage consisting of contusions and brain swelling. However, the nature and causes of brain swelling after traumatic brain injury are multifactorial and poorly understood. Brain swelling associated with acute subdural hematoma is caused by secondary insult to brain in addition to primary parenchymal injury. The authors report outcome of acute subdural hematoma associated with brain swelling as poor even when treated with early surgical evacuation. The mortality rate of such patients was over 75%.<sup>[10]</sup> At Neurosurgical center, SKIMS Kashmir, the outcome of such patients with early and open dural flap was similar i.e., poor with 53.77% mortality. But multi-dural stabs had favorable outcome of 48.74% and survival rate of 77.31% with only 22.69% mortality. Brain swelling and the acute subdural hematoma were most common, i.e., 64%, CT-scan findings in a series.<sup>[11]</sup> Even after operative decompression, the prognosis of acute subdural hematoma is still poor in many cases. This is thought due to coexisting brain damage (Diffuse Axonal Injury, contusions, lacerations) that leads to poor outcome. Thus poor outcome is resultant of the compression of the microcirculation and resulting low CBF which leads to lucid interval i.e., 'talk and die'.<sup>[12]</sup> It was observed at SKIMS, Kashmir that conventional (open-dural flap) surgery in controls to remove subdural clot in presence of coexisting injuries and edema, even though early, could not avoid pouting and laceration of brain and cortical vasculature despite substantial amount of decongestion. This led to poor outcome in 77.36% of the patients in controls (open-dural flap). However, multi-dural stab group had all favorable outcomes. The aim was to find the way to evacuate acute SDH in presence of severe underlying white matter edema as well as to save the cortical architecture of the brain from pouting due to continuous pressure by underlying edema. The multi-dural stabs allowed evacuation of acute subdural hematoma (SDH) by oozing of blood clots and fluid and prevented pouting and laceration of brain, but in open-dural flap there was no control on the pouting and subsequent laceration of brain which was the cause of much morbidity and mortality. Experimental investigators assessed the effect of rapid or delayed surgical evacuation on the physiological consequence and brain edema formation in a rat model of acute SDH coupled with either diffuse brain injury (DBI) or hypoxemia. The SDH was made by an autologous blood injection, while DBI was induced using the impact acceleration model (mild, 450 g/1 m; severe, 450 g/2 m). Physiological parameters measured included ICP, mean arterial blood pressure (MABP), cerebral blood flow (CBF), and brain tissue water content. The surgical evacuation showed no beneficial effects on the brain

edema formation assessed at 5-hour post-injury. The rapid, but not delayed, evacuation significantly reduced both the increased ICP level and brain water content. The additional insult of hypoxemia resulted in a progressive ICP elevation, persistently depressed CBF, and severe brain swelling. Under this situation, the rapid evacuation exacerbated brain edema. These results have clinical implications for the management of severe traumatic SDH, especially its operative indication and timing.<sup>[13]</sup> The results revealed in the SKIMS study showed that multiple stabbing of the dura at intervals decompressed the underlying edematous brain slowly with better results, in comparison to the open dural flap [Table 3]. However, there were patients in both the groups whose ICP was controlled close to normal, but these showed no clinical improvement at all and some patients continued to have high ICP but finally survived the pressure brunt. Thus proving multi-dural stabs or open-dural flap methods do not work only through relief of ICP but other factors are also responsible for the outcome. Some authors showed Single burr hole evacuation in the emergency room as a useful treatment for acute subdural hematoma of the posterior cranial fossa because the procedure can be performed easily and rapidly, thus achieving reduction of ICP.<sup>[14]</sup> At SKIMS, all 8 cases of posterior fossa acute subdural hematoma had multiple dural incisions after wide craniectomy (multi-dural stabs), avoiding wastage of time in opening dural flaps after craniectomy. A series reports the outcome of acute subdural hematomas, delay from injury to operation was the factor of greatest therapeutic importance. Patients who underwent surgery within the first four hours had a 30% mortality rate, as compared with 90 percent in those who had surgery after four hours ( $P < 0.0001$ ).<sup>[15]</sup> However, at SKIMS, most patients were received after four hours but mortality rate, though time factor counts, differed with the procedure and was least for multi-dural stabs (22.69%). Hemispherical brain edema observed after evacuation of subdural or extradural hematoma, is a well recognized entity. In an autopsy study, 17 out of 151 cases had this and it was not contributed to contusions, intracerebral hematoma or infection. The aetiopathogenesis of the lesion is still debated.<sup>[16]</sup> However, there is an evidence to suggest that it may be secondary to ischemia caused by the compressive hematoma or vasomotor paralysis.<sup>[17]</sup> All 225 patients at SKIMS, Kashmir, had brain edema, contusions and acute subdural clot. The 60.50% (72/119) of multi-dural stabs and 58.49% (62/106) of open-dural flaps were having a low admission GCS of 3-6 and none of all patients (225) had a GCS above 8, the results were still better for multi-dural stabs, most probable cause being the protection of brain cortex from laceration by pouting. It is reported in the literature that at the time of discharge of 49 patients, 72% had poor outcome (severe disability, vegetative state or death) with 59% mortality and 28% had favorable outcome (good recovery, moderate disability). This improved six months after trauma, from 72% to 59% (poor outcome) and 28% to

41% (favorable outcome).<sup>[5]</sup> In the study at SKIMS, among the two groups, multi-dural stab group had a good recovery of 42.02% as compared with the open-dural flap (control) group with only 15.09%. The most likely cause of in-comparable results between the two groups was firstly the preoperative uncontrolled malignant traumatic brain edema, refractory to the decongestants and stony hard dura and underlying brain about to pout and tear as soon as dural flap was opened. Secondly, since multi-dural stabs removed acute SDH and at the same time contained brain within the dural walls, most of the morbidity and mortality could be avoided. These patients also responded to the postoperative decongestant therapy optimally. An author reported 33% mortality and 14% vegetative state with only 7% demonstrating good outcome.<sup>[18]</sup> An earlier study on traumatic brain edema by the authors showed a mortality of 52.5%.<sup>[19]</sup> While at SKIMS, Kashmir, open-dural flap (controls) had 53.77% mortality and only 15.09% good recovery as against multi-dural stab group with better outcome [Table 3]. The dural-stabs for the evacuation of acute subdural hematoma as a procedure has been used on 60 patients by the authors.<sup>[20]</sup>

## Conclusion

The multi-dural stabs or SKIMS- (combined decompressive craniotomy and multi-dural stabs). Technique is the quicker, safer (in any condition), novel, parenchymal preserving, and effective decompressive procedure for the removal of acute subdural hematoma in the presence of severe traumatic brain edema to gain extra-space intracranially with good outcome. The residual solid clot dissolves slowly over a period of few days without any further rise in ICP. The technique is rapid ICP reliever and avoids brain pouting and cortical lacerations at the time of surgery. However, this procedure needs further trials in the future to understand its effect on the pathogenesis of brain edema after gaining extra-space intracranially without opening dural flap and to establish it as a routine combined decompressive technique.

## Acknowledgments

Thanks to Little Aisha, Huwa, Nancy, and Aisha-Samad for their continuous support and assistance.

## References

1. Kellie G. On death from cold, and, on congestion of the brain: An account of the appearances observed in the dissection of two of three individuals presumed to have perished in the storm of 3<sup>rd</sup> November 1821; with some reflections on the pathology of the brain. *Trans Med Chir Soc Edinb* 1824;1:84-169.
2. Monro A. Observations on the structure and the function of the nervous system. Edinburgh: Creech and Johnson; 1823. p. 5.
3. Kocher T. Die Therapie des Hirndruckes, In: Holder A (editor):

- Hirnerschütterung, Hirndruck und chirurgische Eingriffe bei Hirnkrankheiten. Vienna: A Holder; 1901. p. 262-6.
4. Cushing H. the establishment of cerebral hernia as a decompressive measure for inaccessible brain tumors with the description of intermuscular methods of making the bone defect in the temporal and occipital regions. *Surg Gynecol Obstet* 1905;1:297-314.
5. Munch E, Horn P, Schurer L, Piepgras A, Paul T, Schmiedek P. Management of severe traumatic brain injury by decompressive craniectomy. *Neurosurgery* 2000;47:315-23.
6. Chambers I, Treadwell L, Mendelow AD. Secondary brain insults following traumatic brain injury (TBI) in children and their relationship with outcome. *Br J Neurosurg* 2000;14:416-23.
7. Teasdale G, Jennett B. Assessment of coma and impaired consciousness, a practical scale. *Lancet* 1974;2:81-4.
8. Jennett B, Bond M. Assessment of outcome after severe brain damage. *Lancet* 1975;1:480-4.
9. Wilberger JE, Harris M, Diamond DL. Acute subdural hematoma: Morbidity, mortality and operative timing. *J Neurosurg* 1991;74:212-8.
10. Sawauchi S, Abe T. The effect of haematoma, brain injury and secondary insult on brain swelling in traumatic acute subdural haemorrhage. *Acta Neurochirurgica* 2008;150:531-6.
11. Faleiro RM, Faleiro LC, Caetano E, Gomide I, Pita C, Coelho G, *et al.* Decompressive Craniotomy: Prognostic factors and complications in 89 patients. *Arq Neuropsiquiatr* 2008;66:369-73.
12. Schroder ML, Muizelaar JP, Kuta AJ. Documented reversal of global ischemia immediately after removal of an acute subdural hematoma: Report of two cases. *J Neurosurg* 1994;80:324-7.
13. Sawauchi S, Marmarou A, Beaumont A, Signorett S, Fukui S. Acute subdural hematoma associated with diffuse brain injury and hypoxemia in the Rat: Effect of surgical evacuation of the hematoma. *J Neurotrauma* 2004;21:563-73.
14. Motohashi O, Kameyama M, Shimosegawa Y, Fujimori K, Sugan K, Onuma T. Single burr hole evacuation for traumatic acute subdural hematoma of the posterior fossa in the emergency room. *J Neurotrauma* 2002;19:993-8.
15. Seelig JM, Becker DP, Miller JD, Greenberg RP, Ward JD, Choi SC. Traumatic acute subdural hematoma: Major mortality reduction in comatose patients treated within four hours. *N Engl J Med* 1981;304:1511-8.
16. Adams JH, Graham DI, Gennareli TA. Neuropathology of acceleration – induced head injury in the subhuman primate. In: *Head Injury: Basic and Clinical Aspects*, In: Grossman RG, Gildenberg PL, Editors., New York: Raven Press; 1982. p. 141-150.
17. Yoshino E, Yamaki T, Higuchi T, Horikawa Y, Hirakawa K. Acute brain edema in fatal head injury: Analysis by dynamic CT scanning. *J Neurosurg* 1985;63:830-9.
18. Marshall LF, Gattille T, Klauber MR. The outcome of severe closed head injury. *J Neurosurg* 1991;75:28-36.
19. Bhat AR, Wani MA, Kirmani A, Raina T, Alam S, Ramzan A. traumatic brain edema and survival – effective role of pentoxifylline. *Biomed Res* 2008;19: 9-12.
20. Bhat AR, Wani MA, Kirmani AR, Raina T, Sajad A, Ramzan AU. Dural-stabs after wide craniectomy to decompress acute subdural hematoma with severe traumatic brain edema – An alternative technique to open dural flap. *IJNT* 2010;7:29-36.

**How to cite this article:** Bhat AR, Kirmani AR, Wani MA. Decompressive craniectomy with multi-dural stabs - A combined (SKIMS) technique to evacuate acute subdural hematoma with underlying severe traumatic brain edema. *Asian J Neurosurg* 2013;8:15-20.

**Source of Support: Nil, Conflict of Interest: None declared.**