

## Case Report

# Fluoro-deoxy-glucose Positron Emission Tomography/Computed Tomography Pattern in a Patient with Linitis Plastica of the Stomach Caused by Primary Signet Cell Adenocarcinoma

Chidambaram Natrajan Balasubramanian Harisankar, Raghava Kashyap, Anish Bhattacharya, Bhagwant Rai Mittal

Department of Nuclear Medicine and PET, Postgraduate Institute of Medical Education and Research, Chandigarh, India

## Abstract

We report the findings of [18F] fluoro-deoxy-glucose (FDG) positron emission tomography (PET) performed in a 67-year-old female with suspicion of gastric carcinoma. Intense FDG uptake was noted in the thickened gastric wall. Subsequent laparotomy showed diffuse involvement of the gastric wall by signet ring cell adenocarcinoma. This report highlights FDG PET/CT pattern in linitis plastica of the stomach caused by primary signet cell adenocarcinoma.

**Key words:** F-18 FDG, linitis plastica, PET/CT, stomach cancer

## Introduction

Linitis plastica, stomach appearing like a leather bottle, is commonly caused by gastric adenocarcinoma infiltrating the submucosa and muscularis propria of stomach. But this could also be due to metastatic infiltration of the stomach, particularly from breast and lung carcinomas. It is characterized by a thick, rigid stomach wall caused by diffuse infiltration of tumor cells and extensive fibrosis. PET imaging may show striking metabolic activity within the entire stomach wall.

## Case Report

A 67-year-old female presented with dysphagia and loss of weight. There was no lymphadenopathy. She denied

any history of previous tuberculosis. On palpation, abdomen was soft and nontender without organomegaly. Ultrasound of the abdomen and computed tomography (CT) showed revealed diffuse thickening of the stomach. Additionally, specks of calcification were noted in the gastric wall on CT. Gastric endoscopy was normal and endoscopic biopsy was negative for malignancy. With suspicion of gastric lymphoma, she was subjected to [18F] fluoro-deoxy-glucose (FDG) positron emission tomography (PET). Whole body contrast-enhanced PET/CT was performed 1 hour after intravenous injection of 10 mCi of F-18 FDG. It showed [Figure 1] diffusely thickened gastric wall with few specks of calcification with intense FDG uptake in the thickened gastric wall (SUVmax 8.3). No significant lymphadenopathy was noted. No abnormal FDG uptake was noted in rest of the organs. The patient was subsequently subjected to laparotomy due to high risk of malignancy. Intraoperatively diffuse thickening of the gastric wall was noted and was inoperable. Biopsy revealed diffuse infiltration of the gastric wall by signet cell adenocarcinoma. The patient is being treated with chemotherapy.

### Access this article online

#### Quick Response Code:

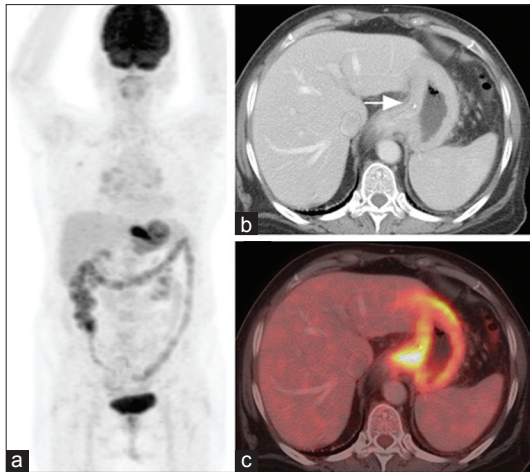


Website:  
www.wjnm.org

DOI:  
10.4103/1450-1147.98743

#### Address for correspondence:

Dr. B.R.Mittal, Prof. & Head, Department of Nuclear Medicine & PET, PGIMER, Chandigarh – 160 012, India. E-mail: brmittal@yahoo.com



**Figure 1:** F-18 FDG PET/CT images (a) maximum intensity projection image showing diffusely increased FDG uptake throughout the stomach, CT images (b) show diffusely thickened gastric wall with few specks of calcification (arrow) in the lesser curvature and fused PET/CT image (c) show intense FDG uptake in the thickened gastric wall (SUVmax 8.3)

## Discussion

Gastric linitis plastica is defined as diffuse thickening and rigidity of the gastric wall resulting from inflammation and fibrosis. Primary gastric adenocarcinoma infiltrating the submucosa and muscularis is the most common cause of linitis plastica. Metastases to the stomach can cause linitis plastica infrequently. Infiltrating lobular carcinoma of the breast is the most common metastatic cause of linitis plastica.<sup>[1,2]</sup> The gastric mucosa is spared of the malignant infiltration and hence endoscopic diagnosis is difficult. Linitis shows very little mucosal lesions on gross appearance.<sup>[3]</sup> Macroscopic features do not often permit the distinction between benign and malignant lesions, multiple endoscopic biopsies are required. However, standard endoscopic biopsy specimens, that usually contain only mucosa, offer frequently negative results for malignancy.<sup>[4]</sup> In patients with negative biopsy results on endoscopy, a fine needle biopsy can be performed under echographic, echoendoscopic or CT guidance with a good sensitivity and specificity for the diagnosis of malignancy.<sup>[5]</sup> FDG uptake in the stomach can be physiological, resulting from smooth-muscle activity, or may be the result of non-neoplastic inflammation. SUVmax of less than 4.0

in the stomach on FDG PET is generally not associated with esophagogastric neoplasia and does not require further evaluation.<sup>[6]</sup> Distension of stomach by food ingestion may be useful in evaluation of primary gastric cancer.<sup>[7]</sup> FDG PET patterns of linitis plastica caused by lymphoma<sup>[8]</sup> and breast cancer<sup>[9]</sup> have been previously described. We have described the pattern observed in a case of linitis plastica caused by primary gastric signet cell adenocarcinoma. This condition should be considered in all patients with thickened gastric wall showing diffusely increased FDG uptake.

## References

1. Taal BG, Peterse H, Boot H. Clinical presentation, endoscopic features, and treatment of gastric metastases from breast carcinoma. *Cancer* 2000;89:2214-21.
2. Ferri LE, Onerheim R, Emond C. Linitis plastica as the first indication of metastatic lobular carcinoma of the breast: case report and literature review. *Can J Surg* 1999;42:466-9.
3. Negreanu L, Assor P, Bumsel F, Metman EH. An endoscopic view in gastric linitis. A case report. *J Gastrointest Liver Dis* 2007;16:321-3.
4. Andriulli A, Recchia S, De Angelis C, Mazzucco D, Berti E, Arrigoni A, *et al.* Endoscopic ultrasonographic evaluation of patients with biopsy negative gastric linitis plastica. *Gastrointest Endosc* 1990;36:611-5.
5. Mortensen MB, Pless T, Durup J, Ainsworth AP, Plagborg GJ, Hovendal C. Clinical impact of endoscopic ultrasound-guided fine needle aspiration biopsy in patients with upper gastrointestinal tract malignancies. A prospective study. *Endoscopy* 2001;33:478-83.
6. Salaun PY, Grewal RK, Dodamane I, Yeung HW, Larson SM, Strauss HW. An analysis of the 18F-FDG uptake pattern in the stomach. *J Nucl Med* 2005;46:48-51.
7. Zhu Z, Li F, Zhuang H. Gastric distension by ingesting food is useful in the evaluation of primary gastric cancer by FDG PET. *Clin Nucl Med* 2007;32:106-9.
8. Ak I, Aydemir B, Gülbaş Z. Scintigraphic appearance of "linitis plastica" in a patient with gastric non-Hodgkin's lymphoma on 18F-FDG imaging. *Eur J Nucl Med Mol Imaging* 2006;33:625-6.
9. Kanne JP, Mankoff DA, Baird GS, Minoshima S, Livingston RB. Gastric linitis plastica from metastatic breast carcinoma: FDG and FES PET appearances. *AJR Am J Roentgenol* 2007;188:W503-5.

**How to cite this article:** Harisankar CB, Kashyap R, Bhattacharya A, Mittal BR. Fluoro-deoxy-glucose Positron Emission Tomography/Computed Tomography Pattern in a Patient with Linitis Plastica of the Stomach Caused by Primary Signet Cell Adenocarcinoma. *World J Nucl Med* 2012;11:26-7.

**Source of Support:** Nil. **Conflict of Interest:** None declared.