

## Case report

# Postoperative Intraperitoneal Bladder Rupture Detected by Renal Scintigraphy: The Importance of Postvoid Imaging

Bryan Kang, Daniel Eisenberg, Nikki Sistrun, Hongju Son

Department of Radiology, Albert Einstein Healthcare Network, Philadelphia, PA 19141, USA

## Abstract

Iatrogenic intraperitoneal bladder rupture is an entity that may present in a patient with idiopathic ascites. Nuclear scintigraphy is an unusual modality for the diagnosis of this etiology, and in particular, the postvoid imaging demonstrates critical findings. We present a case report, pertinent imaging, and a review of literature.

**Keywords:** Bladder, genitourinary, iatrogenic, postoperative, Tc-99m Mag-3 scintigraphy

## Introduction

A computed tomography (CT) examination is the most common tool in the diagnosis of bladder rupture.<sup>[1,2]</sup> Renal scintigraphy is not the first-line imaging modality in the diagnosis of bladder rupture; however, with unexplained laboratory values and symptoms in postoperative patients which show no definite or equivocal CT evidence, renal scintigraphy can play an important role in evaluating renal and bladder functions. Postvoid and delayed imaging, in particular, can demonstrate sequela of a bladder rupture as well as other sequela of postsurgical complications with damage to the collecting system. A search of literature demonstrates the prior usage of renal scintigraphy with diethylenetriaminepentaacetic acid in the diagnosis of bladder rupture.<sup>[3]</sup> The demonstration of intraperitoneal bladder rupture after supracervical hysterectomy with Tc-99m MAG3 is not commonly encountered, and awareness of the imaging findings may be critical to diagnosis.

### Address for correspondence:

Dr. Bryan Kang, Department of Radiology, Albert Einstein Healthcare Network, 5501 Old York Road, Philadelphia, PA 19141, USA.  
E-mail: kangbrya@einstein.edu

### Access this article online

#### Quick Response Code:



Website:  
www.wjnm.org

DOI:  
10.4103/1450-1147.215489

## Case Report

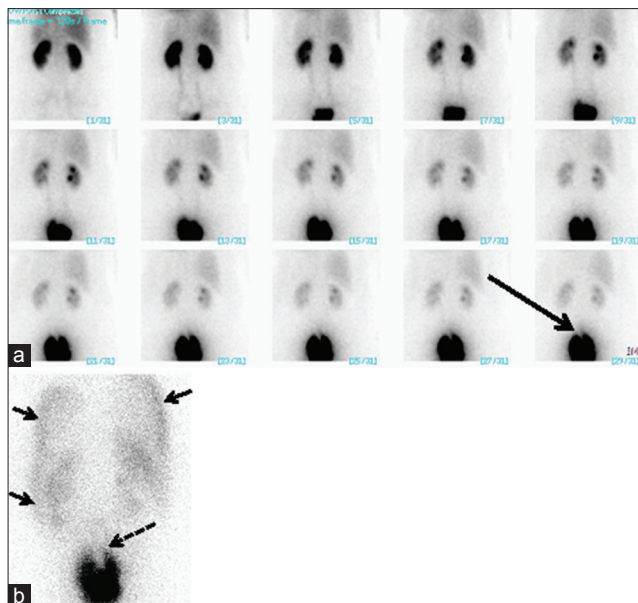
A 41-year-old woman with a history of menorrhagia and fibroids underwent a supracervical hysterectomy 6 days before presentation. Laboratory values on admission demonstrated an elevated creatinine. Unenhanced CT on admission was unremarkable except for a small amount of ascites and edema of the anterior abdominal wall with subsequent postcontrast CT demonstrating increasing ascites (not shown). Due to the elevated creatinine levels, there was a concern of acute renal failure. The following ultrasound was normal except for a small amount of perihepatic-free fluid corresponding to the recent CT examination.

The patient underwent renal scintigraphy with 388.5 MBq of Tc-99m MAG3 (mercaptoacetyl triglycine) to evaluate renal function due to the elevated serum creatinine levels. Perfusion images (not shown) show prompt bilateral symmetric perfusion to the kidneys. Functional print images of the renal functional phase [Figure 1a] show prompt cortical uptake and transit as well as spontaneous drainage of collecting systems bilaterally. However,

This is an open access article distributed under the terms of the Creative Commons Attribution-NonCommercial-ShareAlike 3.0 License, which allows others to remix, tweak, and build upon the work non-commercially, as long as the author is credited and the new creations are licensed under the identical terms.

For reprints contact: reprints@medknow.com

**How to cite this article:** Kang B, Eisenberg D, Sistrun N, Son H. Postoperative intraperitoneal bladder rupture detected by renal scintigraphy: The importance of postvoid imaging. World J Nucl Med 2017;16:314-6.

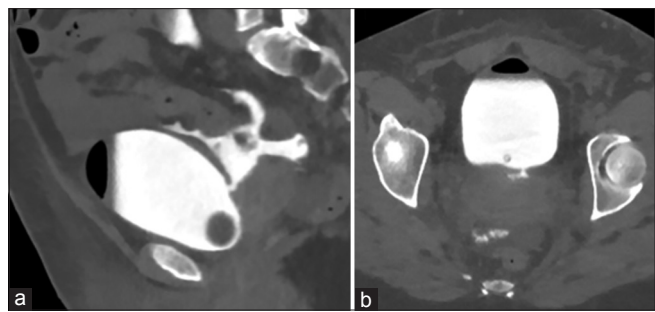


**Figure 1:** Functional print images of the renal functional phase (a) with normal function. Delayed phase imaging (b) demonstrating ascites and defect within the bladder representing intraluminal air within the bladder

there is a focal contour deformity on the superior aspect of the urinary bladder (long solid arrow) which likely corresponds to air accumulation within the bladder seen on CT. Postvoid image [Figure 1b] shows a large amount of urine leak in the intraperitoneal space (solid arrows) outlining the contour of the liver, spleen, and paracolic gutters. There is a persistent bladder filling despite patient's effort of emptying with a conspicuous superior filling defect (dotted arrow). There is faint bilateral renal uptake. Findings are consistent with intraperitoneal bladder rupture. Finding was confirmed with subsequent CT cystogram [Figure 2] demonstrating an intraperitoneal bladder leak with freely extravasated contrast to the peritoneal cavity with the defect present at the posterior aspect of the urinary bladder (dotted arrow) as well as fluoroscopic cystogram (not shown).

## Discussion

Rupture of the urinary bladder demonstrates a reported incidence of 1 of every 126,000 admissions to a hospital setting. This may be secondary to idiopathic spontaneous rupture, urinary retention, or chronic disease of the bladder. The initial presentation of acute renal failure with findings of abdominal pain, ascites, and decreased urinary output can mask the underlying etiology of a bladder rupture. Laboratory values within the presented case demonstrated findings of increased serum creatinine and mild hyperkalemia. Peritoneal tap and laboratory analysis also demonstrated increased fluid urea, potassium, and creatinine that were increased above



**Figure 2:** Computed tomography cystogram (a) with contrast freely entering into the peritoneal cavity with the (b) defect present at the posterior aspect of the urinary bladder

the serum blood levels. The concurrent rise in serum creatinine and hyperkalemia may become a confounding factor as these are recognized reasons for alternate presentations of acute renal failure.

Bladder rupture can be extra- or intra-peritoneal. The dome, in particular, is the least supported and also the only portion covered by peritoneum.<sup>[4]</sup> The elevation of serum creatinine is secondary to the absorption of urine across the peritoneal membrane and is a known mimicker of presentations of acute renal failure.<sup>[5,6]</sup> A CT examination is the most common tool in the diagnosis of bladder rupture.<sup>[7]</sup> Renal scintigraphy is not the first-line imaging modality in the diagnosis of bladder rupture; however, with unexplained laboratory values and symptoms within a postoperative patient, renal scintigraphy can play a pivotal role; postvoid and delayed phase imaging, in particular, can demonstrate sequela of a bladder rupture as well as other sequela of postsurgical complications with damage to the collecting system. A search of literature demonstrated the prior usage of renal scintigraphy with DTPA in the diagnosis of bladder rupture.<sup>[1-3,8]</sup> In summary, we report a case of Tc-99m MAG3 demonstrating the presence of intravesicular air and extravasation of radiotracer representing intraperitoneal bladder rupture after supracervical hysterectomy.

## Financial support and sponsorship

Nil.

## Conflicts of interest

There are no conflicts of interest.

## References

1. Titton RL, Gervais DA, Hahn PF, Harisinghani MG, Arellano RS, Mueller PR. Urine leaks and urinomas: Diagnosis and imaging-guided intervention. *Radiographics* 2003;23:1133-47.
2. Deck AJ, Shaves S, Talner L, Porter JR. Computerized tomography cystography for the diagnosis of traumatic bladder rupture. *J Urol*

- 2000;164:43-6.
3. Lantsberg S, Rachinsky I, Boguslavsky L, Piura B. Diagnosis of urinary leak following abdominal total hysterectomy using renal scintigraphy. *Eur J Obstet Gynecol Reprod Biol* 2000;91:11-3.
  4. Landman W, Khurana B, Briggs A, Fairweather M, Cooper Z, Riviello R, *et al.* BWH emergency radiology-surgical correlation: Intraperitoneal urinary bladder rupture. *Emerg Radiol* 2015;22:713-6.
  5. Arun KG, Salahuddin, Leela V, Noel J, Venkatesh K, Ramakrishnan S, *et al.* Intraperitoneal bladder rupture mimicking acute renal failure. *Indian J Nephrol* 2008;18:26-7.
  6. Zhou C, Ying X, Feng W. Pseudo-acute renal failure due to intraperitoneal urine leakage. *Intern Med* 2015;54:1777-80.
  7. Matsumura M, Ando N, Kumabe A, Dhaliwal G. Pseudo-renal failure: Bladder rupture with urinary ascites. *BMJ Case Rep* 2015;2015. pii: bcr2015212671.
  8. Dat A, Yip CL, Hanegbi U. Beware of the ascites patient: Delayed presentation of traumatic intraperitoneal bladder rupture. *Urol Case Rep* 2015;4:11-3.