

Case report

Laxative Related Primary Hyperphosphatemic Tumoral Calcinosis Identified by Bone Scintigraphy

Marcus Asokendaran, Nat Patrick Lenzo¹

Departments of General Medicine and ¹Nuclear Medicine, Fremantle Hospital, WA 6160, Australia

Abstract

We describe a case of a 40-year-old female patient presenting with tumor calcinosis where hypertrophic pulmonary osteoarthropathy (HPOA) was suspected given her extensive history of malignancy. Plain X-rays did not show reveal the typical periarticular calcification but did show appearances consistent with HPOA. Bone scintigraphy with ^{99m}Tc-methylene diphosphonate (MDP) is a sensitive investigation in the detection of hypertrophic osteoarthropathy but did not show findings characteristics of HPOA like bilateral symmetrical increased uptake of the radiopharmaceutical along the cortical margins of the long bones. The final diagnosis of tumor calcinosis was only made after low dose computerized tomography chest showed a moderated sized amorphous calcified cluster in the apical segment of the right upper lobe consistent. In conclusion, bone scintigraphy continues to be a useful investigation for both common and rare conditions like tumor calcinosis. The unusual three phase bone scan finding of diffuse activity throughout both lung fields, which turned to out to be tumoral calcinosis is highlighted in this case.

Keywords: Bone scintigraphy, joint, tumor calcinosis

Introduction

Tumor calcinosis is a rare condition, in which there is increased deposition of calcium in the periarticular soft tissues. Bone scintigraphy with ^{99m}Tc-methylene diphosphonate (MDP) is not only a sensitive investigation in the detection of hypertrophic osteoarthropathy, but can also be used to detect sources inflammation and calcification throughout the body. This case demonstrates the ability of ^{99m}Tc-MDP in detecting a rare care like tumor calcinosis, in a patient with a documented history of malignancy.

Case Report

A 40-year-old female, with a history of anorexia nervosa with chronic laxative abuse, was admitted to the medical

ward for nasogastric feeding. Her body mass index was 10 on admission, and she was frequently monitored for refeeding syndrome.

This is on a background of having right breast cancer in 2004, treated with right mastectomy and reconstructive surgery, followed by chemotherapy and also right shoulder osteosarcoma in 2005, treated with radiotherapy.

Follow-up positron emission tomography (PET)-computerized tomography (CT) in 2008 showed no evidence to suggest the metabolically active recurrence of either the patient's previous breast cancer or osteosarcoma. There was a small right lung nodule that was not metabolically active however was at the lower limit of resolution of the fludeoxyglucose PET scan, and an ongoing radiological surveillance was recommended. The nodule did not progress radiologically over time.

She had a history of being treated with hypercalcemia of unknown cause despite thorough investigation in the past and last received bisphosphonates 4 years prior to this current admission. She had a history of recurrent neoproliferation resulting in chronic kidney disease

Access this article online

Quick Response Code:



Website:
www.wjnm.org

DOI:
10.4103/1450-1147.174709

Address for correspondence:

Dr. Marcus Asokendaran, Department of General Medicine, Fremantle Hospital, WA 6160, Australia. E-mail: mashok82@hotmail.com

and also suffered from constipation and pseudo bowel obstruction.

During her latest admission, she also started complained of worsening severe musculoskeletal pain that had started 5 years prior. This mainly involved the small joints of her hands, wrist, elbows and both knees. She noticed that both her knees would swell on some days.

Laboratory Investigations revealed: Plasma calcium - 2.48 (2.15 - 2.60 mmol/L), adjusted plasma calcium - 2.42 (2.15 - 2.60 mmol/L), parathyroid hormone - 4.6 (1.6 - 6.9 pmol/L), Urea - 30.6 (3.0 - 8.0 mmol/L), creatinine - 168 (45 - 90 umol/L).

Phosphate levels ranged between 0.70 and 1.90 (0.80 - 1.50 mmol/L).

Magnesium levels ranged between 0.76 and 1.42 (0.70 - 1.10 mmol/L).

Plain X-rays of her both elbows and knees showed smooth periosteal reaction involving the long bones of the distal humerus and proximal ulna as well as the medial and lateral surfaces of the distal femur and proximal tibia and fibula. Appearances were consistent with hypertrophic osteoarthropathy (HPOA).

Given her history of right breast cancer, osteosarcoma of right shoulder and medullary nephrocalcinosis, she went on to have a dynamic bone scan to further evaluate these changes.

The dynamic bone scan did not show the typical pattern of HPOA in the digits though increased activity was seen in bilateral carpal joints [Figure 1]. There was evidence of possible calcinosis around the larger

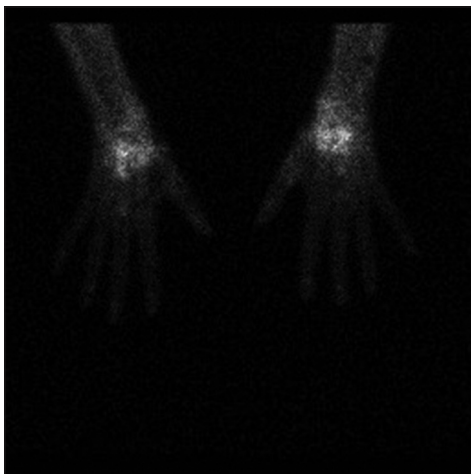


Figure 1: Images of the hands do not show the typical pattern of hypertrophic pulmonary osteoarthropathy in the digits though increased activity is seen in bilateral carpal joints

joints such as the knees. There was diffuse activity that was seen throughout both lung fields can also be seen with pulmonary inflammation such as Wegener's granulomatosis or in prominent hypercalcemia [Figure 2]. She went on to have a noncontrast CT of her chest, which showed a moderated sized amorphous calcified cluster in the apical segment of the right upper lobe. More subtle calcification was noted in the apical segment of the left upper lobe. These findings would be consistent with tumoral calcinosis [Figure 3].

Discussion

Tumor calcinosis is a rare condition, in which there is increased deposition of calcium in the periarticular soft tissues. The original phrase was first described by Incan in 1943.^[1]

It mainly affects the soft tissue of the hips, pelvis, shoulder and elbow joints^[2] although it may also be encountered in the hands, ankle and wrist.

The different possible pathogenesis includes:

- Primary normophosphatemic tumoral calcinosis: Normal serum phosphate, normal serum calcium, with no evidence of disorders previously associated with soft tissue calcification^[3]
- Primary hyperphosphatemic tumoral calcinosis: Elevated serum phosphate, normal serum calcium, and no evidence of disorders previously associated with soft tissue calcification; and
- Secondary tumoral calcinosis: Seen in chronic renal failure with secondary hyperparathyroidism,

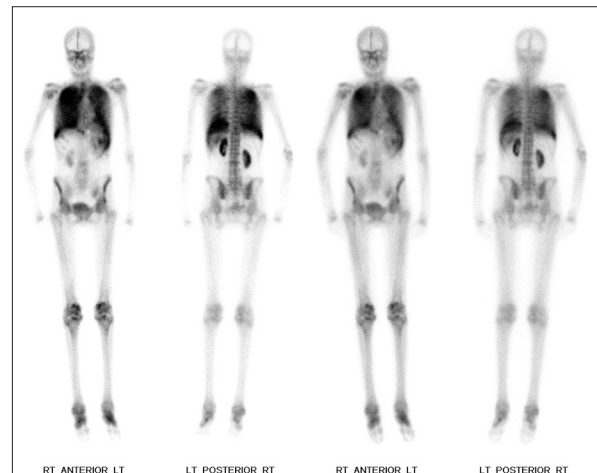


Figure 2: Whole body blood pool images show low-grade but diffuse activity in the lung fields, with prominent activity seen at the knees, right ankle joint and to a degree at the shoulders. Delayed static images reveal diffuse increased activity throughout both lung fields. Small kidneys are noted. Periarticular changes and irregular increased activity is seen at both knees, within the mid feet and several of the other peripheral joints

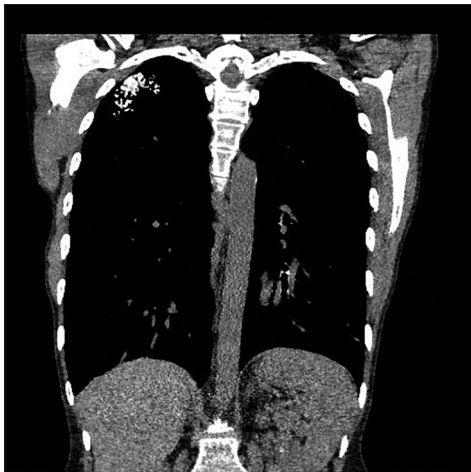


Figure 3: Tumoral calcinosis noted in the lung apex in the right with more subtle early changes also in the left lung apex

hypervitaminosis D, Milk-alkali syndrome, and bone destruction.^[3]

Plain radiographs typically reveal periarticular calcifications without involvement of the underlying joints. CT scans will often reveal cystic spaces within the calcified masses, especially in larger lesions and ultrasound imaging will reveal fluid accumulation within the cystic space.^[4,5]

Bone scintigraphy with ^{99m}Tc-MDP is a sensitive investigation in the detection of hypertrophic osteoarthropathy. The scintigraphic findings characteristics of HPOA are bilateral symmetrical increased uptake of the radiopharmaceutical along the cortical margins of the long bones. Due to the typical appearance it is also known as tram line or double stripe sign.^[6]

While Tc-MDP bone scintigraphy has been used to in the past to diagnose sporadic case of tumor calcinosis with relapses,^[7] to the best of the authors knowledge, there has not been case reports of de novo tumor calcinosis identified by whole bone scintigraphy.

What is of more interest is the fact that, our patient had both hyperphosphataemia and hypermagnesemia from ongoing laxative abuse in the setting of anorexia nervosa and chronic renal impairment. Hypermagnesemia may develop in patients with

impaired renal function or in those who are given a large dose of magnesium either intravenously or as an enema.^[8]

The long-term management of tumour calcinosis can be divided into medical and surgical options. More conservative measures include low-calcium and low-phosphate diets, phosphate deprivation by oral aluminum hydroxide, and induction of the phosphaturia by acetazolamide.^[9,10] Indications for surgical intervention include difficult to control pain, recurrent infection, ulceration, and functional impairment.^[11]

References

1. Inclan A. Tumoral calcinosis. *JAMA* 1943;121:490-5.
2. Yurdoglu C, Ozbaydar MU, Adas M, Ozger H. Familial tumoral calcinosis in three patients in the same family. *Acta Orthop Traumatol Turc* 2007;41:244-8.
3. Smack D, Norton SA, Fitzpatrick JE. Proposal for a pathogenesis-based classification of tumoral calcinosis. *Int J Dermatol* 1996;35:265-71.
4. Franco M, Van Elslande L, Passeron C, Verdier JF, Barrillon D, Cassuto-Viguier E, *et al.* Tumoral calcinosis in hemodialysis patients. A review of three cases. *Rev Rhum Engl Ed* 1997;64:59-62.
5. Martinez S, Vogler JB 3rd, Harrelson JM, Lyles KW. Imaging of tumoral calcinosis: New observations. *Radiology* 1990;174:215-22.
6. Rosenthal L, Kirsh J. Observations of radionuclide imaging in hypertrophic pulmonary osteoarthropathy. *Radiology* 1976;120:359-62.
7. Guveli TK, Mulazimoglu M, Tamam MO, Tamam C, Tatoglu T, Ozpacaci T. Tc-MDP bone scintigraphy in a case with sporadic tumoral calcinosis. *Indian J Nucl Med* 2010;25:27-8.
8. Randall RE Jr, Cohen MD, Spray CC Jr, Rossmeisl EC. Hypermagnesemia in renal failure. Etiology and toxic manifestations. *Ann Intern Med* 1964;61:73-88.
9. Yamaguchi T, Sugimoto T, Imai Y, Fukase M, Fujita T, Chihara K. Successful treatment of hyperphosphatemic tumoral calcinosis with long-term acetazolamide. *Bone* 1995;16:247S-50S.
10. Kumaran MS, Bhadada S, Bhansali A, Shriram M, Kumar B. Young boy with multiple periarticular swellings and discharging sinuses: Tumoral calcinosis. *Indian J Pediatr* 2004;71:e74-6.
11. Alam A, Sree Ram MN, Manrai K, Bhardwaj R. Tumoral calcinosis. *Med J Armed Forces India* 2007;63:180-1.

How to cite this article: Asokendaran M, Lenzo NP. Laxative related primary hyperphosphatemic tumoral calcinosis identified by bone scintigraphy. *World J Nucl Med* 2016;15:200-2.

Source of Support: Nil, **Conflict of Interest:** None declared.