

Original article

Is the Increased Septal Perfusion the Signal of Asymmetrical Septal Hypertrophy?

Semra Ozdemir, Yusuf Ziya Tan, Emine Gazi¹

Departments of Nuclear Medicine and ¹Cardiology, Canakkale Onsekiz Mart University, Çanakkale, Turkey

Abstract

In this study, we have compared scintigraphic and echocardiographic data in order to investigate whether increased septal perfusion represents asymmetrical septal hypertrophy (ASH), which is a symptom followed in the scintigraphy of myocardial perfusion. The study consists of a total of 186 patients (120 females and 66 males with an average age of 59.45 ± 11.54 years) who had normal myocardial perfusion scintigraphy and echocardiography examinations. Statistical comparison of septal wall thickness measurements obtained from echocardiography and septal-to-lateral wall ratios (S/L ratio) was performed scintigraphically. Left ventricular mass values were obtained as both scintigraphic and echocardiographic data and their correlations were evaluated in order to assess the presence of left ventricular hypertrophy (LVH). In statistical analyses, the values of interventricular septal thickness in diastole (IVSd), left ventricle posterior wall thickness in diastole (LVPWd), left ventricle mass (LVM), and left ventricle mass index (LVMI) were found to be significantly higher in group 2 (S/L ratio >1) compared to group 1 (S/L ratio <1). In addition, S/L ratio is significantly correlated with echocardiographic IVSd, LVPWd, LVM, LVMI, and scintigraphic LVM (rest) values. Furthermore, echocardiographic LVM and LVMI values were significantly correlated with LVM and LVMI values obtained from scintigraphy. It should be known that increased S/L ratio that can be monitored during scintigraphic studies can be an indicator of septal hypertrophy and/or LVH, however, further examination and close follow-ups should be performed in necessary cases.

Keywords: Asymmetrical septal hypertrophy, increased septal perfusion, scintigraphy

Introduction

Asymmetrical septal hypertrophy (ASH) is defined as abnormal ventricular muscle thickening of the interventricular septal wall, and it is often seen in patients with hypertension.^[1-3] ASH usually develops during the initial phase of left ventricular hypertrophy (LVH) seen in hypertensive (HT) patients. It is also considered as a type of HT LVH.^[4-6] Even though LVH is observed in some disorders and diseases, such as valve disease, congenital heart disease, hypertrophic cardiomyopathy (HCM) and obesity, the most common reason that causes

LVH is hypertension.^[7-9] Increased septal perfusion is a finding that may be encountered during perfusion scans, and it can be evaluated visually as well as quantitatively (S/L ratio). Although clinical meaning of increased septal perfusion is not fully understood, it is thought that it points to hypertension cases and hypertrophic cardiomyopathy. Therefore, in the present study, it has been aimed to investigate whether increased septal perfusion represents asymmetric septal hypertrophy by evaluating increased septal perfusion, which is commonly encountered in routine nuclear medicine, with echocardiographic data. We have also aimed to investigate whether the size of the left ventricle and dimensions obtained from echocardiography are correlated with each other.

Address for correspondence:

Dr. Semra Ozdemir,
Department of Nuclear Medicine, Canakkale Onsekiz Mart University,
Faculty of Medicine, Canakkale - 17100, Turkey.
E-mail: semozdemir@yahoo.com

Access this article online

Quick Response Code:



Website:

www.wjnm.org

DOI:

10.4103/1450-1147.174706

This is an open access article distributed under the terms of the Creative Commons Attribution-NonCommercial-ShareAlike 3.0 License, which allows others to remix, tweak, and build upon the work non-commercially, as long as the author is credited and the new creations are licensed under the identical terms.

For reprints contact: reprints@medknow.com

How to cite this article: Ozdemir S, Tan YZ, Gazi E. Is the increased septal perfusion the signal of asymmetrical septal hypertrophy?. World J Nucl Med 2016;15:184-9.

Materials and Methods

Patient population

A total of 323 patients with normal perfusion were retrospectively selected as population of the study among cases who were waiting for myocardial perfusion gated single-photon emission computed tomography (SPECT) examinations between January 2012 and November 2014. However, only 186 (120 women and 66 men, with a mean age of 59.45 ± 11.54 years) of these patients with echocardiography examination were included in the study. Standard 12 lead electrocardiograms (ECGs) data and gated myocardial perfusion gated SPECT image findings in addition to the records of patients' histories were reviewed prior to the study. Demographic characteristics and risk factors for coronary artery disease of all patients were also noted.

We have obtained written informed consent from all patients.

Myocardial perfusion gated SPECT imaging protocol

All patients included in the study received as same-day rest-stress technetium (Tc)-99m sestamibi gated SPECT myocardial perfusion imaging protocol. Rest images were taken 30 min to 1 h after injection of 296–370 MBq Tc^{99m} methoxy-isobutyl-isonitrile (sestaMIBI). On the other hand, stress images are taken 3–4 h after taking the rest images. 925–1,110 MBq of Tc^{99m} sestamibi was injected at peak exercise for stress studies and imaging was done 15 min to 1 h after the injection. Treadmill (Bruce protocol) exercise and dipyridamole (0.142 mg/kg/min IV) was used for myocardial perfusion gated SPECT. A dual head gamma camera (Infinia, General Electric Medical Systems, Milwaukee, Wisconsin, USA) was used to perform SPECT imaging. The data obtained were analyzed using automatic-processing software for quantitative gated SPECT (QGS), Cedars Sinai Quantitative Perfusion SPECT (QPS), and Emory Cardiac Toolbox (ECTb). Two nuclear medicine specialists analyzed the scintigraphic images visually and quantitatively.

Visual interpretation

The images of sagittal, coronal, and transaxial slices obtained from rest and stress studies were evaluated. According to these evaluations, it has been concluded that all patients included in the study had normal myocardial perfusion.

Quantitative interpretation of perfusion wall motion and thickening with QPS and QGS programs

The global summed thickening score (STS), left ventricular ejection fractions (LVEFs), and global

summed motion score (SMS) were obtained from stress studies automated QGS program. Summed rest score (SRS), summed stress score (SSS), and summed difference score (SDS) were automatically calculated by using QPS software.

Gated myocardial perfusion with ECTb program

Left ventricular mass values were automatically obtained from this program.

Echocardiographic measurements

According to the current recommendations of the European Society of Echocardiography, a 3.5-MHz transducer (Vivid 7 GE USA) was used to perform the transthoracic echocardiographic examination.^[10] Left ventricular posterior wall thickness in diastole (LVPWd), left ventricular diameter in diastole (LVDd), and interventricular septal thickness in diastole (IVSd) were also recorded.

Left ventricle mass (LVM) was calculated by using the adjusted formula of Devereux as follows: $LVM = 0.8 \times 1.04 \times [(LVDd + LVPWd + IVSd)^3 - LVDd^3] + 0.6 \text{ g.}^{[11]}$

Left ventricle mass index (LVMI) was calculated by dividing body surface area (LVM/BSA, g/m²) into LVM. BSA was calculated using the formula as follows: $BSA = 0.6 \times \text{height (m)} + 0.0128 \times \text{weight (kg)} - 0.1529.^{[12]}$

Quantitative Definition of S/L ratio

Segment maps of Bull's eye created from stress images are used to calculate S/L ratio values. S/L ratios were obtained for each patient by calculating average perfusion ratios in the segments corresponding to septum and lateral wall. Patients with S/L ratio values smaller than 1 were identified as group 1 and those with S/L values higher than 1 were identified as group 2, respectively.

Statistical analysis

Statistical Package for the Social Sciences version 19.0 computer program (SPSS-Inc., Chicago, US) was used to perform all statistical analyses, and continuous data were given as mean \pm SD. *t*-Test was used for samples in order to test the significance level of mean values. Pearson's Chi-square tests were used to compare the distribution of variables and Mann-Whitney *U*-test and Student's *t*-test were used to test the differences between two groups in terms of categorical factors. In addition, Kruskal-Wallis test was used to compare continuous values after analyzing the normality. Finally, Spearman's correlation analysis was employed to analyze the changes occurred in the variables.

Results

A total of 186 patients with normal perfusion scintigraphy findings were included in these analyses. Table 1 presents the clinical characteristics of the cohort. According to the results of analyses, there were no significant differences between two groups in terms of clinical characteristics such as smoking habits, diabetes mellitus, hyperlipidemia, age, body mass index, and family history of coronary artery disease. Systolic and diastolic arterial blood pressures measured during scintigraphy of the patients before the test were found to be higher in the patients of group 2 compared to group 1 (systolic pressure $P < 0.001$, diastolic pressure $P = 0.012$).

According to comparison of electrocardiographic parameters, there was statistically significant difference between the heart rate parameters ($P = 0.014$). However, no significant differences were found in corrected QT (QTc), PR interval, and electrocardiographic parameter of QRS [Table 1].

When echocardiographic and scintigraphic data were compared between the groups; it has been seen that values of echocardiographic parameters such as LVPW, IVS, LVM, and LVMI were found to be higher in group 2 compared to group 1, respectively. There was no difference between groups in terms of LVD values. However, while only LVM (rest) parameters showed differences ($P = 0.043$) between groups among index parameters LVM and LVMI obtained from both rest and stress scintigraphy, there was no differences between groups in terms of other parameters. Furthermore, there were significant differences between groups in terms of septal-to-lateral wall values that are used as grouping criteria. Examples of patients with S/L ratio >1 and S/L ratio <1 were given in Figure 1a and b, respectively. All these findings are consistent with correlation tests performed between echocardiographic and scintigraphic parameters and S/L ratios [Table 2].

Considering LVM and LVMI values obtained from scintigraphy, the values obtained in both rest and stress

Table 1: Some demographic-clinical parameters results in the presented patients

Clinical characteristics	All patients (n=186)	Group 1	Group 2	P value
		S/L wall ratio <1 (n=129 %69.4)	S/L wall ratio >1 (n=57 %30.6)	
The mean age (y)	59.45±11.54	58.60±12.05	61.37±10.14	0.083
Gender (male) n (%)	66 (35.5)	50 (38.8)	16 (28.1)	0.161
Body mass index (kg/m ²)	29.08±4.39	28.73±4.29	29.85±4.55	0.073
Co-morbidities				
Hypertension	104 (55.9)	58 (45)	46 (80.7)	<0.001
Diabetes mellitus n (%)	56 (31.1)	33 (25)	23 (40.4)	0.043
Hyperlipidemia n (%)	38 (20.4)	22 (17)	16 (28)	0.087
Smoking n (%)	29 (15.6)	21 (16.3)	9 (15.8)	0.933
Family history of CAD n (%)	61 (32.8)	39 (30.2)	22 (38.6)	0.264
Systolic BP (mm/Hg)	129.55±19.23	125.98±16.83	137.63±21.87	<0.001
Diastolic BP (mm/Hg)	77.14±10.48	75.74±10.44	80.32±9.96	0.012
ECG				
QRS interval (ms±SD)	90.35±12.28	88.77±9.24	91.05±13.37	0.562
QTc (corrected) (ms±SD)	413.98±24.19	413.28±24.34	415.58±23.97	0.448
PR interval (ms±SD)	148.55±23.49	148.27±23.74	149.18±27.09	0.820
Heart rate (bpm)	82.33±14.82	80.76±14.89	85.89±14.16	0.014
Echocardiography				
LVDd (mm)	44.81±4.15	44.87±4.16	44.68±4.17	0.702
LVPWd (mm)	10.09±1.44	9.86±1.31	10.61±1.58	0.001
IVSd (mm)	10.60±1.59	10.29±1.44	11.29±1.70	<0.001
LVM (g)	162.35±44.01	156.76±41.71	175.00±46.77	0.013
LVMI (g/m ²)	87.83±22.13	84.65±20.52	95.04±24.07	0.003
Scintigraphy				
LVEF	68.35±8.29	68.14±7.91	68.84±9.14	0.726
S/L wall ratio	0.99±0.07	0.95±0.04	1.08±0.48	<0.001
LVM (rest)	121.17±14.64	119.69±14.71	124.53±14.03	0.065
LVMI (rest)	65.88±8.07	64.95±7.62	67.98±8.71	0.043
LVM (stress)	113.16±14.93	112.50±15.07	114.67±14.63	0.501
LVMI (stress)	61.45±7.57	60.99±7.33	62.48±8.06	0.439

Group1: S/L ratio <1 , Group2: S/L ratio >1 , LVDd: Left ventricular diameter in diastole; LVPWd: Left ventricular posterior wall thickness in diastole; IVSd: Interventricular septal thickness in diastole; LVM: Left ventricular mass; LVMI: Left ventricular mass index; LVEF: Left ventricular ejection fraction

tests obtained from scintigraphy were found to be lower than LVM and LVMI values. However, there was a strong correlation between these values obtained from echocardiography and scintigraphy [Table 3].

Discussion

The lateral wall thickness of a normal left ventricle is greater than septum. Accordingly, in myocardial perfusion scintigraphy, it is expected to see more radiopharmaceutical uptake expected in lateral wall since its thickness is greater than thickness of septum. However, during myocardial perfusion scintigraphy scanning, some cases are observed where radiopharmaceutical uptake is visually or/and quantitatively more in the septal wall compared to the lateral wall. However, this situation is not fully understood in clinical terms yet. In order to present the clinical meaning of this case more clearly, we have selected patients with normal perfusion findings and compared their S/L ratios. According to these comparisons, it has been seen that these ratios are correlated with echocardiographic left ventricular size indexes. In addition, since a strong correlation was found between echocardiographic and scintigraphic measurements of LVM and LVMI values; it can be concluded that scintigraphic LVM and LVMI values can provide important clues in daily nuclear medicine practices.

As it is known, hypertension is a widely encountered disease that can be associated with LVH. Left ventricular hypertrophy may be asymptomatic until developing unexpected sudden death or congestive heart failure. So it is important to detect the presence of left ventricular hypertrophy and ASH, which are an early symptoms of left ventricular hypertrophy.^[13-16]

In the literature, it is reported that asymmetric septal hypertrophy can be seen in both HT patients and HCM

cases. According to a study conducted by Shimizu *et al.*, the wall thickness was significantly greater in both the HT and HCM groups than in the control group, whereas

Table 2: Spearman’s correlation coefficients of S/L wall ratio and echocardiographic, sintigraphics parameters

Parameters	rho	P
Echocardiography		
IVSd	0.271	<0.001*
LVPWd	0.252	0.001*
LVM	0.197	0.007*
LVMI	0.201	0.006*
MPS gated		
LVM (rest)	0.161	0.028*
LVMI (rest)	0.120	0.102
LVM (stress)	0.096	0.191
LVMI (stress)	0.056	0.450

IVSd: Interventricular septal thickness in diastole; LVPWd: Left ventricular posterior wall thickness in diastole; LVM: Left ventricular mass; LVMI: Left ventricular mass index; *: Correlation is significant at the 0.05 level (2-tailed)

Table 3: Spearman’s correlation coefficients of echocardiographic and sintigraphic left ventricular mass parameters

Spearman’s rho and P* value	Echocardiographic LVM	Echocardiographic LVM Index
Scintigraphic LVM (rest)		
rho	0.441	
P	<0.001*	
Scintigraphic LVMI (rest)		
rho		0.333
P		<0.001*
Scintigraphic LVM (stress)		
rho	0.426	
P	<0.001*	
Scintigraphic LVMI (stress)		
rho		0.309
P		<0.001*

*: Correlation is significant at the 0.05 level (2-tailed). LVM: Left ventricular mass; LVMI: Left ventricular mass index

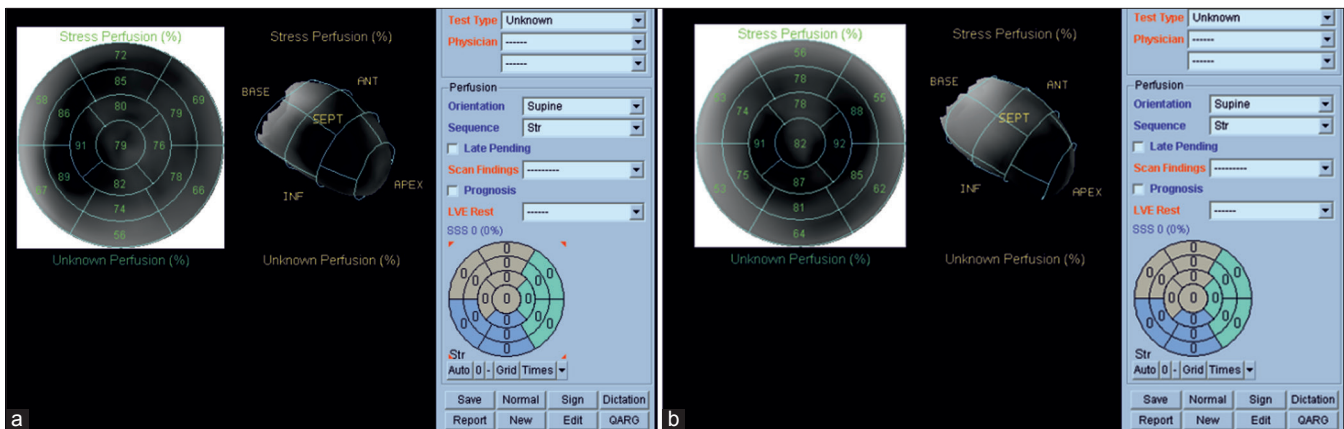


Figure 1: (a) An example of Bull’s eye segments of the patient with S/L ratio >1 in myocardial perfusion scintigraphy. The values obtained from echocardiography were as follows: IVSd = 13 mm, LVPWd = 12 mm. (b) An example of Bull’s eye segments of patient with S/L ratio <1 in myocardial perfusion scintigraphy. The values obtained from echocardiography were as follows: IVSd = 10 mm, LVPWd = 9 mm

there were no differences in these indices between the HT and HCM groups. Furthermore, they have suggested that ASH is a type of HT LV hypertrophy in HT patients.^[1]

Amano *et al.* have conducted a study in order to evaluate the relationship between global and regional cardiac abnormalities in case of HCM with ASH, and delayed hyper-enhancement of the myocardium by using magnetic resonance imaging (MRI).^[17] According to the results of this study, it has been reported that delayed hyper-enhancement of the myocardium with extensive extent may reflect the hypokinesia and severe regional hypertrophy in HCM with ASH if it is higher than 50%.

According to a case presented by Raymond Ching-Chiew Wong *et al.*, it has been reported that a young man with heart failure and obesity cardiomyopathy presented with asymmetric septal hypertrophy, marked LV hypertrophy, and endomyocardial biopsy (EMB) defeated genetic HCM.^[18] Nevertheless, some studies suggest that obesity may be associated with larger LVMI, increased myocardial wall thickness, and diastolic dysfunction.^[19,20] However, in the present study, no significant difference was found between two groups in terms of body mass index values.

Although echocardiography is a more frequent method because of it is safe, rapid, reliable, and cost-effective for the evaluation of left ventricle size and functions, yet it may be inadequate especially in cases with limited echocardiographic window.^[21,22] However, echocardiographic images can change with the change in probe angle and measurements because they are operator-dependent.^[23] These situations are important for determining asymmetric septal hypertrophy in HT patients.

LVM should be accurately calculated but it may be difficult because of the heart angle, movement, and limited image. Therefore, it may require multimodal screening techniques. In our study, left ventricular wall thickness and mass in myocardial perfusion scintigraphy (MPS) were correlated with echocardiographic measurements. MPS also can be use for determining of left ventricle volumes and functions as well as myocardial perfusion. In this context, MPS has a complementary value in clinical practice. Enhanced septal activity should be reported and investigated in terms of hypertrophy.

The small population size is the major limitation of our study. Secondly because of the retrospective design of the study, echocardiographic evaluations were performed only by a two-dimensional technique. Three-dimensional echocardiographic measurements could better correlate with MPS.

Conclusion

Results of our study suggest that increased S/L ratio can be an indicator of asymmetric septal hypertrophy and/or LVH. Therefore, it should be noted that increased S/L ratio that can be monitored during myocardial perfusion scintigraphy can be an indicator of septal hypertrophy or/and LVH, however, further examination and close follow-ups should be performed in necessary cases.

Financial support and sponsorship

Nil

Conflicts of interest

There are no conflicts of interest.

References

1. Shimizu M, Sugihara N, Shimizu K, Yoshio H, Ino H, Nakajima K, *et al.* Asymmetrical septal hypertrophy in patients with hypertension: A type of hypertensive left ventricular hypertrophy or hypertrophic cardiomyopathy combined with hypertension? *Clin Cardiol* 1993;16:41-6.
2. Yokota Y, Teng SS, Emoto R, Miki T, Takarada A, Seo T, *et al.* Mechanism of development of asymmetric septal hypertrophy in patients with essential systemic hypertension. *Jpn Circ J* 1989;53:1173-84.
3. Yamada M, Teraoka K, Kawade M, Hirano M, Yamashina A. Frequency and distribution of late gadolinium enhancement in magnetic resonance imaging of patients with apical hypertrophic cardiomyopathy and patients with asymmetrical hypertrophic cardiomyopathy: A comparative study. *Int J Cardiovasc Imaging* 2009;25(Suppl 1):131-8.
4. Peer M, Boaz M, Zipora M, Shargorodsky M. Determinants of left ventricular hypertrophy in hypertensive patients: Identification of high-risk patients by metabolic, vascular, and inflammatory risk factors. *Int J Angiol* 2013;22:223-8.
5. Bajpai JK, AP S, AK A, AK D, Garg B, Goel A. Impact of prehypertension on left ventricular structure, function and geometry. *J Clin Diagn Res* 2014;8:BC07-10.
6. Bilge AK, Atilgan D, Onur I, Pamukcu B, Ozcan M, Adalet K. Relationship between left ventricular hypertrophy, hypertensive retinopathy, microalbuminuria and echocardiographic modalities in newly diagnosed hypertensive patients. *Int J Cardiovasc Imaging* 2010;26:405-12.
7. Han JC, Barrett CJ, Taberner AJ, Loisele DS. Does reduced myocardial efficiency in systemic hypertensive-hypertrophy correlate with increased left-ventricular wall thickness? *Hypertens Res* 2015;38:530-8.
8. Dobrowolski P, Prejbisz A, Klisiewicz A, Florczak E, Rybicka J, Januszewicz A, *et al.* Determinants of concentric left ventricular hypertrophy in patients with resistant hypertension: RESIST-POL study. *Hypertens Res* 2015;38:545-50.
9. Minoshima M, Noda A, Nishizawa T, Hara Y, Sugiura M, Iino S, *et al.* Endomyocardial radial strain imaging and left ventricular relaxation abnormalities in patients with hypertrophic cardiomyopathy or hypertensive left ventricular hypertrophy. *Circ J* 2009;73:2294-9.
10. Lang RM, Bierig M, Devereux RB, Flachskampf FA, Foster E, Pellika PA, *et al.*; Chamber Quantification Writing Group; American Society of Echocardiography's Guidelines and

- Standards Committee; European Association of Echocardiography. Recommendations for chamber quantification: A report from the American Society of Echocardiography's Guidelines and Standards Committee and the Chamber Quantification Writing Group, developed in conjunction with the European Association of Echocardiography, a branch of the European Society of Cardiology. *J Am Soc Echocardiogr* 2005;18:1440-63.
11. Foppa M, Duncan BB, Rohde LE. Echocardiography-based left ventricular mass estimation. How should we define hypertrophy? *Cardiovasc Ultrasound* 2005;3:17.
 12. Cuspidi C, Facchetti R, Bombelli M, Sala C, Grassi G, Mancia G. Differential value of left ventricular mass index and wall thickness in predicting cardiovascular prognosis: Data from the PAMELA population. *Am J Hypertens* 2014;27:1079-86.
 13. Ozturk C, Aparci M, Karaduman M, Balta S, Çelik T, İyisoy A. Relationship of systolic blood pressure and body mass index with left ventricular mass and mass index in adolescents. *Angiology* 2015. [Epub ahead of print].
 14. Laukkanen JA, Khan H, Kurl S, Willeit P, Karppi J, Ronkainen K, *et al.* Left ventricular mass and the risk of sudden cardiac death: A population-based study. *J Am Heart Assoc* 2014;3:e001285.
 15. Yang L, Qiu Q, Fang SH. Evaluation of left atrial function in hypertensive patients with and without left ventricular hypertrophy using velocity vector imaging. *Int J Cardiovasc Imaging* 2014;30:1465-71.
 16. Kitaoka H, Kuwahara T, Nishida K, Morimoto K, Kubo T, Okawa M, *et al.* Hypertrophic cardiomyopathy with progression from apical hypertrophy to asymmetrical septal hypertrophy: A case report. *J Cardiol Apr* 2005;45:155-9.
 17. Amano Y, Takayama M, Takahama K, Kumazaki T. Delayed hyper-enhancement of myocardium in hypertrophic cardiomyopathy with asymmetrical septal hypertrophy: Comparison with global and regional cardiac MR imaging appearances. *J Magn Reson Imaging* 2004;20:595-600.
 18. Wong RC, Tan KB. Asymmetric left ventricular hypertrophy associated with morbid obesity mimicking familial hypertrophic cardiomyopathy. *Singapore Med J* 2014;55:e201-4.
 19. de Simone G, Izzo R, De Luca N, Gerds E. Left ventricular geometry in obesity: Is it what we expect? *Nutr Metab Cardiovasc Dis* 2013;23:905-12.
 20. Brumback LC, Kronmal R, Heckbert SR, Ni H, Hundley WG, Lima JA, *et al.* Body size adjustments for left ventricular mass by cardiovascular magnetic resonance and their impact on left ventricular hypertrophy classification. *Int J Cardiovasc Imaging* 2010;26:459-68.
 21. Celebi AS, Yalcin H, Yalcin F. Current cardiac imaging techniques for detection of left ventricular mass. *Cardiovasc Ultrasound* 2010;8:19.
 22. Anderson JB, Grenier M, Edwards NM, Madsen NL, Czosek RJ, Spar DS, *et al.* Usefulness of combined history, physical examination, electrocardiogram, and limited echocardiogram in screening adolescent athletes for risk for sudden cardiac death. *Am J Cardiol* 2014;114:1763-7.
 23. Ducas R, Tsang W, Chong AA, Jassal DS, Lang RM, Leong-Poi H, *et al.* Echocardiography and vascular ultrasound: New developments and future directions. *Can J Cardiol* 2013;29:304-16.