

Uptake of ^{18}F -fluoro-2-deoxyglucose in the Healthy Testes of Young Men as Assessed by Positron Emission Tomography/Computed Tomography; Including the Inter- and Intra-observer Variation

A. Meij-de Vries, R. J. J. Knol, S. V. Lazarenko, R. W. Meijer, E. M. van der Plas, H. A. Heij

Department of Surgery, Medical Centre, Alkmaar, the Netherlands

Abstract

Knowledge of the physiological testicular accumulation of ^{18}F -fluoro-2-deoxyglucose (FDG) is essential in order to discriminate between normal and pathological findings. In this study, the ^{18}F -FDG-uptake in healthy testes of young men was assessed using positron emission tomography/computed tomography (PET/CT)-scans. A total of 40 testes of 20 men with a mean age of 26.5 ± 3.9 years were evaluated. ^{18}F -FDG-uptake was expressed as the standardized uptake value (SUV). Testicular volume was measured on CT and PET. All scans were assessed by three researchers, one of whom assessed every scan twice. Laterality indices and inter- and intra-observer variation were evaluated. Correlation between the SUV_{max} and SUV_{peak} between SUV_{mean} and SUV_{peak} and between age and SUV_{peak} were assessed. Testes showed an average SUV_{max} of 3.42 ± 0.61 , SUV_{peak} of 3.06 ± 0.54 and SUV_{mean} of 2.44 ± 0.44 . The average testicular volume on CT was 23.0 ± 6.4 ml, whereas on PET it was 18.0 ± 5.1 ml. Laterality indices were calculated of 0.077 ± 0.065 (SUV_{max}), 0.074 ± 0.066 (SUV_{peak}), 0.072 ± 0.063 (SUV_{mean}), 0.245 ± 0.259 (CT), and 0.200 ± 0.188 (PET), respectively. Inter- and intra-observer reliability were found to be perfect for the SUVs (intraclass correlation coefficient [ICC] 0.992-1.0), but poor for testicular volumes (ICC 0.854-0.902). Testicular ^{18}F -FDG uptake in young men can be measured accurately on PET/CT and shows high symmetry. Consequently, ^{18}F -FDG PET/CT has the potential to become a useful instrument in the evaluation of the functioning of the individual testis.

Keywords: ^{18}F -fluoro-2-deoxyglucose-positron emission tomography/computed tomography scan, inter- and intra-observer variability, laterality index, physiological uptake, testis

Introduction

^{18}F -fluoro-2-deoxyglucose (FDG) positron emission tomography (PET) imaging in combination with computed tomography (CT) is mainly used to assess malignant lesions.^[1]

However, in normal tissue ^{18}F -FDG also accumulates in various degrees.^[2] It is essential to know what this

physiological uptake is, in order to discriminate between normal and pathological findings. Moreover, testicular ^{18}F -FDG uptake correlates positively with the main sperm parameters and is likely to be a promising parameter for testis function.^[3]

In testicular tissue, normal ^{18}F -FDG uptake has been studied in men over the age of 35 and in a pediatric study population.^[4-6] However, data on men between the ages of 18 and 32 years and on the reliability of the ^{18}F -FDG uptake measurements are lacking.

Therefore, the aim of this study is to measure the physiological testicular ^{18}F -FDG uptake in young men and to assess the usability of these measurements by calculating the laterality indices and the inter- and intra-observer variation.

Access this article online

Quick Response Code:



Website:
www.wjnm.org

DOI:
10.4103/1450-1147.139137

Address for correspondence:

Annebeth Meij-de Vries, Medical Centre, Alkmaar, E-mail: a.de.vries@mca.nl

Materials and Methods

Study population

During the period of January 2012 to April 2013, a total of 1555 men underwent a diagnostic whole body FDG-PET/CT scan in our hospital. In the age group of our interest (18–32 years), 20 scans (40 testes) were performed on men with a mean age of 26.5 ± 3.9 years (range: 19.3–31.2 years). All PET/CT scans were carried out with the same type of scanner. Indications for the diagnostic whole body FDG-PET/CT scans included Hodgkin's disease (8), suspicion of malignancy (4), colon carcinoma (3), sarcoidosis (2), tuberculosis (1), B-cell lymphoma (1), and a suspicion of endocarditis (1). None of the patients had a history of undescended testis or showed any abnormality of the testes on the PET/CT scan.

Each patient gave written informed consent for the evaluation of their PET/CT data for scientific research.

¹⁸F-fluoro-2-deoxyglucose positron emission tomography/computed tomography scan

Whole-body ¹⁸F-FDG PET/CT scanning was performed using a Biograph 16 TruePoint PET/CT scanner (Siemens Healthcare, Knoxville, USA).

All 20 patients had a blood glucose level below 10 mmol/l and received an intravenous injection of FDG. The average injected dose was 4.7 MBq/kg body weight (range: 2.4–6.4 MBq/kg), and the average time between FDG administration and the start of the PET acquisition was 62 min (range: 44–74 min).

In 10 patients, a low-dose CT scan was performed for localization and attenuation correction purposes. Scanning parameters included 50 reference mAs and 130 kV with 4D Care Dose (Siemens Healthcare, Knoxville, USA). No intravenous contrast was administered to these patients. A diagnostic CT total body with 110 reference mAs and 110 or 130 kV with 4D Care Dose was acquired for the other 10 patients, and these patients were given intravenous contrast.

For PET scanning, a three-dimensional emission scan was acquired with 6 or 7 bed position (195 and 225 transaxial images, respectively), using 4 min/bed position. Images with CT-based attenuation correction were reconstructed, using ordered subset expectation maximization three-dimensional reconstruction with fourth iterations, eight subsets, a Gaussian postsmoothing filter of 5 mm, 168×168 matrix, pixel size $4.07 \text{ mm} \times 4.07 \text{ mm}$, and slice thickness 5 mm.

Image analysis and parameters

Images [Figure 1] were interpreted on syngo. via VA20A equipped workstations, using the MM Oncology

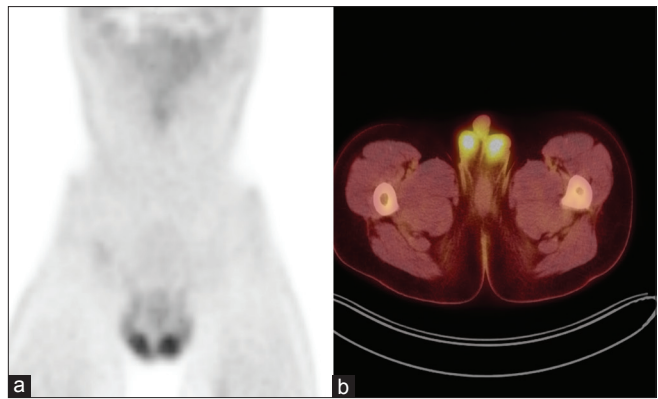


Figure 1: Example of positron emission tomography/computed tomography images in a patient with symmetric testicular uptake of fluoro-2-deoxyglucose, coronal (a) and axial (b)

software package (version 1.0; Siemens Healthcare, Erlangen, Germany), which can display CT, PET, and fused PET/CT images simultaneously.

In order to measure testicular volume by CT, the testes were selected semi-automatically using the generic segmentation tool in this software package. The resulting selected area was checked visually in all orthogonal planes (slice thickness 2 mm) and reshaped manually in case of obvious errors. Subsequently, the testicular volumes were calculated automatically by summing the volume estimates from the selected areas in each slice.

Standardized uptake values were calculated from the PET images as the ratio of the activity (kBq) in tissue per milliliter to the activity in the injected dose (MBq) per patient body weight in kilogram. Volume of interests (VOIs) were selected on the PET images using the VOI isocontour tool in the oncology software package mentioned above, with a threshold of 50%. Spheres were placed manually around each testis on the three-dimensional PET images and rotated to the correct orientation of the testis. Within the resulting isocontour, SUV_{max} (SUV of a single pixel with highest uptake in the VOI), SUV_{peak} (mean SUV of 1 cm^3 with highest uptake in VOI), SUV_{mean} (mean SUV in whole VOI) and the volume of the VOI were measured and recorded.

All scans were assessed by three researchers (observer 1, 2, and 3), one of them assessed every scan twice (observer 3^a and 3^b).

Statistical analysis

All data were managed and analyzed with SPSS, version 14.0 (SPSS Inc, Chicago, Ill). The laterality index was defined as $(|L - R| / (L + R) \times 2)$, where L = left testicular SUV and R = right testicular SUV.^[5] The intraclass correlation coefficient (ICC) was used to evaluate

inter- and intra-observer variability; the ICC is 1.0 if there is a perfect reliability. Furthermore, linear regression was used to calculate the exact correlation between the three different researchers (interobserver variation) and between the first and second assessment of one of the researchers (intraobserver variation).^[7,8] A correlation coefficient (r) >0.7 was regarded as a good correlation. Linear regression was expressed as $Y = a + bx$, where the intercept (a) is 0 and the slope (b) is 1 if there is a perfect correlation. The correlations between the SUV_{max} and SUV_{peak} between SUV_{mean} and SUV_{peak} and between age and SUV_{peak} were assessed with linear regression and the Pearson's correlation coefficient test. $P < 0.05$ was considered as statistically significant.

Results

Table 1 shows the mean and laterality indices of the SUV_{max} , SUV_{peak} and SUV_{mean} testicular volume on CT and VOI of the 40 healthy testes in young men.

Inter- and intra-observer reliability

The interobserver ICCs (+95% confidence interval [CI]) of the SUV_{max} , SUV_{peak} and SUV_{mean} testicular volume on CT, and VOI are shown in Table 2. The interobserver ICC for the testicular volumes on CT with contrast ($n = 10$)

Table 1: Mean±SD and range of SUV_{max} , SUV_{peak} , SUV_{mean} , TV on CT and VOI and their laterality indices measured by three researchers on 20 ¹⁸FDG-PET/CT scans of young men with 40 healthy testes

	Mean±SD	Range	Laterality index mean±SD	Range
SUV_{max}	3.42±0.61	2.07-4.82	0.077±0.065	0-0.192
SUV_{peak}	3.06±0.54	1.81-4.14	0.074±0.066	0-0.228
SUV_{mean}	2.44±0.44	1.40-3.37	0.072±0.063	0-0.248
TV _{CT}	23.0±6.4	10.2-42.8	0.245±0.259	0-1.054
VOI	18.0±5.1	9.0-33.8	0.200±0.188	0-0.791

SUV : Standardized uptake value; TV_{CT} : Testicular volume measured by CT (ml); VOI: Volume of interest (ml); SD: Standard deviation; CT: Computed tomography; ¹⁸FDG: ¹⁸F-fluoro-2-deoxyglucose; PET: Positron emission tomography

Table 2: Interobserver and intraobserver variability of SUV_{max} , SUV_{peak} , SUV_{mean} , TV on CT and VOI measured on 20 ¹⁸FDG-PET/CT scans of young men with 40 normal testes, expressed as ICC

	ICC (95% CI)	
	Interobserver variability	Intraobserver variability
SUV_{max}	0.997 (0.996-0.999)	1.0 (1.0-1.0)
SUV_{peak}	1.0 (1.0-1.0)	0.999 (0.999-1.0)
SUV_{mean}	0.997 (0.995-0.998)	0.992 (0.985-0.996)
TV _{CT}	0.854 (0.753-0.918)	0.916 (0.841-0.955)
VOI	0.883 (0.803-0.934)	0.902 (0.815-0.948)

SUV : Standardized uptake value; TV_{CT} : Testicular volume measured by CT (ml); VOI: Volume of interest (ml); SD: Standard deviation; CT: Computed tomography; ICC: Intraclass correlation coefficient; ¹⁸FDG: ¹⁸F-fluoro-2-deoxyglucose; PET: Positron emission tomography; CI: Confidence interval

was 0.890 (0.768-0.953) and for the CT scans without contrast ($n = 10$) 0.805 (0.589-0.917).

Also shown in Table 2 are the intraobserver ICCs (+95% CI) of the SUV_{max} , SUV_{peak} and SUV_{mean} testicular volume on CT, and VOI. The intraobserver ICC for the testicular volumes on CT with contrast ($n = 10$)

Table 3a: Interobserver (A) and intraobserver (B) variability of SUV_{max} , SUV_{peak} , SUV_{mean} , TV on CT and VOI measured on 20 ¹⁸FDG-PET/CT scans of young men with 40 normal testes, calculated by linear regression and expressed as correlation coefficient (r), intercept (a) and slope (b)

	Correlation coefficient (r)	Intercept (a)	Slope (b)
SUV_{max}			
Obs1 vs Obs2	0.989	-0.081	1.025
Obs1 vs Obs3	0.991	-0.065	1.023
Obs2 vs Obs3	0.998	0.032	0.993
SUV_{peak}			
Obs1 vs Obs2	1.0	0.004	0.999
Obs1 vs Obs3	0.999	-0.011	1.002
Obs2 vs Obs3	0.999	-0.015	1.003
SUV_{mean}			
Obs1 vs Obs2	0.997	-0.020	0.998
Obs1 vs Obs3	0.988	-0.012	1.023
Obs2 vs Obs3	0.989	0.015	1.022
TV _{CT}			
Obs1 vs Obs2	0.588	8.008	0.701
Obs1 vs Obs3	0.744	0.964	1.034
Obs2 vs Obs3	0.688	4.915	0.802
VOI			
Obs1 vs Obs2	0.810	4.102	0.851
Obs1 vs Obs3	0.611	4.517	0.616
Obs2 vs Obs3	0.724	2.133	0.694

SUV : Standardized uptake value; Obs: Observer; TVCT: Testicular volume measured by CT (ml); VOI: Volume of interest (ml); CT: Computed tomography; ¹⁸FDG: ¹⁸F-fluoro-2-deoxyglucose; PET: Positron emission tomography

Table 3b: Interobserver (A) and intraobserver (B) variability of SUV_{max} , SUV_{peak} , SUV_{mean} , TV on CT and VOI measured on 20 ¹⁸FDG-PET/CT scans of young men with 40 normal testes, calculated by linear regression and expressed as correlation coefficient (r), intercept (a) and slope (b)

	Correlation coefficient (r)	Intercept (a)	Slope (b)
SUV_{max}			
Obs3 ^a vs Obs3 ^b	1.0	0	1.0
SUV_{peak}			
Obs3 ^a vs Obs3 ^b	0.999	0.017	0.996
SUV_{mean}			
Obs3 ^a vs Obs3 ^b	0.986	0.117	0.946
TV _{CT}			
Obs3 ^a vs Obs3 ^b	0.845	2.836	0.847
VOI			
Obs3 ^a vs Obs3 ^b	0.827	2.993	0.930

SUV : Standardized uptake value; Obs: Observer; TVCT: Testicular volume measured by CT (ml); VOI: Volume of interest (ml); CT: Computed tomography; ¹⁸FDG: ¹⁸F-fluoro-2-deoxyglucose; PET: Positron emission tomography

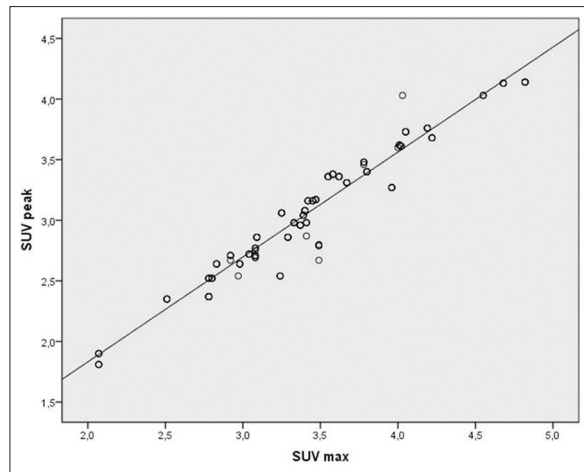


Figure 2: Strong positive correlation between the standardized uptake value (SUV)_{max} and SUV_{peak} of the ¹⁸fluoro-2-deoxyglucose-positron emission tomography/computed tomography imaging of young men with 40 normal testes and four measurements. $r = 0.973$; $Y = 0.07 + 0.97x$; $P < 0.0001$

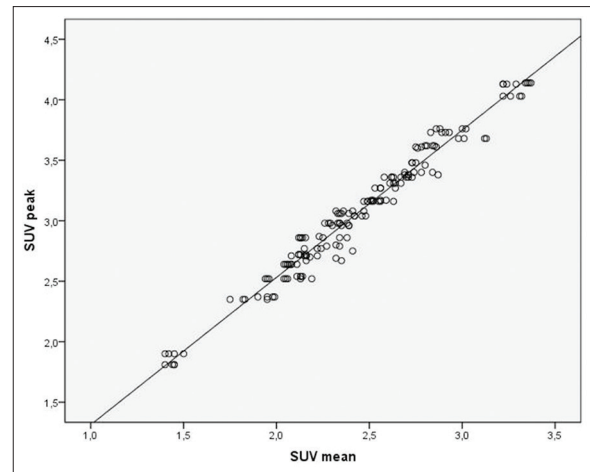


Figure 3: Strong positive correlation between the standardized uptake value (SUV)_{mean} and SUV_{peak} of the ¹⁸fluoro-2-deoxyglucose-positron emission tomography/computed tomography imaging of young men with 40 normal testes and four measurements. $r = 0.984$; $Y = 0.1 + 0.98x$; $P < 0.0001$

was 0.893 (0.729-0.958) and for the CT scans without contrast ($n = 10$) 0.934 (0.832-0.974).

The exact inter- and intra-observer correlation as measured by linear regression for all parameters is presented in Table 3.

Correlation between standardized uptake value (SUV_{max}) and SUV_{peak}

There was a significant, strong positive correlation between the SUV_{max} and SUV_{peak}; $r = 0.973$; $Y = 0.07 + 0.97x$, $P < 0.0001$ [Figure 2].

Correlation between standardized uptake value (SUV_{mean}) and SUV_{peak}

There was a significant, strong positive correlation between the SUV_{mean} and SUV_{peak}; $r = 0.984$; $Y = 0.1 + 0.98x$, $P < 0.0001$ [Figure 3].

Correlation between age and standardized uptake value_{peak}

There was a significant, weak positive correlation between age and the SUV_{peak}. $r = 0.349$; $Y = 1.7 + 0.35x$, $P < 0.0001$ [Figure 4].

Discussion

In this study, on testicular ¹⁸F-FDG uptake on PET/CT in a population of young men, we found a high inter- and intra-observer reliability in assessing the SUV_{max} as well as the SUV_{peak} and the SUV_{mean}. Further, these SUV values had low laterality indices and correlated well with each other. Furthermore, the correlation between the SUV_{peak} and age was weak.

In their study, Kosuda *et al.* they found a testicular SUV ranging from 1.90 to 3.34 (average; 2.44 ± 0.53), Kitajima *et al.* have reported a mean SUV_{max} of 2.81 ± 0.43 in the age group of 30–39, and the highest mean SUV_{mean} Goethals *et al.* found in a pediatric population was 1.4.^[4-6] Absolute uptake values such as SUVs are known to be affected by many technical and physiological factors. Therefore, measurements from different studies cannot reliably be compared.^[9-11] Nevertheless, the positive correlation ($r = 0.406$, $P = 0.005$) between age and the SUV_{mean} described by Goethals *et al.* have been interpreted as not in line with the negative correlation ($r = -0.284$, $P < 0.0001$) between age and SUV_{max} that Kitajima *et al.* described from the age of 36. In our study, we interpreted the positive correlation between age and SUV_{peak} ($r = 0.349$; $Y = 1.7 + 0.35x$; $P < 0.0001$) as significant, but weak.

Although Goethals *et al.* interpreted their results as not in line with the results of Kitajima *et al.*, the reverse correlation may be a consequence of the maturation of testes in child- and adulthood and on the other hand, the aging of the testes with deterioration of the Leydig cells during the second part of a man's life.^[12,13] Our finding of a significant, but weak correlation between age (19.3–32.2 years) and SUV_{peak} supports this theory since in our age group testicles are mature, but do not alter yet.

Furthermore, in this study, we found that the laterality of testicular ¹⁸F-FDG uptake is low: the laterality indices for SUV_{max}, SUV_{peak} and SUV_{mean} were 0.077 ± 0.065 , 0.074 ± 0.066 , and 0.072 ± 0.063 , respectively. These findings are comparable with the laterality indices of the SUV_{max} reported by Kitajima *et al.* (0.066 ± 0.067).^[5] This implies that the SUVs are comparable for bilateral

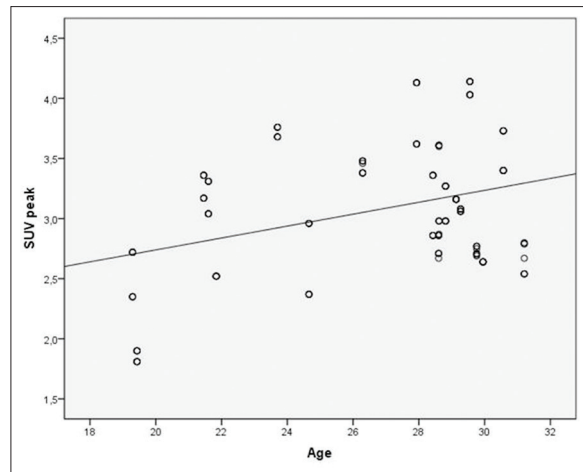


Figure 4: Weak positive correlation between the age and standardized uptake value_{peak} of the ¹⁸fluoro-2-deoxyglucose-positron emission tomography/computed tomography imaging of young men with 40 normal testes and four measurements. $r = 0.349$; $Y = 1.75 + 0.35x$; $P < 0.0001$

testes; there is high symmetry in healthy testes and that a higher laterality index (for instance > 0.15) may be an indication for a pathologic process.

In addition, inter- and intra-observer variability were evaluated. There was a weak inter- and intra-observer reliability in the testicular volumes measured on CT (with or without contrast) as well as in the VOI on the PET/CT. Moreover, the correlation between both parameters was moderate ($r = 0.513$; $Y = 11.5 + 0.5x$; $P < 0.0001$). This leads to the conclusion that testicular volume is an unreliable parameter to evaluate using a PET/CT scan. However, all standard uptake values (max, peak and mean) showed a very good inter- and intra-observer repeatability. SUV_{max} corresponds with the single pixel with the highest ¹⁸F-FDG uptake in the VOI and is of particular value in PET/CT images of high statistical quality.^[14] SUV_{peak} , which represents the mean SUV of the 1 cm³ with the highest ¹⁸F-FDG uptake in the VOI, provides a slightly more robust alternative. The ICCs of inter- and intra-observer variability are 1.0 and 0.999, respectively; therefore, the SUV_{peak} seems a perfectly reliable parameter. This parameter has an average \pm standard deviation of 3.06 ± 0.54 , a laterality index of 0.074 ± 0.066 and good correlations with SUV_{max} ($r = 0.973$; $Y = 0.07 + 0.97x$; $P < 0.0001$) and SUV_{mean} ($r = 0.984$; $Y = 0.1 + 0.98x$; $P < 0.0001$); as a result, the SUV_{peak} appears to be an ideal parameter for the evaluation of testicular ¹⁸F-FDG uptake.

The limitations of this study need to be addressed. First, number of scans (20) and testes (40) is relatively small. Since January 2012 a new scanner has been in use and as the scanner might influence the SUVs, it was decided to include only the PET/CT scans made on this new scanner.

Besides, scans were included only of men in the age group of our interest (18–32 years). These two inclusion criteria limited number of scans to 20, with 40 testes.

Second, this was a retrospective study. Testes were not placed in a proper position and in some cases both testes were in contact with each other which hampered the automatic detection of the testis with the generic segmentation tool on CT. Further, although the scans were performed on the same scanner, there were some differences in the scanning protocol. For example, intravenous contrast agent was used in half the scans, whereas in the other half no contrast agent was administered. Analysis showed a significantly higher SUV_{max} in the group with contrast agent compared with the group without contrast agent (3.57 ± 0.6 vs. 3.27 ± 0.58 ; $P = 0.034$), but no significant differences were found between both groups for the SUV_{peak} (3.17 ± 0.55 vs. 2.95 ± 0.51 ; $P = 0.1$) and SUV_{mean} (2.53 ± 0.44 vs. 2.34 ± 0.42 ; $P = 0.07$). The retrospective character of this study may have caused some inaccuracy in the results and can be improved in a future prospective study with a proper positioning of both testes and one single scanning protocol.

Third, our study population contained a group of men with a variety of diseases with corresponding (chemo) therapies. Because an excess of FDG is given before scanning, cancerous or otherwise pathologic tissue does not compromise the FDG uptake of normal tissue, that is, testicles. The influence of chemotherapy on testicular FDG uptake has been studied by Burger *et al.*^[15] They found no absolute or relative change in testicular FDG uptake after starting or during systemic chemotherapy for Hodgkin's lymphoma. Furthermore, no involvement of the testes in the pathology of our study population had been diagnosed. Furthermore, no other testicular abnormalities were seen on the PET/CT scans. Overall, we believe that there was no influence of diseases with the corresponding therapies in our study population on the measured SUV values.

In short, SUV measurements with PET/CT of testicular ¹⁸F-FDG uptake seem reliable with a low inter- and intra-observer variability and high symmetry in young men with normal testes. SUV_{peak} seems to be the best parameter to use in the evaluation of this uptake. Consequently, the PET/CT seems a promising new method to evaluate testicular function, and this conclusion is supported by recently published data on the positive correlation between the rate of testicular ¹⁸F-FDG uptake and sperm parameters.^[3] The PET/CT scan will enable us to discriminate between the functioning of both bilateral testes. Therefore, it will overcome an important limitation of the main fertility parameters used previously, such as semen analysis or paternity.^[16] For example, the testicular ¹⁸F-FDG uptake

measured on PET/CT might become an important parameter in the evaluation of the functioning of previously unilateral orchidopexied testes.

Conclusion

Testicular ^{18}F -FDG uptake in young men can be measured accurately using PET/CT, with a low inter- and intra-observer variability and shows high symmetry. ^{18}F -FDG PET/CT has the potential to become a useful instrument in the evaluation of the functioning of the individual testis.

References

1. Bar-Shalom R, Yefremov N, Guralnik L, Gaitini D, Frenkel A, Kuten A, *et al.* Clinical performance of PET/CT in evaluation of cancer: Additional value for diagnostic imaging and patient management. *J Nucl Med* 2003;44:1200-9.
2. Zincirkeser S, Sahin E, Halac M, Sager S. Standardized uptake values of normal organs on ^{18}F -fluorodeoxyglucose positron emission tomography and computed tomography imaging. *J Int Med Res* 2007;35:231-6.
3. Dierickx LO, Huyghe E, Nogueira D, Zerdoud S, Filleron T, Brillouet S, *et al.* Functional testicular evaluation using PET/CT with ^{18}F -fluorodeoxyglucose. *Eur J Nucl Med Mol Imaging* 2012;39:129-37.
4. Kosuda S, Fisher S, Kison PV, Wahl RL, Grossman HB. Uptake of 2-deoxy-2- ^{18}F fluoro-D-glucose in the normal testis: Retrospective PET study and animal experiment. *Ann Nucl Med* 1997;11:195-9.
5. Kitajima K, Nakamoto Y, Senda M, Onishi Y, Okizuka H, Sugimura K. Normal uptake of ^{18}F -FDG in the testis: An assessment by PET/CT. *Ann Nucl Med* 2007;21:405-10.
6. Goethals I, De Vriendt C, Hoste P, Smeets P, Ham H. Normal uptake of F-18 FDG in the testis as assessed by PET/CT in a pediatric study population. *Ann Nucl Med* 2009;23:817-20.
7. Huang YE, Chen CF, Huang YJ, Konda SD, Appelbaum DE, Pu Y. Interobserver variability among measurements of the maximum and mean standardized uptake values on (18) F-FDG PET/CT and measurements of tumor size on diagnostic CT in patients with pulmonary tumors. *Acta Radiol* 2010;51:782-8.
8. Marom EM, Munden RE, Truong MT, Gladish GW, Podoloff DA, Mawlawi O, *et al.* Interobserver and intraobserver variability of standardized uptake value measurements in non-small-cell lung cancer. *J Thorac Imaging* 2006;21:205-12.
9. Boellaard R, Krak NC, Hoekstra OS, Lammertsma AA. Effects of noise, image resolution, and ROI definition on the accuracy of standard uptake values: A simulation study. *J Nucl Med* 2004;45:1519-27.
10. Boellaard R. Standards for PET image acquisition and quantitative data analysis. *J Nucl Med* 2009;50 Suppl 1:11S-20.
11. Park HH, Park DS, Kweon DC, Lee SB, Oh KB, Lee JD, *et al.* Inter-comparison of ^{18}F -FDG PET/CT standardized uptake values in Korea. *Appl Radiat Isot* 2011;69:241-6.
12. Chen H, Ge RS, Zirkin BR. Leydig cells: From stem cells to aging. *Mol Cell Endocrinol* 2009;306:9-16.
13. Midzak AS, Chen H, Papadopoulos V, Zirkin BR. Leydig cell aging and the mechanisms of reduced testosterone synthesis. *Mol Cell Endocrinol* 2009;299:23-31.
14. Lodge MA, Chaudhry MA, Wahl RL. Noise considerations for PET quantification using maximum and peak standardized uptake value. *J Nucl Med* 2012;53:1041-7.
15. Burger IA, Vargas HA, Goldman DA, Gonen M, Kumar A, Zelenetz AD, *et al.* The impact of systemic chemotherapy on testicular FDG activity in young men with Hodgkin's lymphoma. *Eur J Nucl Med Mol Imaging* 2013;40:701-7.
16. van Brakel J, Kranse R, de Muinck Keizer-Schrama SM, Hendriks AE, de Jong FH, Bangma CH, *et al.* Fertility potential in men with a history of congenital undescended testes: A long-term follow-up study. *Andrology* 2013;1:100-8.

How to cite this article: Meij-de Vries A, Knol R, Lazarenko SV, Meijer RW, van der Plas EM, Heij HA. Uptake of ^{18}F -fluoro-2-deoxyglucose in the Healthy Testes of Young Men as Assessed by Positron Emission Tomography/Computed Tomography; Including the Inter- and Intra-observer Variation. *World J Nucl Med* 2014;13:88-93.

Source of Support: Nil, **Conflict of Interest:** None declared.