

Case report

Persistent High Grade Flurodeoxyglucose Uptake in Lipomatous Hypertrophy of the Interatrial Septum on Dual Time Point Imaging and with Ambient Warming

K. K. Kamaleshwaran, N. Sudhakar¹, D. K. Shibu, E. R. R. Kurup, Ajit Shinto

Departments of Nuclear Medicine and ¹Medical Oncology, Kovai Medical Centre and Hospital, Coimbatore, Tamil Nadu, India

Abstract

Lipomatous hypertrophy of the interatrial septum (LHIS) is a relatively uncommon disorder of the heart characterized by benign fatty infiltration of the interatrial septum that usually spares the fossa ovalis. LHIS showing flurodeoxyglucose uptake has been reported, and is presumed to be due to activated brown adipose tissue (BAT). We here report a case of a patient who had isolated mediastinal uptake in interatrial septum, mimicking metastasis. Rescanning with external warming to deactivate BAT and a delayed time point image was done, which showed persistent and progressively increasing metabolic uptake respectively, suggesting that LHIS uptake might be unrelated to activated BAT or inflammation.

Keywords: Brown adipose tissue, flurodeoxyglucose positron emission tomography computed tomography, lipomatous hypertrophy

Introduction

LHIS is a histologically benign process in which adipose tissue, a normal component of the interatrial septum, increases and infiltrates between the myocardial fibers. LHIS usually is detected as an incidental finding on echocardiography, and the estimated prevalence is 1% at autopsy, 2-8% on echocardiography^[1], and 2.2% on MDCT.^[2] Knowledge of the frequency and features of LHIS on CT and FDG-PET is important in the primary staging of patients with malignancy. In patients with cancer, the false interpretation of FDG uptake in LHIS as metastatic disease would stage a patient as having mediastinal disease. This false interpretation, in a

patient who otherwise had absent or local nodal involvement, would mean that the patient would not receive appropriate curative therapy.^[3,4] We here report a follow up case of a patient with ovarian cancer who had isolated mediastinal uptake in interatrial septum, mimicking metastasis. Rescanning with external warming to deactivate BAT and a delayed time point image was done, which showed persistent and progressively increasing metabolic uptake respectively, suggesting that LHIS uptake might be unrelated to activated BAT or inflammation.

Case Report

The case we present here is about a patient 66-year-old woman presented with a history of Stage II ovarian cancer, postsurgical status, and on follow-up. She was evaluated with a whole body F18 flurodeoxyglucose (FDG) positron emission tomography-computed tomography (PET-CT) to assess residual disease and metastases. Initial whole body PET-CT done after 45 min of an injection of a standard dose of F-18 FDG demonstrated isolated mediastinal

Access this article online

Quick Response Code:



Website:
www.wjnm.org

DOI:
10.4103/1450-1147.138577

Address for correspondence:

Dr. Ajit Shinto, Kovai Medical Centre and Hospital, PB 3209, Avanashi Road, Coimbatore - 641 014, Tamil Nadu, India. E-mail: ajitshinto@gmail.com

uptake, localized to the inter atrial septum with fat density on CT. As the reason for focal increased FDG uptake was hypothesized to be either activated brown adipose tissue (BAT) or inflammation, the scan was repeated on another day with external warming of the patient for 4 h before injection. A delayed time point scan of the chest was also done to assess wash out of the tracer, which would have favored inflammation. However, both the images demonstrated persistent increased FDG uptake, suggesting that the focal hyper metabolism is not related to activate BAT, or there is another pathway of activation other than low temperature. Furthermore, the progressively increased FDG accumulation suggests that it is unlikely to be a purely inflammatory etiology either as has been suggested.^[1]

Discussion

The prevalence of lipomatous hypertrophy of the interatrial septum (LHIS) is estimated to be between 1% and 8%. LHIS has been shown to cause electrocardiography changes, atrial arrhythmias, recurrent pericardial effusions and rarely sudden cardiac death.^[2] The specific CT appearance of fat in combination with the characteristic FDG uptake of the atrial septum on PET confirms the diagnosis.^[3] The increased FDG uptake on PET scan is believed to occur due to the presence of brown fat in LHIS, resulting in a false interpretation of malignancy. It is an important to recognize that increased FDG uptake in benign processes potentially can mimic malignancy either in adjacent lymph nodes or in the myocardium. False interpretation of increased FDG uptake as neoplasm in LHIS would stage a patient with malignancy inappropriately as having a metastasis and potentially result in suboptimal therapy.^[4,5] Fusion PET/CT helps clarify the region of localized FDG uptake and confirm that it lies in the region of LHIS rather than the adjacent right hilum, mediastinum, or pleura. Representative images including PET, CT and fusion are given in Figures 1 and 2.

The reason why LHIS avidly accumulates FDG has been the subject of debate. The accepted views are that it is due to activated BAT, presence of inflammation or cardiomyocytes. Activation of BAT is usually due to cold temperature and persistent external warming has been shown to deactivate BAT and reduce FDG uptake. Inflammatory uptake in lesions is usually confirmed with a washout of FDG on delayed imaging. The present case does not demonstrate a decrease in uptake, both on external warming and on delayed imaging suggesting an alternate explanation for FDG accumulation in LHIS. Else, there could be an alternate pathway for BAT activation.

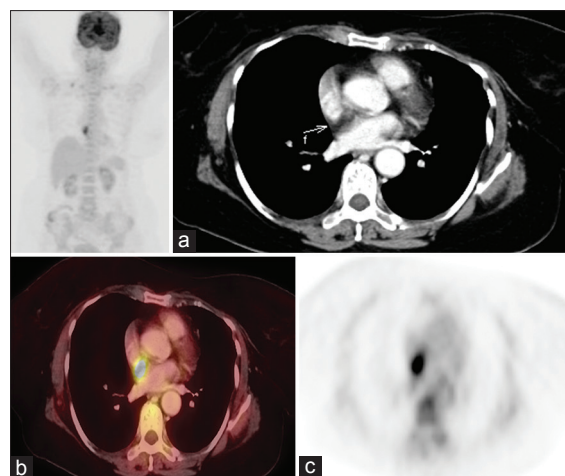


Figure 1: Focal 18F-fluorodeoxyglucose activity with standardized uptake value measuring 14 was noted in the mediastinum on wholebody positron emission tomography/ computed tomography. (a) An unenhanced axial computed tomography scan with an arrow showing the fat density in the interatrial septum. (b) Axial fused and (c) Axial positron emission tomography image

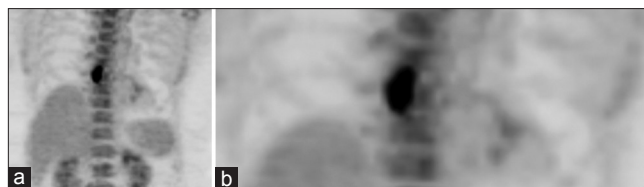


Figure 2: (a) Regional flurodeoxyglucose (FDG) positron emission tomography-computed tomography (PET-CT) of the chest done on another day after 4 hour external warming and intra venous injection of a standard dose of F18 FDG, demonstrates persistent intense FDG uptake with an standardized uptake value (SUV) max of 14.6, (b) Delayed time point PET CT of the chest was done 1 hour after the initial image post warming, demonstrating progressive increase in FDG uptake and SUV max of 16.2

References

1. Zukotynski KA, Israel DA, Kim CK. FDG uptake in lipomatous hypertrophy of the interatrial septum is not likely related to brown adipose tissue. *Clin Nucl Med* 2011;36:767-9.
2. Heyer CM, Kagel T, Lemburg SP, Bauer TT, Nicolas V. Lipomatous hypertrophy of the interatrial septum: A prospective study of incidence, imaging findings, and clinical symptoms. *Chest* 2003;124:2068-73.
3. Meaney JF, Kazerooni EA, Jamadar DA, Korobkin M. CT appearance of lipomatous hypertrophy of the interatrial septum. *AJR Am J Roentgenol* 1997;168:1081-4.
4. Fukuchi K, Ohta H, Matsumura K, Ishida Y. Benign variations and incidental abnormalities of myocardial FDG uptake in the fasting state as encountered during routine oncology positron emission tomography studies. *Br J Radiol* 2007;80:3-11.
5. Fan CM, Fischman AJ, Kwek BH, Abbara S, Aquino SL. Lipomatous hypertrophy of the interatrial septum: Increased uptake on FDG PET. *AJR Am J Roentgenol* 2005;184:339-42.

How to cite this article: Kamaleshwaran KK, Sudhakar N, Shibu DK, Kurup E, Shinto A. Persistent High Grade Flurodeoxyglucose Uptake in Lipomatous Hypertrophy of the Interatrial Septum on Dual Time Point Imaging and with Ambient Warming. *World J Nucl Med* 2014;13:62-3.

Source of Support: Nil, **Conflict of Interest:** None declared