

Distal extension mandibular removable partial denture with implant support

Canan Bural¹, Begum Buzbas¹, Sebnem Ozatik¹, Gulsen Bayraktar¹, Yusuf Emes²

Correspondence: Dr. Canan Bural
Email: cbural@istanbul.edu.tr

¹Department of Prosthodontics, Istanbul University Faculty of Dentistry, Istanbul, Turkiye,

²Department of Oral and Maxillofacial Surgery, Istanbul University Faculty of Dentistry, Istanbul, Turkiye

ABSTRACT

This case report describes the fabrication of a distal extension removable partial denture (RPD) of a 65-year-old man with implant support. Loss of fibroelasticity of the peripheral tissues and reduced mandibular vestibular sulcular depth due to a previous surgical resection and radiotherapy at the right side were the main clinical factors that created difficulty for denture retention and stability. The fabrication of a mandibular RPD supported by anterior teeth and two bilaterally placed implants in the molar area to convert from Kennedy Class 1 design to Kennedy Class 3 implant-bounded RPD is reported. Retention and stability of the denture were improved with implant support on the distal extension site of the RPD. The common clinical problems about distally extended RPDs are lack of retention and stability due to the movement around the rotational axis. Dental implant placement to the distal edentulous site minimizes the potential dislodgement of the RPD is popular. Implant-supported RPD can be suggested as an advantageous and cost-effective treatment option for the partially edentulous patients.

Key words: Dental implant, distal-extension removable partial denture, implant-supported removable partial denture, Kennedy Class I partial edentulous, lower attachment

INTRODUCTION

Common clinical problems about distal extension removable partial dentures (RPDs) are lack of retention and stability and unaesthetic appearance because of the clasps.^[1-6]

Placing bilateral single dental implants in the molar area of the residual alveolar ridges is becoming a popular treatment choice while implants would effectively change the Kennedy Class 1 situation to a more favorable implant-supported Kennedy Class 3 configuration.^[2,4,5,7-9] The retention and stability of the dentures are being improved with placing the implants bilaterally.^[1,2,4] Moreover, implant support decreases the resorption of the alveolar ridges and

the need of relining procedures in the following years.^[10-12] As a result, this treatment modality could resolve intrusion movement problem of the RPD while reducing treatment costs compare with implant-supported fixed prosthesis and resulting in greater patient satisfaction.^[2,4,5]

There are different types of connection between the implants and the acrylic base of the RPD, such as implant cover screws, stress-breaking attachments, and healing caps.^[1-9,12] Ball, locator or ERA attachments are the different types of stress-breaking attachments that have been applied to the implants in previous studies and some case reports.^[1-6,8-14] In addition,

This is an open access article distributed under the terms of the Creative Commons Attribution-NonCommercial-ShareAlike 3.0 License, which allows others to remix, tweak, and build upon the work non-commercially, as long as the author is credited and the new creations are licensed under the identical terms.

For reprints contact: reprints@medknow.com

How to cite this article: Bural C, Buzbas B, Ozatik S, Bayraktar G, Emes Y. Distal extension mandibular removable partial denture with implant support. Eur J Dent 2016;10:566-70.

DOI: 10.4103/1305-7456.195180

Access this article online	
<p>Quick Response Code:</p> 	<p>Website: www.eurjdent.com</p>

placement of only healing caps to function as vertical stopping has previously been reported.^[1,4-6,8]

This clinical report describes a mandibular implant-supported RPD in a patient who had tumor surgery and radiotherapy using a conventional RPD with lack of retention and stability.

CASE REPORT

A 65-year-old, both maxillary and mandibular partially edentulous, male was referred to the Department of Prosthetic Dentistry, Istanbul University, Faculty of Dentistry. The patient's chief complaints were reduced function and unaesthetic appearance because of missing teeth and the lack of retention and stability with his previous RPD.

The patient's medical history revealed that he had radiation therapy on the right side of mandibular buccal shelf region at the head and neck area. At the extraoral examination, a scar tissue at the right buccal shelf area was observed due to the surgical tumor resection that was operated 25 years ago. In addition, loss of fibroelasticity of the right peripheral soft tissue and perioral region was discovered due to the radiotherapy while the left side indicated no abnormality [Figure 1]. When a dental anamnesis was taken, the patient has reported that three maxillary teeth with severe mobility were extracted before application to the Department of Prosthetic Dentistry Clinic. The patient had no existing dentures for both jaws. He had difficulty in usage of his previous dentures due to lack of retention. Intraoral examination revealed that the patient had two maxillary central and lateral teeth with moderate mobility and five mandibular teeth, right lateral to left canine with no mobility [Figure 2]. Reduced vestibular sulcus depth and a fibrous scar tissue were examined at the right buccal region. Radiographic examination using the existing panoramic X-ray showed that right maxillary canine and maxillary central incisor teeth were previously extracted. In addition, mandibular right first premolar with an existing periapical lesion was also decided to be extracted [Figure 3].

Three treatment options were presented to the patient.

- Maxillary and mandibular conventional clasp-retained RPDs were rejected because of the patient's previous complaint about lack of retention and stability with his previous dentures
- Maxillary and mandibular implant-supported fixed prostheses were rejected due to the financial limitations of the patient

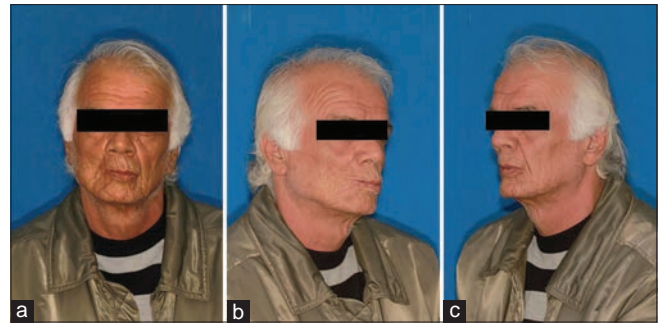


Figure 1: Extraoral view before prosthetic treatment (a). Scar tissue and loss of fibroelasticity at the right buccal shelf area due to the surgical tumor resection and radiotherapy (b). No indication of abnormality on the left side (c)

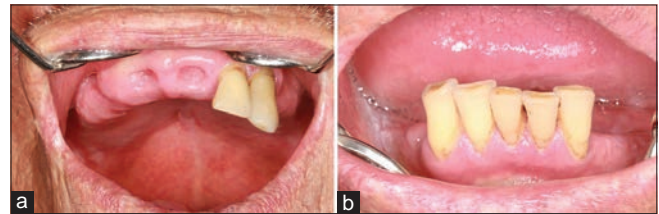


Figure 2: Preoperative intraoral view. Tissue healing at the right maxillary region and 2 left maxillary teeth (a). Mandibular teeth before prosthetic therapy (b)

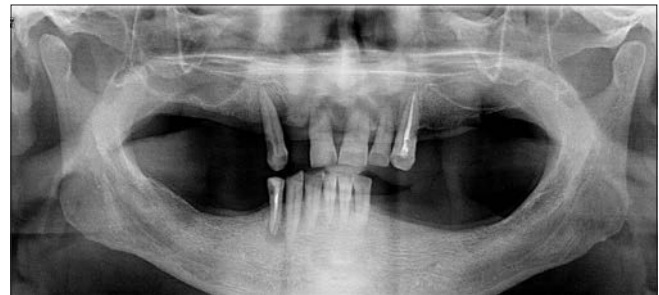

Figure 3: Preoperative panoramic X-ray view

- Maxillary complete denture and mandibular implant-supported RPDs were chosen by the patient as an optimal treatment with the advantage of the increased retention and stability provided by the implants for the mandibular RPD. The cons and pros for the extraction of maxillary left central and lateral teeth were explained in details to the patient in terms of biomechanics and esthetics. The patient preferred the extraction of the remaining teeth, and the future fabrication of a maxillary complete denture was planned. Written informed consent before surgical and prosthetic treatment was obtained from the patient.

Under local anesthesia, mucoperiosteal flaps were elevated and two implants (4.1 mm diameter, 10 mm length; Straumann AG, Waldenburg, Switzerland) were placed in posterior region of the mandible, both

on the right and left sides [Figure 4]. Primary closure was obtained in both operation sites. Prophylactic antibiotics and nonsteroidal anti-inflammatory drugs were prescribed. Sutures were removed on the 7th postoperative day. At the end of 3 months, the osseointegration of the implants was checked on the panoramic radiograph [Figure 5]. The healing of the mandibular distal edentulous sites seemed to be normal and gingival formers were placed [Figure 6]. At this stage, two maxillary teeth were also extracted before the initiation of the prosthodontic therapy.

Preliminary impressions were made using an alginate impression material (Italgin Chromatic Alginate, BMS Dental, Capannoli, Italy) and individual impression trays for both maxilla and mandible were fabricated using autopolymerizing acrylic resin. After border molding on the maxillary tray, the final impression was

made using a zinc oxide eugenol material (SS White, C/O Prima Dental Group, Gloucester, England). For the mandible, the locator abutments (H3 mm, coated Ti alloy, Straumann AG, Basel, Switzerland) were torqued to the implants with a 25 N/cm [Figure 7]. For the mandibular impression, impression copings were attached to the locator abutments. Cingulum rest seats were prepared on the mesial site of the mandibular right canine and between the mandibular first and second lateral incisors. After that, the final impression of the mandible was made using an addition silicone impression material (Dentasil A, DENTAC, Senden, Germany). Locator analogs were attached to the impression copings [Figure 8] and the impression was poured [Figure 9].

RPD framework was designed on the mandibular cast with T-bar clasps on the terminal abutment teeth and

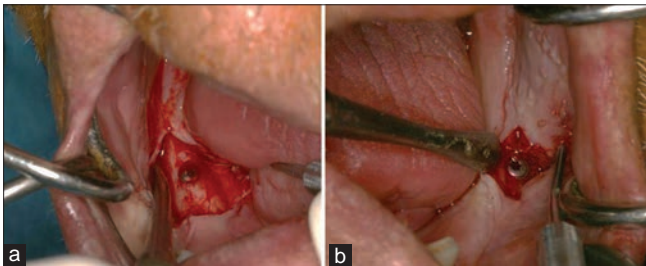


Figure 4: Implant surgery on the right (a) and left (b) first molar area

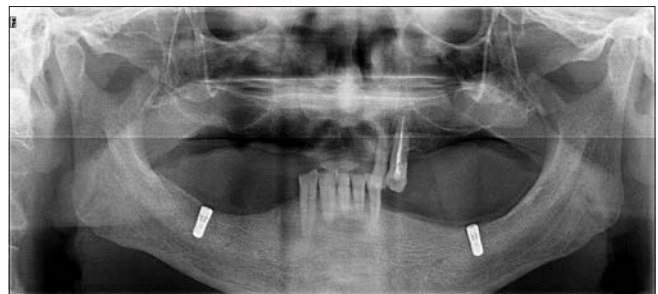

Figure 5: Panoramic X-ray view. Osseointegration of the implants at the postoperative 3rd month

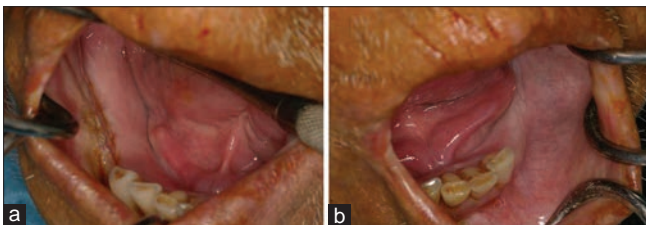


Figure 6: Intraoral view of implant site at the postoperative 3rd month. (a) right side (b) left side

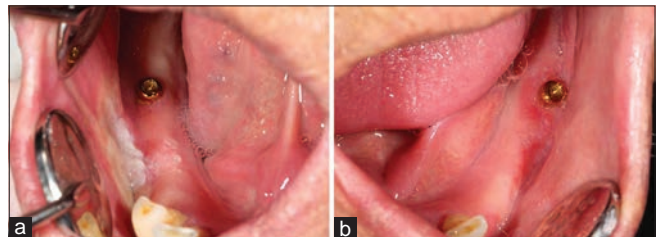


Figure 7: Locator abutments connected to the implants (a) right side (b) left side

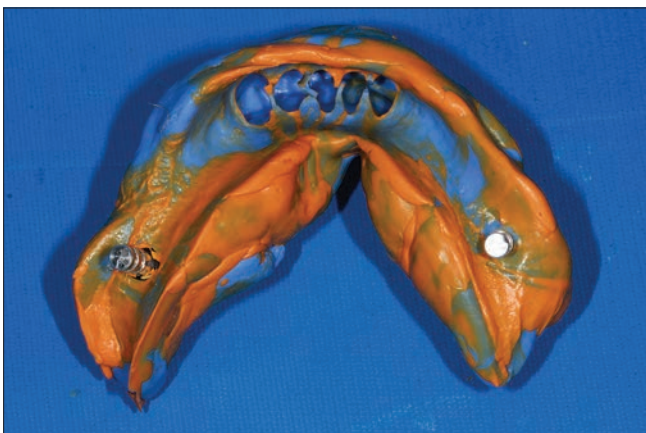


Figure 8: Final impression with impression copings attached with locator analogs



Figure 9: Working model with locator analogs

a lingual plate as a major connector. The cingulum rests were fabricated on the rest seats [Figure 10]. The framework at the implant abutment region was designed circular around the abutment, and the distance between the abutment and the framework was approximately 2 mm so as to support the denture base acrylic resin [Figure 11]. The RPD was cast using a chromium-cobalt casting alloy (DFS, Ländenstrabe, Riedenbug, Germany).

Artificial teeth (NT Optima, Toros Dental, Antalya, Turkey) setup was completed and tried in the mouth. The maxillary complete denture and mandibular RPDs were delivered to the patient Locator abutment matrix and black processing nylon insert were connected to the mandibular RPD using autopolymerizing acrylic resin (Self-cure acrylic, IMICRYL, Istanbul, Turkey). After polymerization, the denture was removed and the pink locator attachments were fitted [Figure 12]. After delivery, the patient was recalled weekly for 4 weeks [Figure 13]. The patient was satisfied with the function of his dentures as well as the improved esthetics [Figure 14].

DISCUSSION

Bounding of the RPD with implants is a treatment option which combines the advantages of the implants

and simplicity of the RPD system, with reducing the drawbacks of invasive attempt and cost of the implants more than two.^[3] In this case report, Kennedy Class 1 partial edentulousness was changed to an implant-bounded Kennedy Class 3 configuration.

The clinical factors (reduced fibroelasticity of the peripheral soft tissues, buccal scar tissue with a reduced sulcus depth of the right buccal area) that may negatively affect the denture's retention and stability are the indication of an implant-bounded RPD. These problems can be clinically resolved with a single implant on the distal edentulous sites that also improve the biomechanics of the prosthesis.^[1,3,4] Previous results suggest that by placing an implant to the distal extension site of the RPD, enhancement of distribution of the occlusal forces, movement of the posterior rotational axis to a distal position, shortening of the distal extension of the RPD, and reducing potential rotational movement of the RPD can be improved.^[3,15] The tissueward and the opposite movement of the RPD

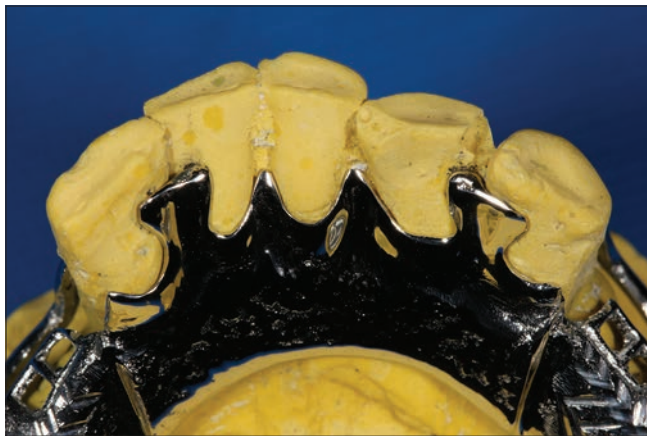


Figure 10: Cingulum rests designed on the mandibular anterior teeth

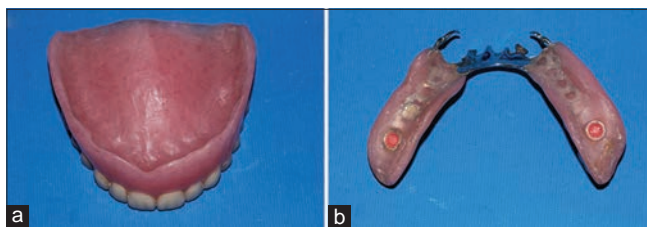


Figure 12: Maxillary complete denture (a) and mandibular implant-supported removable partial denture with locator attachments in the intaglio surface (b)

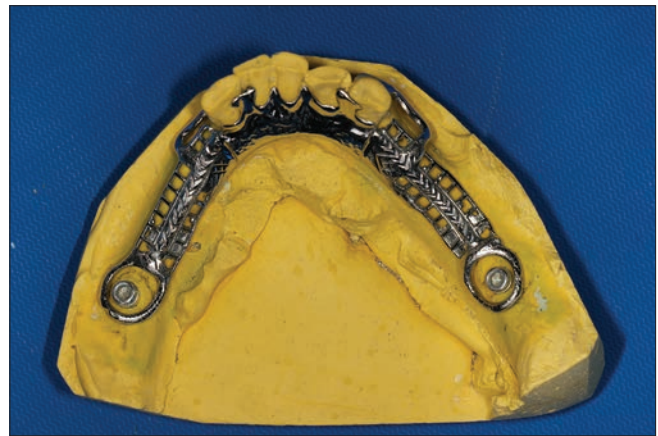

Figure 11: Removable partial denture framework with T-bar clasps on the terminal abutment teeth, lingual plate as a major connector and circular design around the implant abutments

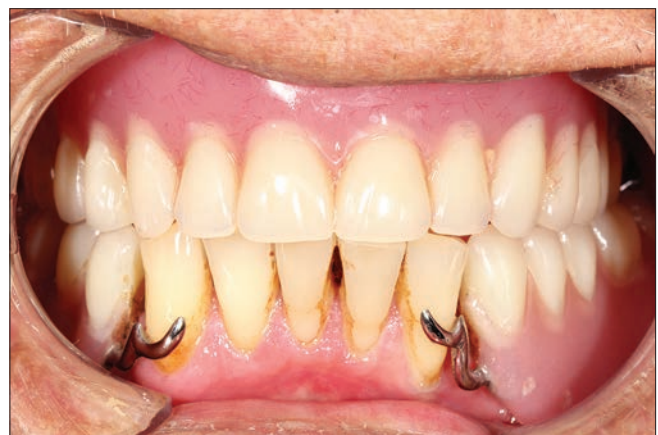

Figure 13: Intraoral view 4 weeks after delivery

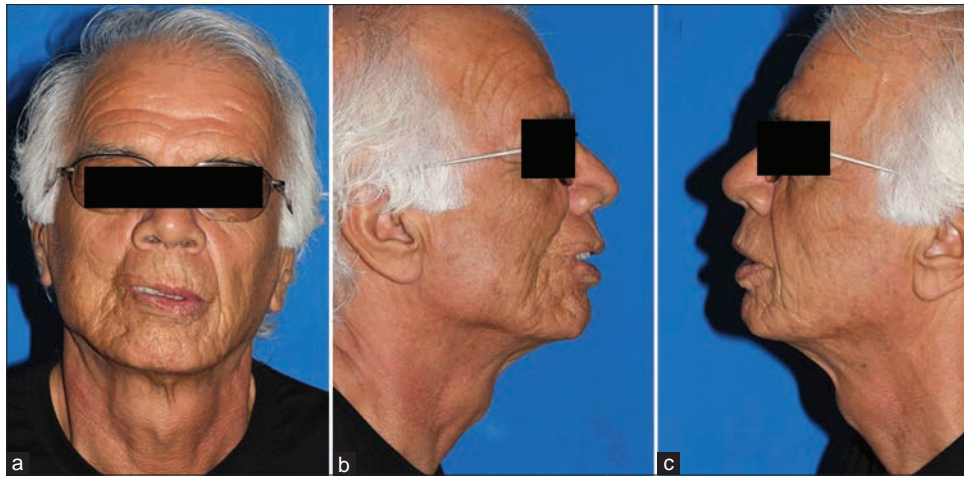

Figure 14: Extraoral view after prosthetic treatment (a). Right (b) and left side (c)

were restricted by the method mentioned above, and as a result, retention and stability of the RPD are increased. At the recall appointments, the patient did not report any complaint about the movement of the implant-supported RPD when compared to his previous conventional clasp-retained RPD. The patient satisfaction was also improved when compared to the patient's previous clasp-retained conventional RPD.

CONCLUSION

Placement of bilateral implants can convert the RPD from tooth- and tissue-supported RPD to an implant-supported RPD. In the present report, movement of the RPD was reduced and therefore retention and stability was improved by the implants with locator abutments. Finally, the treatment plan can be suggested, especially in patients who could not effort the implant-supported fixed prosthesis.

Declaration of patient consent

The authors certify that they have obtained all appropriate patient consent forms. In the form the patient(s) has/have given his/her/their consent for his/her/their images and other clinical information to be reported in the journal. The patients understand that their names and initials will not be published and due efforts will be made to conceal their identity, but anonymity cannot be guaranteed.

Financial support and sponsorship

Nil.

Conflicts of interest

There are no conflicts of interest.

REFERENCES

- Gonçalves TM, Campos CH, Garcia RC. Implant retention and support for distal extension partial removable dental prostheses: Satisfaction outcomes. *J Prosthet Dent* 2014;112:334-9.
- Zancopé K, Abrão GM, Karam FK, Neves FD. Placement of a distal implant to convert a mandibular removable Kennedy class I to an implant-supported partial removable Class III dental prosthesis: A systematic review. *J Prosthet Dent* 2015;113:528-33.e3.
- Bortolini S, Natali A, Franchi M, Coggiola A, Consolo U. Implant-retained removable partial dentures: An 8-year retrospective study. *J Prosthodont* 2011;20:168-72.
- Ohkubo C, Kobayashi M, Suzuki Y, Hosoi T. Effect of implant support on distal-extension removable partial dentures: *In vivo* assessment. *Int J Oral Maxillofac Implants* 2008;23:1095-101.
- Mitrani R, Brudvik JS, Phillips KM. Posterior implants for distal extension removable prostheses: A retrospective study. *Int J Periodontics Restorative Dent* 2003;23:353-9.
- Kono K, Kurihara D, Suzuki Y, Ohkubo C. Pressure distribution of implant-supported removable partial dentures with stress-breaking attachments. *J Prosthodont Res* 2014;58:115-20.
- Keltjens HM, Kayser AF, Hertel R, Battistuzzi PG. Distal extension removable partial dentures supported by implants and residual teeth: Considerations and case reports. *Int J Oral Maxillofac Implants* 1993;8:208-13.
- Elsyad MA, Habib AA. Implant-supported versus implant-retained distal extension mandibular partial overdentures and residual ridge resorption: A 5-year retrospective radiographic study in men. *Int J Prosthodont* 2011;24:306-13.
- Mijiritsky E, Karas S. Removable partial denture design involving teeth and implants as an alternative to unsuccessful fixed implant therapy: A case report. *Implant Dent* 2004;13:218-22.
- Verri FR, Pellizzer EP, Rocha EP, Pereira JA. Influence of length and diameter of implants associated with distal extension removable partial dentures. *Implant Dent* 2007;16:270-80.
- Griffin TJ, Cheung WS. The use of short, wide implants in posterior areas with reduced bone height: A retrospective investigation. *J Prosthet Dent* 2004;92:139-44.
- de Freitas RF, de Carvalho Dias K, da Fonte Porto Carreiro A, Barbosa GA, Ferreira MA. Mandibular implant-supported removable partial denture with distal extension: A systematic review. *J Oral Rehabil* 2012;39:791-8.
- Cunha LD, Pellizzer EP, Verri FR, Falcón-Antenucci RM, Goiato MC. Influence of ridge inclination and implant localization on the association of mandibular Kennedy class I removable partial denture. *J Craniofac Surg* 2011;22:871-5.
- Krekmanov L, Kahn M, Rangert B, Lindström H. Tilting of posterior mandibular and maxillary implants for improved prosthesis support. *Int J Oral Maxillofac Implants* 2000;15:405-14.
- Bilhan H. The role of the dental implant in removable partial dentures. In: Sakar O, editor. *Removable Partial Dentures: A Practitioners' Manual*. Switzerland: Springer International Publishing Switzerland; 2016. p. 195-208.