

Clinical evaluation of fiber-reinforced composite crowns in pulp-treated primary molars: 12-month results

Zahra Mohammadzadeh¹, Iman Parisay², Maryam Mehrabkhani³, Azam Sadat Madani¹,
Fatemeh Mazhari²

¹Dental Research Center, Faculty of Dentistry, Mashhad University of Medical Sciences, Mashhad, Iran,
²Dental Material Research Center, Faculty of Dentistry, Mashhad University of Medical Sciences, Mashhad, Iran,
³Oral and Maxillofacial Diseases Research Center, Faculty of Dentistry, Mashhad University of Medical Sciences, Mashhad, Iran

Correspondence: Dr. Fatemeh Mazhari
Email: mazharif@mums.ac.ir

ABSTRACT

Objective: The aim of this study was to evaluate the clinical performance of tooth-colored fiber-reinforced composite (FRC) crowns in pulp-treated second primary mandibular teeth. **Materials and Methods:** This split-mouth randomized, clinical trial performed on 67 children between 3 and 6 years with two primary mandibular second molars requiring pulp treatment. After pulp therapy, the teeth were randomly assigned to stainless steel crown (SSC) or FRC crown groups. Modified United States Public Health Service criteria were used to evaluate marginal integrity, marginal discoloration, and secondary caries in FRC crowns at intervals of 3, 6, and 12 months. Retention rate and gingival health were also compared between the two groups. The data were analyzed using Friedman, Cochran, and McNemar's tests at a significance level of 0.05. **Results:** Intact marginal integrity in FRC crowns at 3, 6, and 12 months were 93.2%, 94.8%, and 94.2%, respectively. Marginal discoloration and secondary caries were not found at any of the FRC crowns. The retention rates of the FRC crowns were 100%, 98.3%, and 89.7% at 3, 6 and 12 months, respectively, whereas all the SSCs were found to be present and intact after 12 months ($P = 0.016$). There was no statistically significant difference between the two groups in gingival health. **Conclusion:** According to the results of this study, it seems that when esthetics is a concern, in cooperative patients with good oral hygiene, FRC crowns can be considered as a valuable procedure.

Key words: Fiber-reinforced composite crowns, pulp-treated primary teeth, stainless steel crowns, United States Public Health Service criteria

INTRODUCTION

Tooth decay is still one of the most prevalent chronic conditions of childhood despite advances in preventive dentistry,^[1,2] and restoration of carious primary teeth following pulp treatment in particular is a challenge to dentists.^[3,4] Common options for use in pediatric

dentistry include amalgam, prefabricated crowns, and tooth color-matched filling materials.^[5]

Amalgam is still the most durable and cost-effective restorative material,^[4] but in preschool children with

This is an open access article distributed under the terms of the Creative Commons Attribution-NonCommercial-ShareAlike 3.0 License, which allows others to remix, tweak, and build upon the work non-commercially, as long as the author is credited and the new creations are licensed under the identical terms.

For reprints contact: reprints@medknow.com

How to cite this article: Mohammadzadeh Z, Parisay I, Mehrabkhani M, Madani AS, Mazhari F. Clinical evaluation of fiber-reinforced composite crowns in pulp-treated primary molars: 12-month results. Eur J Dent 2016;10:522-8.

DOI: 10.4103/1305-7456.195177

Access this article online	
<p>Quick Response Code:</p> 	<p>Website: www.eurjdent.com</p>

large proximal carious lesions, preformed metal crowns are preferred to amalgam because of their durability.^[6-9] However, there is always the issue of their low esthetics.^[4] Thus, when there is a grave concern on the part of parents regarding esthetics, the modified versions including open-face stainless steel crowns (SSCs) and preveneered SSCs are used.^[10] However, using the open-face SSC is time consuming, and the veneered SSC may lose its veneer coat over time.^[4,6]

Composites are the options available in this respect. Chief advantages include high esthetic value, relatively low heat conductance, and preservation of the prepared tooth.^[11] Nevertheless, there are concerns as toxicity, posttreatment sensitization, and marginal microleakage.^[12] In addition, this material cannot be the treatment of choice in cases of multiple extensive caries on posterior primary molars. Indirect composites and fiber-reinforced composites (FRCs) are the alternative suggestions.^[13]

In case of indirect composites, extraoral polymerization can seemingly enhance marginal integration and mechanical features of composites.^[14]

Another way to improve composite restoration quality is to apply an FRC. This material is composed of two parts: Fiber as the reinforcing element that gives support and strength and the matrix that provides the setting for the procedure.^[15] The FRC is deemed superior to conventional composites in that it is more esthetic and durable, also it has the benefit of being free of metal restorative material.^[16]

We aimed to investigate FRC clinical function in pulp-treated primary molar restorations and compare them to steel crowns since there has been no study conducted regarding this comparison.

MATERIALS AND METHODS

Design and subjects

This was a split-mouth randomized, clinical trial conducted on 67 patients aged 3–6 years, who were admitted to the Pediatric Department of the Mashhad Dental School. The Committee of Ethics of the Mashhad University of Medical Sciences approved the study. On the first visit, we clarified the objectives of the study to the parents and then we obtained written informed consent from all parents.

Patients entering the study were otherwise healthy, with their first permanent molars unerupted and

their second primary molars in need of bilateral pulp treatment. Their cooperation could be described as satisfactory, and their overall oral hygiene based on Oral Hygiene Index-Simplified criteria was good. We excluded uncooperative patients, those with deep-bite occlusion, and reverse bite (cross bite), as well as those with parafunctional habits from the study. Furthermore, we did not include cases where isolation could not be accomplished, either due to extended subgingival decay or lack of cooperation and if less than one-third of the total tooth could be salvaged due to the preparation.

Sample size

The sample size was determined based on data from a previous study.^[17] With a confidence level of 95% and a power of statistical test of 80%, 67 samples were considered for the study.

Randomization and blindness

The principle investigator did the randomization process by using random numbers to determine whether the left or right lower molars would be treated with FRCs or steel crowns. This was done using the “Research Randomizer” application, whereby a random number between 1 and 67 was provided by www.randomizer.org. Each case was assigned an opaque sealed envelope with a number in it. In case of an even number, the right and left molars were treated using steel crown and FRC, respectively. If the given number was an odd one, the reverse pattern was applied. The principle operator, patients, and assessor could not be blind due to the obvious appearance of the restorations.

Interventions

In the final sample of 67 patients on the registry, second primary molars on both sides of the mandible underwent pulp therapy, subsequent to which final restorations were done using steel crowns or FRCs on a random basis. All restorations were performed by one operator.

Fiber-reinforced crown

After removing existing carious lesions, a 1 mm shoulder finish line was done around the teeth using a shoulder bur #847-016 (Jota, Swiss). Then, the occlusal surface was reduced, leaving a gap of 1.5 mm with the opposing tooth. When reducing the proximal sides, a convergence angle of 6° was maintained when holding the tapered burr parallel to the vertical axis of the tooth [Figure 1].

Resin modified glass ionomer was used to homogenize the existing dimensions following the total removal

of caries. A glass ionomer core with the dimensions of 6 mm × 7 mm was created with a clearance gap of 1.5 mm with the opposing teeth when the mandible was in centric occlusion. In all teeth, core walls were, at the end, comprised glass ionomer (2/3) and dental tissue (1/3). Teeth with destruction in excess of the above mentioned were excluded.

The impressions pertaining to the prepared sites were then made, applying putty and wash; in order for crown occlusion adjustment, alginate impression of the opposite jaw was also created. In the laboratory, the die undercuts were covered by a thin layer of wax, next a thin layer of separator (GC Gradia, GC corporation, Tokyo, Japan) was placed over the die, then a layer of flowable composite (FiltekZ350, 3M ESPE, USA) which is followed by fiberglass (Angelus, Londrina, PR, Brazil) smeared with resin in woven pattern was applied and light cured. The composite was placed over the die incrementally and polymerized by Steplight Unit (GC STEPLIGHT SL-I, GC Corporation, Tokyo, Japan). Finally, the restoration was put into light cure polymerization unit (GC Labolight LV-III, GC Corporation, Tokyo, Japan) for 5 min for better polymerization.

To enhance retention during placement, two horizontal grooves measuring 3 mm in length and 1 mm in depth were created on the buccal and lingual sides of the core using a tapered finishing bur #859 L (Jota, Swiss) [Figure 1]. The core was cleansed and debris was removed by applying 37% phosphoric acid for 5 s. After complete rinsing and drying the tooth and the crown, the cementation was done using G-cem self-adhesive capsular

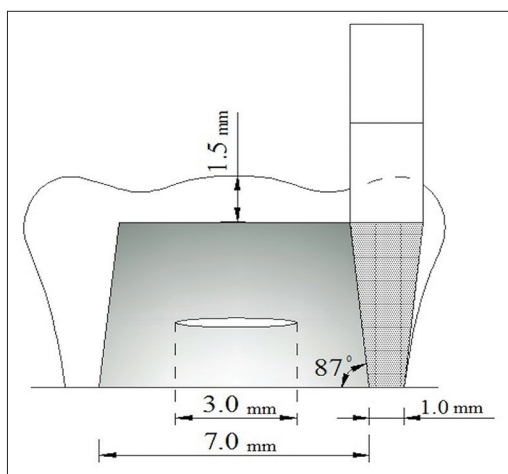


Figure 1: Schematic illustration of teeth prepared for the fiber-reinforced composite crown. The horizontal grooves with 3 mm length and 1 mm depth were made on the buccal and lingual sides of the core

cement (GC Corporation, Japan) under isolation. Light was then applied for 4 s for the initial setting, and after removing excess cement on the margins, the final curing was done with a high-intensity light emitting diode light curing unit (1100 mW/cm²) for 60 s (buccal, lingual, and occlusal surfaces were each cured for 20 s). Light curing was performed while applying pressure on the crown. After completing the curing, keeping intact isolation, there was a 5 min time for cement to reach its ultimate strength. This was followed by final finishing, polishing, and checking the occlusion.

Steel crowns

After pulp therapy and preparing the teeth as usual, SSCs (SSC 3M ESPE) were cemented using glass ionomer cement [Figure 2].

Dental health instructions were given and appointments were made at 3, 6, 12, and 24 months after crown placement. Only 33 patients attended their 24-month follow-up, so their results were excluded from the statistical analysis. In each appointment, retention rate and gingival status on both sides, and marginal integration, marginal discoloration, and secondary caries were examined according to modified United States Public Health Service (USPHS) criteria on FRCs [Table 1].^[17,18]

Statistical analysis

Freedman test was used for marginal integration status at 3, 6, and 12 months. Cochran test was applied for gingival assessment at 3, 6, and 12 months. McNemar's test was used to compare durability and health status in the FRC and steel crown groups.

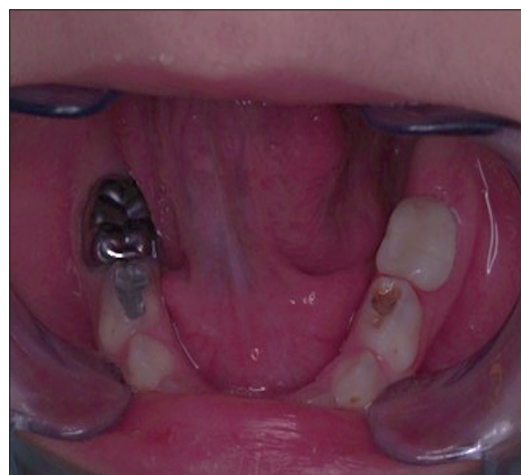

Figure 2: Intraoral view of the teeth restored with the two types of crown

RESULTS

Sixty-seven patients (49% male, 51% female, mean age 4.81 ± 1.18) participated in this study. Fifty-nine out of 67 patients attended their follow-up sessions at months 3, 6, and 12 [Figure 3].

Retention rate of FRCs was 89.7% after 12 months, which was lower than the value (100%) in SSCs ($P = 0.002$). Gingival status around the FRCs showed favorable outcomes with 98.3%, 87.9%, and 90.4% at 3, 6, and 12 months, respectively. Cochran test results were not statistically significant in these follow-up sessions ($P = 0.14$). Gingival status around the SSCs showed favorable outcomes with 98.3%, 96.6%, and 94.2% at 3, 6, and 12 months, respectively. Cochran test results were not statistically significant in these follow-up sessions ($P = 0.6$). Retention rate and gingival status of the two crowns after 3, 6, and 12 months are compared in Figures 4 and 5, respectively.

In the FRC group, we could not detect any change in marginal discoloration nor secondary decays at any follow-up intervals. Marginal integration values of the FRCs at different follow-up times until 12 months are shown in Table 2.

24-month follow-up

Only 33 patients attended their 24-month follow-up, so their results were not included in the statistical analysis. Two out of 33 FRCs detached, while all of the SSCs remained intact. Four patients in the FRC group and three patients in the SSC group had bleeding on

Table 1: Modified United States Public Health Service criteria

Category	Scores	Criteria
Marginal adaptation	0	Restoration is continuous with existing anatomic form, explorer does not catch
	1	Explorer catches, no crevice is visible into which explorer will penetrate
	2	Crevice at margin, enamel exposed
	3	Obvious crevice at margin, dentine or base exposed
Marginal discoloration	4	Restoration mobile, fractured or missing
	0	No discoloration evident
	1	Slight staining can be polished away
Secondary caries	2	Obvious staining can be polished away
	3	Gross staining
	0	No caries present
Gingival health	1	Caries present
	0	No gingival bleeding
	1	Bleeding with probing
	2	Spontaneous bleeding

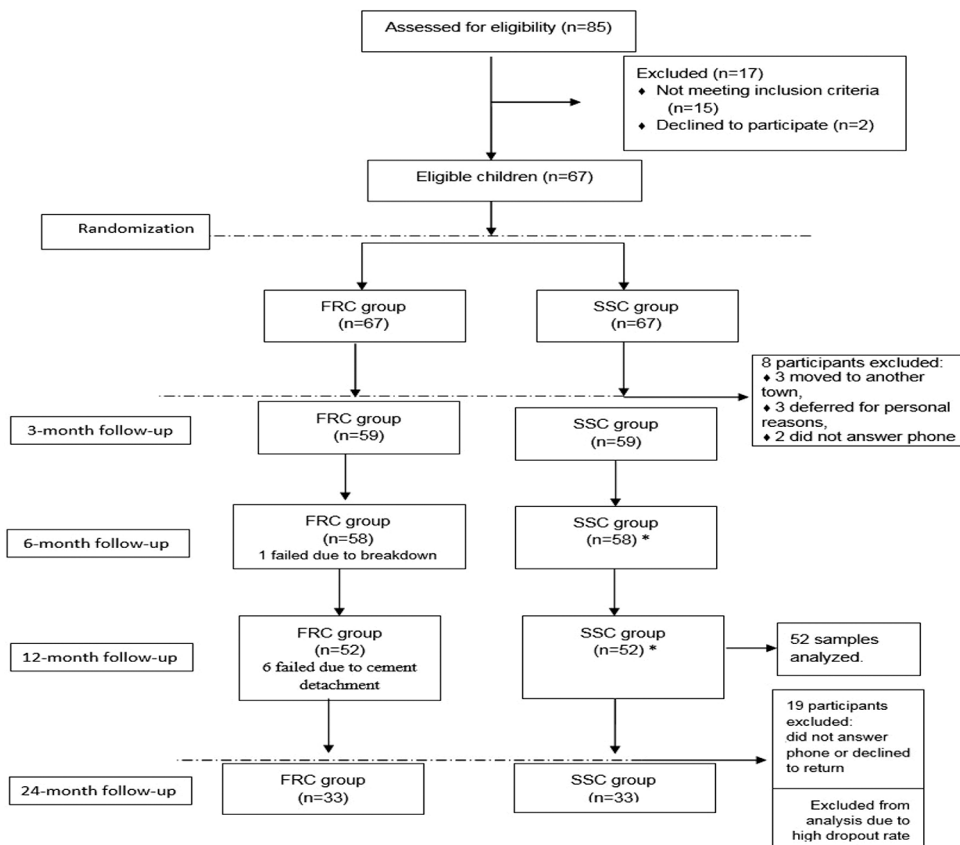


Figure 3: The flow of participants through each stage of the study

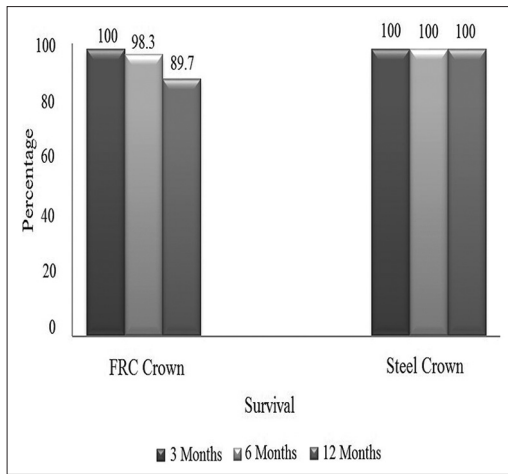


Figure 4: Comparison of the survival of fiber-reinforced crowns and steel crowns in 3, 6, and 12 months intervals

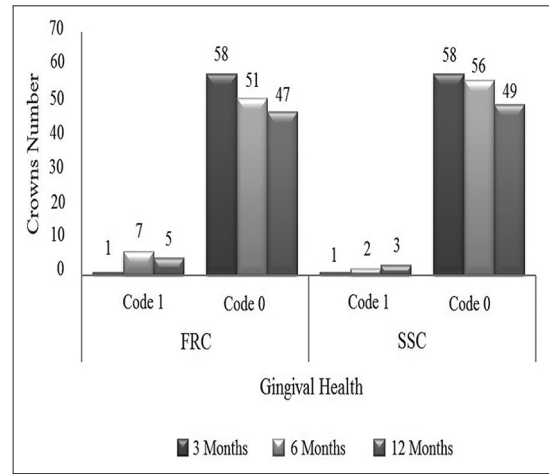


Figure 5: Comparison of the gingival health around fiber-reinforced crowns and steel crowns in 3, 6, and 12 months intervals

Table 2: Comparison the marginal integrity of fiber-reinforced crowns at intervals of 3, 6, and 12 months

Score*	Follow-up, n (%)		
	3 months	6 months	12 months
0	55 (93.2)	55 (94.8)	49 (94.2)
1	3 (5.1)	2 (3.4)	2 (3.8)
2	1 (1.7)	1 (1.7)	1 (1.9)
3	0	0	0
Total	59 (100)	58 (100)	52 (100)
Friedman test (P)	0.368		

*Code 0: Restoration is continuous with existing anatomic form; explorer does not catch, Code 1: Explorer catches; no crevice is visible into which explorer will penetrate, Code 2: Crevice at margin; enamel exposed, Code 3: Obvious crevice at margin, dentine or base exposed

probing. Marginal integrity was scored as 81% Code 0 in the FRC group, (three crowns rated Code 1 and three crowns rated Code 2). There was no secondary caries or marginal discoloration.

DISCUSSION

Primary teeth restoration following pulp treatment is a constant challenge to dentists owing to the scant remaining dental tissue and low structural strength. Conventional solutions have recommended SSCs; the chief demerit of which is their poor esthetic values. A number of other materials including composites and esthetic SSCs are in use, each with their own drawbacks. In this respect, FRC has been gaining popularity owing to its favorable features, as well as esthetic value. Hence, in this study, we used this material for posterior primary teeth restoration.

After 12 months, only seven FRCs were found unsuccessful, and the remaining crowns were in the

optimum condition in terms of marginal integration. Of these seven unsuccessful crowns, only one crown broke and the others were decemented but intact, and if the patients referred earlier, it would have been possible for us to recement them. There was also neither sign of color change nor secondary caries after 12 months. Gingival health was assessed “acceptable” during the follow-up, with no statistically significant difference with the steel crown group.

The FRC mechanical features are profoundly influenced by the fiber type, alignments, preparation, and matrix.^[11,14] We opted for woven glass fibers smeared with resin. The woven pattern enabled the fibers to bear tension in various directions as they spread out, with resin adding to the strength of the FRC.^[19] Fiber alignment in the matrix was carried out manually.

A key factor in the final outcome is to maintain marginal integration, which, in turn, depends on dental preparation, properties of the material used, cement type, crown preparation, and measurement precision.^[20] We used resin cement and a convergence angle of 6°. We also used an explorer for measuring the gap on FRCs based on UHPHS criteria. There is still controversy regarding the impact of the axial convergence angle on the gaps between margins. Some studies reported that the gaps widened in cases of sharper convergence angles and so in most of the studies the researchers proposed an optimum of 6° to achieve the minimum gap.^[20,21] Researchers have shown that resin cement can lead to an ideal marginal integration,^[22] which, if unachieved, can cause destruction due to cement exposure in the oral cavity. In a 10-year study by Gaengler on 108 cases

of composite restorations based on USPHS criteria, only thirty restorations sustained optimum marginal integration.^[23] However, Shiono reported 100% integration 87.5 months after applying the indirect composite,^[24] whereas Burke reported a success rate of 84% following a 2-year study on 100 composite-treated cases.^[25] In this study, optimum, marginal integration was observed in 94.2% of crowns after 12 months.

Another factor that was assessed in this study was marginal discoloration around FRCs. There was no marginal discoloration during the follow-up time. Monaca reported a 4% abutment gradual color change occurring over time in the 4-year study of 182 FRC bridges based on USPHS criteria.^[26] Anya also mentioned no color change was observed in their 3-year follow-up of FRC anterior repairs.^[27] In contrast, in a 2-year assessment by Can Say *et al.*, a statistically significant disparity was noted in this respect.^[28] There are two points worthy of note here. First, our follow-up was relatively short; it was likely that longer assessment would reveal otherwise. Second, the above-mentioned research investigated composite repairs, whereas ours was on the FRC where additional curing and polishing were applied, this could lead to less discoloration.^[29]

There was no recurrent caries attack during the 12-month follow-up in the FRC group, also gingival health was acceptable with no statistically significant difference with the steel crown group. This might be partly due to the inclusion criteria, in which the participants were judged to have good oral hygiene. Yet, fluoride emitting from G-cem can also play a role in preventing secondary decays. What corroborates our finding in this respect is the outcome achieved by Burke *et al.*,^[25] Mendonça *et al.*,^[30] Prati *et al.*,^[31] Deliperi and Bardwell,^[32] and Santiago *et al.*^[33] in their assessments of composite restorations followed for 24, 12, 36, 30, and 24 months, respectively. Guelmann *et al.*,^[34] Sharaf and Farsi,^[35] Einwag,^[36] Chao *et al.*,^[37] and Durr *et al.*^[38] all implied that metal crowns do not adversely impact gingival health and the surrounding periodontium, needless to mention the undeniable effect of oral health in this respect. In our findings, there was no report of any statistically considerable disparity between the two types of crowns in this respect. As mentioned before, dental hygiene is highly influential in this final outcome.^[34,39] We managed to maintain almost equal conditions in our split-mouth study, which chiefly explains the results of our study.

The SSCs showed 100% durability compared to FRCs (89.7%) at the end of the 1-year assessment,

which the difference was statistically significant. We opted for self-adhesive cement owing to the convenience in use, as well as its fluoride-emitting feature.^[34] According to past studies, self-adhesive cements were shown to have weaker bonds comparing to self-etch and etch and rinse-perhaps due to limited demineralization and infiltration capacity to the underlying dentin.^[40] This can also explain the reason why six of our participants failed to achieve proper outcomes (in cases of crown detachment).

The SSC has been highly regarded in pulp-treated primary molars owing to its durability and strength.^[41-44] It is particularly recommended in high-risk children with extensive anterior and posterior primary teeth lesions. In comparison, FRC is recommended in cases where there is a cosmetic concern on the part of parents, provided that oral health is maintained and the child remains cooperative during the procedure.

One chief limitation in our study was that cases of failure (crown detachment) returned too late; otherwise, the same crowns could have been recemented. Moreover, there was a high drop-out rate after 24 months (about 50%), and since the high dropout numbers could bias the results, we did not include the 24-month results in our analysis.

CONCLUSION

The SSCs were substantially more durable than their counterpart the FRCs, whereas the two did not differ in their gingival status outcome. The latter were also shown to have excellent marginal integration with no color change or recurrent decays. Although SSCs still seem to remain the material of choice in pulp-treated primary molars, if esthetic concerns exist and the patient is sufficiently cooperative, FRCs can be applied as an alternative mode of treatment.

Acknowledgment

This investigation was supported by the vice-chancellor for research of the Mashhad University of Medical Sciences, Iran. This study was based on a thesis ($n = 453$) submitted to the Mashhad Dental School, Mashhad University of Medical Sciences (Iran), in partial fulfillment of the requirements for the Master of Science degree in Pediatric Dentistry. We would also like to show our gratitude to the Tooth Dental-Sahebkar Laboratory for the reliable fabrication of FRC crowns.

Financial support and sponsorship
Nil.

Conflicts of interest

There are no conflicts of interest.

REFERENCES

- Dean J, Avery D, McDonald R. *Dentistry for the Child and Adolescent*. 9th ed. St. Louis: Elsevier Saunders; 2011. p. 177-204.
- Roberson T, Heymann H, Swift E, Sturdevant C. *Sturdevants Art and Science of Operative Dentistry*. 5th ed. United States: Scherfer; 2006.
- Hosoya Y, Omachi K, Staninec M. Colorimetric values of esthetic stainless steel crowns. *Quintessence Int* 2002;33:537-41.
- American Academy of Pediatric Dentistry. Clinical Affairs Committee – Restorative Dentistry Subcommittee. Guideline on pediatric restorative dentistry. *Pediatr Dent* 2012;34:173-80.
- Kilpatrick NM. Durability of restorations in primary molars. *J Dent* 1993;21:67-73.
- Ram D, Fuks AB, Eidelman E. Long-term clinical performance of esthetic primary molar crowns. *Pediatr Dent* 2003;25:582-4.
- Guelmann M, Bookmyer KL, Villalta P, Garcia-Godoy F. Microleakage of restorative techniques for pulpotomized primary molars. *J Dent Child (Chic)* 2004;71:209-11.
- Shinya A, Lassila LV, Vallittu PK. The effect of preparation design on the marginal stress of resin-bonded metal-free crowns: A finite element study. *Int J Prosthodont* 2008;21:445-7.
- Donly KJ, Ellis RK. Glass inserts. A new dimension in restorative dentistry. *Am J Dent* 1989;2:21-4.
- Ram D, Peretz B. Composite crown-form crowns for severely decayed primary molars: A technique for restoring function and esthetics. *J Clin Pediatr Dent* 2000;24:257-60.
- Dyer SR, Lassila LV, Jokinen M, Vallittu PK. Effect of fiber position and orientation on fracture load of fiber-reinforced composite. *Dent Mater* 2004;20:947-55.
- Sadowsky SJ. An overview of treatment considerations for esthetic restorations: A review of the literature. *J Prosthet Dent* 2006;96:433-42.
- Pinkham JR, Casamassimo PS, McTigue DJ, Fields HW, Nowak AJ. *Pediatric Dentistry: Infancy Through Adolescence*. 4th ed. St. Louis: Elsevier Saunders; 2005. p. 325-40.
- Garoushi SK, Lassila LV, Tezvergil A, Vallittu PK. Fiber-reinforced composite substructure: Load-bearing capacity of an onlay restoration and flexural properties of the material. *J Contemp Dent Pract* 2006;7:1-8.
- Freilich M, Meiers J, Duncan J, Goldberg A. *Fiber-reinforced Composites in Clinical Dentistry*. Chicago: Quintessence; 1999.
- Garoushi S, Vallittu PK, Lassila LV. Fracture resistance of short, randomly oriented, glass fiber-reinforced composite premolar crowns. *Acta Biomater* 2007;3:779-84.
- Atieh M. Stainless steel crown versus modified open-sandwich restorations for primary molars: A 2-year randomized clinical trial. *Int J Paediatr Dent* 2008;18:325-32.
- van Dijken JW, Hasselrot L, Ormin A, Olofsson AL. Restorations with extensive dentin/enamel-bonded ceramic coverage. A 5-year follow-up. *Eur J Oral Sci* 2001;109:222-9.
- Arhun N, Arman A. Fiber-reinforced technology in multidisciplinary chairside approaches. *Indian J Dent Res* 2008;19:272-7.
- Cho L, Song H, Koak J, Heo S. Marginal accuracy and fracture strength of ceromer/fiber-reinforced composite crowns: Effect of variations in preparation design. *J Prosthet Dent* 2002;88:388-95.
- Cho L, Choi J, Yi YJ, Park CJ. Effect of finish line variants on marginal accuracy and fracture strength of ceramic optimized polymer/fiber-reinforced composite crowns. *J Prosthet Dent* 2004;91:554-60.
- Behr M, Rosentritt M, Mangelkramer M, Handel G. The influence of different cements on the fracture resistance and marginal adaptation of all-ceramic and fiber-reinforced crowns. *Int J Prosthodont* 2003;16:538-42.
- Gaengler P, Hoyer I, Montag R. Clinical evaluation of posterior composite restorations: The 10-year report. *J Adhes Dent* 2001;3:185-94.
- Shiono H, Koizumi H, Hirata M, Ayano M, Nakayama D, Matsumura H. Seven-year clinical evaluation of indirect restorations made of the Estenia composite. *Int Chin J Dent* 2009;9:39-43.
- Burke FJ, Crisp RJ, James A, Mackenzie L, Pal A, Sands P, *et al.* Two year clinical evaluation of a low-shrink resin composite material in UK general dental practices. *Dent Mater* 2011;26:22-30.
- Monaco C, Ferrari M, Miceli GP, Scotti R. Clinical evaluation of fiber-reinforced composite inlay FPDs. *Int J Prosthodont* 2003;16:319-25.
- Ayna B, Celenk S, Atakul F, Uysal E. Three-year clinical evaluation of endodontically treated anterior teeth restored with a polyethylene fibre-reinforced composite. *Aust Dent J* 2009;54:136-40.
- Can Say E, Kayahan B, Ozel E, Gokce K, Soyman M, Bayirli G. Clinical evaluation of posterior composite restorations in endodontically treated teeth. *J Contemp Dent Pract* 2006;7:17-25.
- Zortuk M, Kilic K, Uzun G, Ozturk A, Kesim B. The effect of different fiber concentrations on the surface roughness of provisional crown and fixed partial denture resin. *Eur J Dent* 2008;2:185-90.
- Mendonça JS, Neto RG, Santiago SL, Lauris JR, Navarro MF, de Carvalho RM. Direct resin composite restorations versus indirect composite inlays: One-year results. *J Contemp Dent Pract* 2010;11:025-32.
- Prati C, Chersoni S, Cretti L, Montanari G. Retention and marginal adaptation of a compomer placed in non-stress-bearing areas used with the total-etch technique: A 3-year retrospective study. *Clin Oral Investig* 1998;2:168-73.
- Deliperi S, Bardwell DN. Clinical evaluation of direct cuspal coverage with posterior composite resin restorations. *J Esthet Restor Dent* 2006;18:256-65.
- Santiago SL, Passos VF, Vieira AH, Navarro MF, Lauris JR, Franco EB. Two-year clinical evaluation of resinous restorative systems in non-carious cervical lesions. *Braz Dent J* 2010;21:229-34.
- Guelmann M, Matsson L, Bimstein E. Periodontal health at first permanent molars adjacent to primary molar stainless steel crowns. *J Clin Periodontol* 1988;15:531-3.
- Sharaf AA, Farsi NM. A clinical and radiographic evaluation of stainless steel crowns for primary molars. *J Dent* 2004;32:27-33.
- Einwag J. Effect of entirely preformed stainless steel crowns on periodontal health in primary, mixed dentitions. *ASDC J Dent Child* 1984;51:356-9.
- Chao DD, Tsai TP, Chen TC. Clinical evaluation of gingival tissue restored with stainless steel crown. *Changcheng Yi Xue Za Zhi* 1992;15:198-203.
- Durr DP, Ashrafi MH, Duncan WK. A study of plaque accumulation and gingival health surrounding stainless steel crowns. *ASDC J Dent Child* 1982;49:343-6.
- Al-Samhan A, Al-Enezi H, Alomari Q. Clinical evaluation of posterior resin composite restorations placed by dental students of Kuwait University. *Med Princ Pract* 2010;19:299-304.
- Pavan S, dos Santos PH, Berger S, Bedran-Russo AK. The effect of dentin pretreatment on the microtensile bond strength of self-adhesive resin cements. *J Prosthet Dent* 2010;104:258-64.
- Lehmann F, Eickemeyer G, Rammelsberg P. Fracture resistance of metal-free composite crowns-effects of fiber reinforcement, thermal cycling, and cementation technique. *J Prosthet Dent* 2004;92:258-64.
- Attari N, Roberts JF. Restoration of primary teeth with crowns: A systematic review of the literature. *Eur Arch Paediatr Dent* 2006;7:58-62.
- Guelmann M, Fair J, Bimstein E. Permanent versus temporary restorations after emergency pulpomies in primary molars. *Pediatr Dent* 2005;27:478-81.
- Kirzioglu Z, Gungor OE, Ciftci ZZ. Evaluation of the restoration success of endodontic therapy of the primary molars. *Eur J Dent* 2011;5:415-22.