

Efficacy of LA Axxess burs, Gates Glidden drills and Protaper Sx in obtaining straight line access in mesiobuccal roots of mandibular first molars: A cone-beam computed tomography assessment

Promila Verma¹, Rhythm Bains¹, A. P. Tikku¹, Anil Chandra¹, Shibha Mehta¹

Correspondence: Dr. Rhythm Bains
Email: docrhythm77@gmail.com

¹Department of Conservative Dentistry and Endodontics, Faculty of Dental Sciences, King George's Medical University, Lucknow, Uttar Pradesh, India

ABSTRACT

Objective: This study aims at cone-beam computed tomography (CBCT) evaluation of the ability of Gates Glidden (GG) drills, Protaper Sx, and LA Axxess burs to produce a straight line access (SLA) in mesiobuccal canals of mandibular first molars. **Methodology:** Forty-five freshly extracted mandibular teeth with a canal curvature of 10-20° were taken for the study and divided into three groups according to the instruments used for cervical preflaring: Group I (LA Axxess burs), Group II (GG drills), and Group III (Protaper Sx). Pre- and post-instrumentation CBCT images were evaluated for comparing the ability of GG drills, Protaper Sx and LA Axxess burs to produce an SLA in mesiobuccal canals of mandibular first molars. **Results:** There was no significant change ($P = 0.06$) in the angle in the preSLA images of LA Axxess Group I (12.37 ± 1.01), GG Group II (13.39 ± 1.74), and Protaper Sx Group III (13.90 ± 1.74). The mean decrease in the angle from preSLA to postSLA was significant for all the three groups ($P = 0.0001$). However, the mean change was highest in Group I (4.25 ± 1.14), followed by Group II (3.28 ± 1.22) and Group III (2.89 ± 1.53). **Conclusion:** LA Axxess burs were the most effective in reducing the coronal curvature and produced a straighter access to apical third compared to GG Drills and Protaper Sx.

Key words: Cervical preflaring, coronal curvature, straight line access

INTRODUCTION

The primary objective of endodontic therapy is to render thorough debridement of the root canal throughout its length to ensure reduced postoperative symptoms, enhanced healing and increased longevity of the endodontically treated tooth. The root canal anatomy often presents obstructions in the coronal one-third, especially in the curved canals, which hampers the smooth access of endodontic instruments, medications, and irrigants to the apical one-third, thus leaving behind a significant residual bacterial load in

the canal.^[1] Use of cervical or coronal preflaring and the crown-down technique removes these obstructions to allow an unimpeded and straighter access of the instruments to the apical third of root canal.^[2]

Straight line access (SLA) refers to a preparation path which results in an unobstructed or straight path from the occlusal to the apical end or the first curvature of the canal.^[3] This not only reduces unnecessary deflection of the file and allows better operator control over the

This is an open access article distributed under the terms of the Creative Commons Attribution-NonCommercial-ShareAlike 3.0 License, which allows others to remix, tweak, and build upon the work non-commercially, as long as the author is credited and the new creations are licensed under the identical terms.

For reprints contact: reprints@medknow.com

How to cite this article: Verma P, Bains R, Tikku AP, Chandra A, Mehta S. Efficacy of LA Axxess burs, Gates Glidden drills and Protaper Sx in obtaining straight line access in mesiobuccal roots of mandibular first molars: A cone-beam computed tomography assessment. Eur J Dent 2016;10:486-90.

DOI: 10.4103/1305-7456.195174

Access this article online	
<p>Quick Response Code:</p> 	<p>Website: www.eurjdent.com</p>

instrument, but also improves tactile sense, increases the accuracy of working length (WL) determination and aids in adequately achieving the desired apical working width.^[4-6]

One of the pioneer instruments used for achieving SLA were the Gates Glidden (GG) drills. These are used sequentially in a circumferential manner, but do not completely remove the cervical interferences, especially in the cemento-enamel junction. Furthermore, they tend to cut more dentin in the furcal region (danger zone) thus compromising tooth integrity.^[7,8] Today, most of the Ni-Ti rotary systems offer orifice openers and shapers for preflaring of the canals. Quite popular among these, the auxiliary shaping Ni-Ti file Protaper Sx, offer advantages such as superelasticity, lesser chance of canal transportation and strip perforation when compared to the stainless steel GG drills. More recently, titanium nitride treated, stainless steel LA Axxess burs (SybronEndo, Orange, CA, USA), with safe ended tips have been introduced, which promise a safer and more effective preflaring compared to the conventional drills and files.

The mesial root of the mandibular first molar often presents with a flat and ribbon-shaped canal anatomy with significant curvature in the mesiobuccal canals, thus making it difficult to negotiate the apical third area. The present study thus aims at cone-beam computed tomography (CBCT) evaluation of the ability of GG drills, Protaper Sx, and LA Axxess burs to produce an SLA in mesiobuccal canals of mandibular first molars.

METHODOLOGY

Forty-five freshly extracted mandibular teeth with a canal curvature of 10-20° (Schneider's method)^[9] in the mesial roots and two separate foramina were collected and stored in 5.25% sodium hypochlorite for disinfection. Exclusion criteria included teeth with incompletely formed apices, external resorption, or canal calcification. To determine the WL an ISO size 10 file was inserted in the canal till its tip was visible at the apical foramen. Teeth were mounted on a clear acrylic block, and standard access cavities were prepared. A 0.5 mm depth groove was prepared on the mesiobuccal cusp tip of the teeth and gutta-percha was condensed in it so that it could serve as a radiopaque marker for a fixed reference point. The teeth were divided into three groups ($n = 15$) according to the system used for preflaring. Preflaring was done in accordance with the manufacturer's instructions.

- Group I: Size 20/0.06 taper line angle stainless steel La Axxess (SybronEndo, Orange, CA, USA) burs used for preflaring the cervical and middle third of the canal, 3 mm short of WL
- Group II: GG drills (Dentsply, Maillefer, Switzerland) were used middle third preflaring for cervical and at a length till resistance was felt in middle third of canal in a sequence of size 4, 3 and 2 (ISO sizes 110, 90, and 70) at a speed of 2500 rpm on a conventional micromotor. The canal was recapitulated with size 15 K file and irrigated with 5.25% NaOCl after each size change
- Group III: Cervical preflaring with Protaper Sx (Dentsply, Maillefer, Switzerland) 3 mm short of WL after determining canal patency with a size 15 file on an electric endomotor at 300 rpm and a torque setting of 0.2 N.

Cross-sectional sagittal CBCT (Planmeca ProMax 3D, USA Inc., Romexis software) images were taken with size 10 file inserted in mesiobuccal canal till WL, and these were termed as preSLA images. The images were saved for further comparison with images after coronal flaring (postSLA images). After cervical and middle third preflaring, postSLA images were taken with a file that was bound in the canal till full WL (tip visible at the apex). The preSLA and postSLA changes in the file deflection were compared as presented in Figure 1 and explained as follows.

On the CBCT image, Line A represented the file long axis. Line C was drawn from radio-opaque marker to the beginning of canal curvature. The point where the Lines A and C meet was Point B and the angle

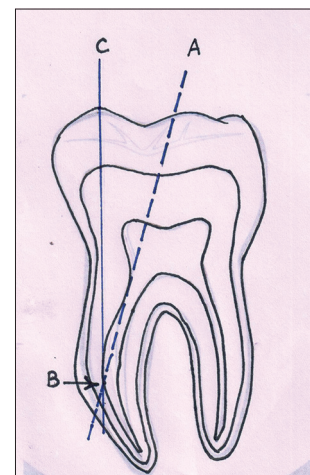


Figure 1: Line-diagram representation of the methodology. Line A represents the file long axis. Line C was drawn from radio opaque marker to the beginning of canal curvature where Line A left the canal long axis. The point where the Lines A and C meet was point B and the angle ABC is the canal-file angle

ABC (canal-file angle) was noted for all teeth in the preSLA images. After preflaring, the angle ABC was again measured. The pre- and post-readings were noted, and mean change was recorded [Figures 2-4]. One-way ANOVA was used to compare the pre and postSLA mean change among the groups, followed by Tukey's *post-hoc* comparison test. Paired *t*-test was used to compare the changes within the group. The level of significance was kept at $P < 0.05$. All analysis was carried out using SPSS version 16 (SPSS Inc., Chicago, IL, USA).

RESULTS

There was no significant change ($P = 0.06$) in the angle in the preSLA images of LA Axxess Group I (12.37 ± 1.01), GG Group II (13.39 ± 1.74), and ProtaperSx Group III (13.90 ± 1.74). The mean decrease in the angle from preSLA to postSLA was significant for all the three groups ($P = 0.0001$). However, the mean change was higher in Group I (4.25 ± 1.14), Group II (3.28 ± 1.22), and Group III (2.89 ± 1.53) [Tables 1 and 2]. The mean percentage change was 34.7% in Group I, 11.9% in Group II, and 10.5% in Group III.

DISCUSSION

Owing to the canal irregularities and curvature of the root canal, a significant area of the canal remains

un-instrumented even after completion of cleaning and shaping.^[10] Studies have shown that coronal and middle third preflaring gives a better chance for maximum instrumentation of the radicular dentin by increasing the contact between the instrument and dentin surface and also provide an SLA to the apical region of the canal.^[6] It also reduces instrument separation and helps in calculating accurate WL.^[11] However, this should not be achieved at the expense of tooth integrity, thus the instrument selection for this purpose should be done with conservation in mind. The present study intended to assess the canal preflaring efficacy of LA Axxess bur in comparison to Protaper Sx and GG drills, as the former claims to be more conservative owing to its safe ended tip design and titanium nitride coating. Although studies have been done comparing the efficacy of LA Axxess bur, very few have utilised CBCT imaging to compare the pre- and post-cervical flaring with these burs.^[12,13]

The canal-file angle (angle ABC) was made use of to study the ability of various instruments to achieve SLA that is a reduction in the cervical curvature. As the instrument removes radicular dentin in the coronal third, the file tends to be placed straighter in the canal, and the canal-file angle decreases. According to the present study, LA Axxess burs caused a maximum reduction in the canal-file angle and thus

Groups	Mean±SD		Mean change	P##
	Pre	Post		
I (LA Axxess)	12.37±1.01	8.12±1.65 ^{a,b}	4.25±1.14 ^{a,b}	0.0001*
II (Gates Glidden)	13.39±0.84	10.10±1.05 ^b	3.28±1.22 ^b	0.0001*
III (ProTaper Sx)	13.90±1.74	11.01±1.98 ^a	2.89±1.53 ^a	0.0001*
P#	0.06	0.001*	0.001*	

#ANOVA, ##Paired *t*-test, ^aP=0.0001, ^bP=0.005 (Tukey's *post hoc* comparison test), *Significant mean change is 13.90-11.01=2.89. SD: Standard deviation

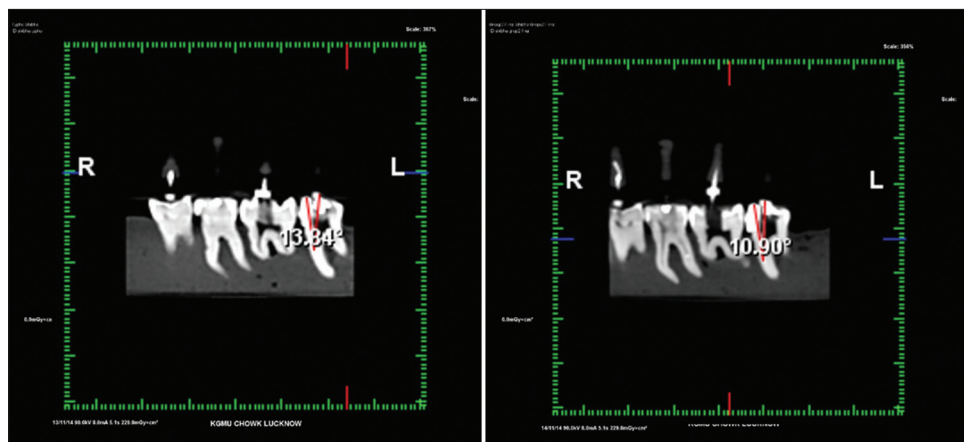


Figure 2: Pre and postinstrumentation cone beam computed tomography images of LA Axxess group

maximum reduction of cervical curvature, (mean change 4.25 ± 1.14 , $P = 0.0001$) which was significantly higher than the Protaper Sx and GG drill groups. These instruments cut dentin at orifice level and dentin walls at pulp chamber at the same time, thus allowing more controlled apical cutting. The present results are in accordance to a study by Duarte *et al.*^[12] in which LA Axxess bur was most effective in removing coronal dentin, however, the authors cautioned against the use of size 35/0.06 taper burs as they may cause strip perforation, especially in the mesial roots of mandibular first molars. The results of their study suggested that size 20/0.06 taper was safe for preflaring mesial canals of mandibular first molars.

In a stereomicroscopic study by Sharma *et al.*,^[13] LA Axxess burs were found to be most effective in cervical preflaring among Protaper RaCe, HyFlex, Flexmaster, and GG drills and produced the least discrepancy between the anatomical diameter and first file to bind at the WL.^[13]

GG drills ranked second in reducing the canal-file angle and creating a straighter canal (Mean change 3.28 ± 1.22) among the three systems. Although GG drills are conventionally and one of the most commonly used instruments for cervical preflaring, these have an aggressive cutting action and do not have a taper and tend to cut more toward the furcal wall.^[8] It has been shown that even anticurvature filing motion does not reduce the risk of perforation by GG drills.^[7] However, studies have shown that if used with caution they can be an inexpensive tool for coronal preflaring. Protaper Sx produced least change in the canal curvature among the three groups (mean change 2.88 ± 1.53). This may be due to the tendency of these instruments to remain centered in the canal and possess less aggressive radial lands.^[14] One of the

Table 2: Mean percentage change from prestraight line access to poststraight line access

Groups	Mean percentage change (mean±SD)
I (LA Axxess)	34.7±9.6
II (Gates Glidden)	24.3±8.6
III (ProTaper Sx)	20.5±10.3

SD: Standard deviation

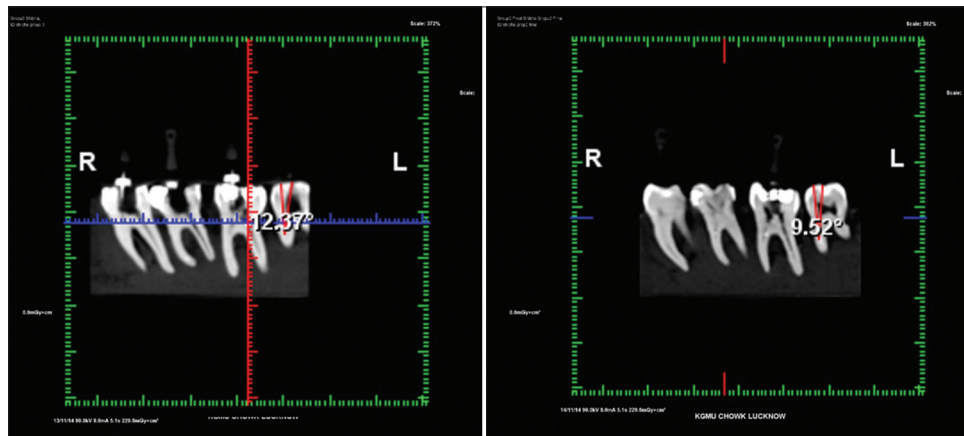


Figure 3: Pre and postinstrumentation Cone beam computed tomography images of Gates Glidden group

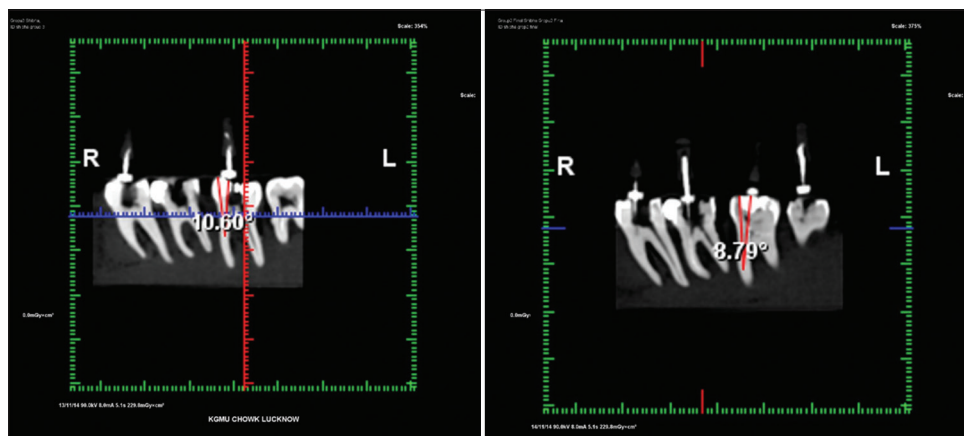


Figure 4: Pre and postinstrumentation Cone beam computed tomography images of Protaper Sx group

limitations of these instruments is that they cut dentin uniformly toward outward, thus increasing risk for more dentinal loss at furcal level.^[15]

CBCT proved to be an effective tool in assessing the pre- and post-instrumentation changes in the canal curvature as it is more accurate, three-dimensional and provides better spatial resolution, especially in areas like mesial root of mandibular first molars (as in the present study) which have grooves in the mesial or distal aspect thus confounding the conventional two-dimensional radiographic images.^[16,17] The mean change in the canal file angle demonstrated a significant change in pre and postgroups of all the groups and proved to be a convenient way to analyze the adequacy of SLA produced. In a similar study, using preSLA and postSLA CBCT images, Farhad Mollashahi *et al.*^[18] compared the SLA produced and effect of preflaring on the fit of the initial apical file after preparing the canals with FlexMaster Intro File, Pre-RaCe, and GG drills. However, according to results of their study, GG drills were more effective than NiTi instruments in reducing the cervical curvature.

CONCLUSION

Within the limitations of the present study, it can be said that cervical preflaring helps to achieve an SLA to the apical one-third of the root canal. The instrument selection for preflaring should be able to achieve this goal without causing much damage to the remaining tooth structure. LA Axxess bur, which has safe ended head design, was most effective in reducing the cervical curvature and thus producing a better SLA compared to GG drills and Protaper Sx files, but more studies are required to evaluate its effect on remaining dentin thickness of the radicular dentin.

Financial support and sponsorship

Nil.

Conflicts of interest

There are no conflicts of interest.

REFERENCES

1. Leeb J. Canal orifice enlargement as related to biomechanical preparation. *J Endod* 1983;9:463-70.
2. Sureshchandra B, Gopikrishna V. Grossman's Endodontic Practice. 12th ed. New Delhi: Wolter's-Kluwer (India) Pvt. Ltd.; 2010.
3. Peters O, Koka R. Preparation of coronal and radicular space. In: Ingle JJ, Bakland LK, Baumgartner JC, editors. *Endodontics*. 6th ed. Hamilton: BC Decker Inc.; 2008. p. 877-81.
4. Vertucci F, Haddix J. Tooth morphology and access cavity preparation. In: Hargreaves KM, Cohen S, editors. *Pathways of the Pulp*. 10th ed. St. Louis: Mosby; 2011. p. 160-2.
5. Weine FS, Kelly RF, Lio PJ. The effect of preparation procedures on original canal shape and on apical foramen shape. *J Endod* 1975;1:255-62.
6. Morgan LF, Montgomery S. An evaluation of the crown-down pressureless technique. *J Endod* 1984;10:491-8.
7. Isom TL, Marshall JG, Baumgartner JC. Evaluation of root thickness in curved canals after flaring. *J Endod* 1995;21:368-71.
8. Busquim SS, dos Santos M. Cervical shaping in curved root canals: Comparison of the efficiency of two endodontic instruments. *Braz Oral Res* 2002;16:327-31.
9. Schneider SW. A comparison of canal preparations in straight and curved root canals. *Oral Surg Oral Med Oral Pathol* 1971;32:271-5.
10. Torabinejad M, Sigurdsson A. Evaluation of endodontic outcomes. In: Torabinejad M, Walton R, editors. *Endodontics Principles and Practice*. 4th ed. St. Louis, Missouri: Elsevier; 2009. p. 383.
11. Ehrhardt IC, Zuolo ML, Cunha RS, De Martin AS, Kherlakian D, Carvalho MC, *et al.* Assessment of the separation incidence of Mtwo files used with preflaring: Prospective clinical study. *J Endod* 2012;38:1078-81.
12. Duarte MA, Bernardes RA, Ordinola-Zapata R, Vasconcelos BC, Bramante CM, Moraes IG. Effects of Gates-Glidden, LA Axxess and orifice shaper burs on the cervical dentin thickness and root canal area of mandibular molars. *Braz Dent J* 2011;22:28-31.
13. Sharma SA, Tyagi SP, Sinha DJ, Singh UP, Chandra P, Kaur G. Influence of cervical preflaring using different rotary instruments on the accuracy of apical file size determination: A comparative *in-vitro* study. *J Conserv Dent* 2014;17:575-8.
14. Mahran AH, AboEl-Fotouh MM. Comparison of effects of ProTaper, HeroShaper, and Gates Glidden burs on cervical dentin thickness and root canal volume by using multislice computed tomography. *J Endod* 2008;34:1219-22.
15. Martin LR, Gilbert B, Dickerson AW 2nd. Management of endodontic perforations. *Oral Surg Oral Med Oral Pathol* 1982;54:668-77.
16. Al-Nuaimi N, Patel S, Foschi F, Mannocci F. The detection of simulated periapical lesions in human dry mandibles with cone beam computed tomography – A dose reduction study. *Int Endod J* 2015. [Doi: 10.1111/iej.12565]. [Epub ahead of print].
17. Durack C, Patel S. Cone beam computed tomography in endodontics. *Braz Dent J* 2012;23:179-91.
18. Farhad Mollashahi N, Sohrabi M, Farhad Mollashahi L, Mehdizadeh M. The efficacy of FlexMaster's IntroFile, PreRaCe and gates Glidden drills in straight-line access: A CBCT assessment. *Iran Endod J* 2014;9:199-203.