

Clinical and radiographic comparison of various medicaments used for pulpotomy in primary molars: A randomized clinical trial

Prachi Goyal¹, I. K. Pandit², Neeraj Gugnani², Monica Gupta², Richa Goel³,
Ramandeep Singh Gambhir⁴

¹Department of Pedodontics, MM College of Dental Sciences and Research, Mullana, Haryana, India,

²Department of Pedodontics, DAV Dental College, Yamuna Nagar, Haryana, India,

³Department of Public Health Dentistry, MM College of Dental Sciences and Research, Mullana, Haryana, India,

⁴Department of Public Health Dentistry, Rayat and Bahra Dental College and Hospital, Mohali, Punjab, India

Correspondence: Dr. Ramandeep Singh Gambhir
Email: raman2g@yahoo.com

ABSTRACT

Objective: To evaluate and compare the efficacy of ferric sulfate, glutaraldehyde, and mineral trioxide aggregate (MTA) as pulpotomy medicaments in primary molars. **Materials and Methods:** This was a perspective randomized clinical trial. A total of 90 molars from 42 children aged 4–8 years were selected for pulpotomy procedure. Teeth were randomly divided into three equal groups of 30 teeth each. Teeth in Group I were intended to be treated with ferric sulfate, Group II were intended to be treated with buffered glutaraldehyde and Group III with MTA. All the molars were evaluated clinically at 24 h and both clinically and radio graphically at 1, 3, and 6 months. The observations were statistically analyzed using Chi-square test and Fisher's exact test. **Results:** After 1 month, there was no clinical finding observed in all the three groups. At 3 months postoperative evaluation, 13.3% of teeth in Group I and 12.5% of teeth in Group II had mobility. At 6 months interval, pain and sinus formation each was noted in 9.1% of primary teeth in Group I while periodontal ligament widening was reported in 66.7% of teeth in Group I and 85.7% of teeth in Group II. **Conclusion:** MTA exhibited overall best results as pulpotomy agent for primary molars followed by 15.5% ferric sulfate, whereas 2% buffered glutaraldehyde was found to be least effective as a pulpotomy agent.

Key words: Ferric sulfate, glutaraldehyde, mineral trioxide aggregate, primary molars, pulpotomy

INTRODUCTION

Natural primary teeth are considered as best space maintainers; hence every effort should be directed to preserve these teeth as far as possible. One of the most

important goals of pediatric dentistry is the restoration and maintenance of carious primary teeth.^[1]

This is an open access article distributed under the terms of the Creative Commons Attribution-NonCommercial-ShareAlike 3.0 License, which allows others to remix, tweak, and build upon the work non-commercially, as long as the author is credited and the new creations are licensed under the identical terms.

For reprints contact: reprints@medknow.com

How to cite this article: Goyal P, Pandit IK, Gugnani N, Gupta M, Goel R, Gambhir RS. Clinical and radiographic comparison of various medicaments used for pulpotomy in primary molars: A randomized clinical trial. Eur J Dent 2016;10:315-20.

DOI: 10.4103/1305-7456.184144

Access this article online

Quick Response Code:



Website:
www.eurjdent.com

Pulpotomy is performed in those primary teeth in which caries removal has resulted in mechanical pulp exposure.^[2] Formocresol, a popular pulpotomy medicament based on the principle of devitalization, was considered as the gold standard in performing vital pulpotomy for primary teeth for the past 60 years.^[3] However, in spite of years of success of its use, concerns had been raised about its potential toxicity, mutagenicity and carcinogenicity in humans.^[4] A possible substitute for formocresol is glutaraldehyde which has been advocated because of its superior cross linking ability and better fixative property besides being less volatile causing less apical penetration with less dystrophic pulp calcification and more initial chemical activity than formocresol.^[5]

Ferric sulfate was used in the study due to its hemostatic action, and since its time of application is only 30 s, it is very beneficial especially in case of children. However, the agglutinated proteins form plugs that occlude the capillary orifices.^[6] Mineral trioxide aggregate (MTA), a relatively newer material, is composed of tricalcium oxide, tricalcium silicate, tricalcium aluminate, and silicate oxide. It is biocompatible, has high sealing ability, ability to form dentinal bridge and can cause regeneration of cementum and periodontal ligament (PDL).^[7]

Due to scanty literature on comparative studies regarding the efficacy of various pulpotomy medicaments, the present study was undertaken to evaluate and compare the efficacy of ferric sulfate, glutaraldehyde, and MTA as pulpotomy medicaments in primary molars. The present study was planned in accordance with a previous study which evaluated the long-term effectiveness of four pulpotomy techniques in which pulpotomies using ferric sulfate revealed the best treatment outcome.^[8]

MATERIALS AND METHODS

Ethical clearance and consent

The study was conducted in 2012 in DAV Dental College Yamuna Nagar, Haryana. Single independent investigator (PG) conducted all the procedures under the supervision of the study guide (IKP). Before the start of the study, ethical approval was obtained from the Institutional Ethics Committee for conducting the study. Informed consent was obtained from the parents of children before their final recruitment into the study.

Selection of patients and division of samples

Children in the age group of 4–8 years visiting the outpatient clinics in the Department of Pedodontics and Preventive Dentistry with a chief complaint of one or more decayed teeth were screened. Patients with any signs of internal or external resorption were excluded from the study. Finally 42 patients were included in the study. Sample size was calculated on the basis of the following formula.

$n = 2 (Z_{\alpha} + Z_{1-\beta})^2 \sigma^2 / \Delta^2$, where n is the required sample size.

Using simple random sampling, 90 primary molars from selected patients were divided equally into three groups. Teeth in different groups were intended to be treated with different pulpotomy agents—that is 15.5% ferric sulfate, 2% buffered glutaraldehyde, and MTA. Clinical and radiographic evaluations of the teeth were conducted at 24 h, 1 month, 3 months and 6 months, intervals by two independent examiners who had no knowledge of the group to which the particular tooth was assigned. Patients were assessed using different clinical and radiological parameters which were also used for future postoperative evaluations. The absence/presence of all the clinical and radiological signs was recorded. Before grading the X-ray films, the examiners were asked to evaluate 14 posterior periapical radiographs not included in the study to establish a consensus. Clinical parameters included pain, sinus formation, swelling (intra oral), and mobility while the radiological parameters included PDL widening, internal resorption, external resorption, periapical radiolucency, canal obliteration, and furcation radiolucency. The presence of each sign was recorded as a digital score of “1” and the absence was recorded as a digital score of “2.” The overall success of the treatment was assessed according to both clinical and radiographic findings.

Clinical procedure

Pulpotomy procedure was performed for the selected primary molars and different medicaments were then applied after coronal pulp removal.

Group I (Ferric sulfate): A sterile cotton pellet no. 4 moistened with 15.5% ferric sulfate (Astringedent - 60 ml; Ultradent products, USA) was placed in contact with the radicular pulp for 15 s. After irrigation with normal saline and observation of haemostasis, zinc oxide eugenol paste was applied on the pulp tissue.

Group II (2% buffered glutaraldehyde): After coronal pulp amputation, a sterile cotton pellet no. 4 moistened in 2% buffered glutaraldehyde solution (2% glutaraldehyde in 1 l with a solution activator of 6.5 g Bioclenz-G) was placed on amputated pulp stumps for 5 min. Cotton pellet was removed and zinc oxide eugenol paste was placed over the pulp stumps.

Group III (MTA): After obtaining hemostasis with sterile cotton pellets no. 4, pulp stumps were covered with a thin layer of MTA paste, which was prepared by mixing MTA powder with sterile saline at a 3:1 powder/saline ratio to obtain a thick, creamy consistency. The MTA base was placed on the floor of the pulp chamber and condensed against the pulp orifices with a moist cotton pellet. The cavity was then filled with zinc oxide eugenol.

Following pulpotomy, all the teeth were restored with stainless steel crown (3M)/light cure glass ionomer cement (GC Fuji I, GC America, Alsip, IL, USA) after 24 h. Children were recalled postoperatively after 24 h for clinical evaluation and after 1 month, 3 months and 6 months both for clinical and radiographical evaluation.

Statistical analysis

The recorded data was transferred to a personal computer and statistical analysis was carried out using SPSS package version 15 (SPSS Inc., Chicago, IL). Descriptive statistics were calculated using Chi-square test and Fisher's exact test. Statistical significance was set at $P < 0.05$.

RESULTS

At 24-h postoperative interval, none of the groups had presence of any clinical and radiological finding. In addition, at 1 month there was no clinical and radiological finding observed in all the three groups. After 3 months, 16 primary molars were lost to follow-up. This number increased to a total of 32 after 6 months [Figure 1]. At 24-h postoperative interval, none of the groups had presence of any clinical finding. At 1 month, there was no clinical finding observed in all the three groups. However, there was higher incidence of PDL widening and furcation radiolucency in Group I and Group II subjects as compared to Group III and the findings were statistically significant ($P < 0.05$) [Table 1].

After 3 months evaluation, 13.3% of teeth in Group I and 12.5% of teeth in Group II had mobility but the findings were statistically insignificant ($P = 0.369$)

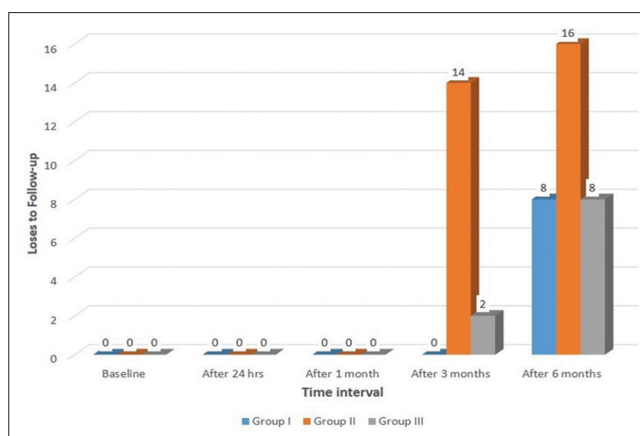


Figure 1: Losses to follow-up at various time intervals

[Table 2]. PDL was noticed in 73.3% of teeth in Group I and 62.5% of subjects in Group II and the findings were highly significant as compared to Group III ($P < 0.001$).

After 6 months, evaluation was done, pain and sinus formation each was noted in 9.1% of primary teeth in Group I while mobility was noticed in 27.3% of teeth in Group I and 57.1% of teeth in Group II [Table 3]. No clinical finding was reported in teeth present in Group III. In radiological parameters, PDL widening was reported in 66.7% of teeth in Group I and 85.7% of teeth in Group II. However, furcation radiolucency was noticed in 100% of primary molars in Group II and findings were statistically significant when compared to Group III ($P < 0.05$).

DISCUSSION

Primary molars treated with MTA showed 100% clinical success. Similar finding was observed in some other studies.^[9,10] Pain after 6 months was reported in 57.1% patients treated with glutaraldehyde and only 9.1% patients treated with ferric sulfate. However, reports of some other study revealed greater clinical success (lesser no. of patients felt pain) with ferric sulfate.^[11] The difference could be attributed to the dissimilar techniques and duration of study.

Success or failure of pulpotomy treatment is dependent upon an accurate diagnosis at the time of treatment. It is worth mentioning here that all the teeth included in the study were affected by caries. It is essential for the radicular pulp to be healthy at the time of treatment to increase the success rate of the procedure. Teeth treated with MTA did not show any sinus formation which could be due to its antibacterial properties.

Table 1: Postoperative evaluation after 1 month interval

Parameter	Group I (n=30)		Group II (n=30)		Group III (n=30)		Significance of difference	
	n	Percentage	n	Percentage	n	Percentage	χ^2	P
Clinical parameters								
Pain	0	0	0	0	0	0	-	-
Sinus formation	0	0	0	0	0	0	-	-
Swelling	0	0	0	0	0	0	-	-
Mobility	0	0	0	0	0	0	-	-
Radiological parameters								
Periodontal ligament widening	16 ^c	53.3	8	26.7	0 ^a	0	10.909	0.004
Internal resorption	8	26.7	0	0	0	0	8.780	0.012
External resorption	0	0	0	0	0	0	-	-
Periapical radiolucency	0	0	0	0	0	0	-	-
Canal obliteration	0	0	2	6.7	0	0	2.045	0.360
Furcation radiolucency	14 ^c	46.7	6	20.0	0 ^a	0	9.514	0.009

^aSignificant as compared to Group I, ^bSignificant as compared to Group II, ^cSignificant as compared to Group III (Fisher's exact test)

Table 2: Postoperative evaluation after 3 months interval

Parameter	Group I (n=30)		Group II (n=16)		Group III (n=28)		Significance of difference	
	n	Percentage	n	Percentage	n	Percentage	χ^2	P
Clinical parameters								
Pain	0	0	0	0	0	0	-	-
Sinus formation	0	0	0	0	0	0	-	-
Swelling	0	0	0	0	0	0	-	-
Mobility	4	13.3	2	12.5	0	0	1.992	0.369
Radiological parameters								
Periodontal ligament widening	22 ^c	73.3	10 ^c	62.5	0 ^{a,b}	0	17.409	<0.001
Internal resorption	12 ^c	60.0	2	12.5	0 ^a	0	7.927	0.020
External resorption	6	20.0	2	12.5	0	0	3.034	0.219
Periapical radiolucency	4	13.3	2	12.5	0	0	1.992	0.369
Canal obliteration	0	0	2	12.5	0	0	3.726	0.155
Furcation radiolucency	20 ^c	66.7	10 ^c	62.5	0 ^{ab}	0	15.393	<0.001

^aSignificant as compared to Group I, ^bSignificant as compared to Group II, ^cSignificant as compared to Group III (Fisher exact test)

Table 3: Postoperative evaluation after 6 months interval

Parameter	Group I (n=22)		Group II (n=14)		Group III (n=22)		Significance of difference	
	n	Percentage	n	Percentage	n	Percentage	χ^2	P
Clinical parameters								
Pain	2 ^b	9.1	8 ^{ac}	57.1	0 ^b	0.0	10.615	0.001
Sinus formation	2	9.1	6 ^c	42.9	0 ^b	0	6.937	0.031
Swelling	0	0	0	0	0	0	-	-
Mobility	6	27.3	8 ^c	57.1	0 ^b	0	7.723	0.021
Radiological parameters								
Periodontal ligament widening	14	66.7	12 ^c	85.7	0 ^b	0	15.242	<0.001
Internal resorption	12	54.5	2	14.3	0 ^a	0	9.425	0.009
External resorption	6	27.3	8 ^c	57.1	0 ^b	0	7.723	0.021
Periapical radiolucency	4	18.2	6 ^c	42.9	0 ^c	0	5.518	0.063
Canal obliteration	0	0	4	28.6	0	0	6.751	0.034
Furcation radiolucency	16 ^a	72.7	14 ^c	100	0 ^{ac}	0	20.262	<0.001

^aSignificant as compared to Group I, ^bSignificant as compared to Group II, ^cSignificant as compared to Group III (Fisher exact test)

Some other studies also reported similar results.^[9,12] Sinus formation was seen in only 9.1% cases of ferric

sulfate. However, contradictory results were reported in some other studies conducted elsewhere.^[8,13]

Absence of swelling on postoperative evaluations at all recall intervals in all groups is a clear parameter of success, proper case selection and maintenance of complete intra operative aseptic conditions achieving the proper hermetic seal. This finding is consistent with couple of other studies.^[13,14] Tooth mobility was not observed in patients treated with MTA, whereas only 27.3% patients treated with ferric sulfate and 57.1% treated with glutaraldehyde showed tooth mobility at 6 months interval. This could be due to widening of PDL space.

MTA treated teeth did not show PDL widening due to its stimulatory effect on the biosynthetic activity of peri radicular cells. This was in accordance with another study.^[15] Widening of PDL was observed in 66.7% of teeth treated with ferric sulfate and 85.7% teeth treated with glutaraldehyde after 6 months. This could be attributed to occlusal trauma or lack of bone support arising from advanced bone loss. Our findings were consistent with couple of other studies in which most common pathologic finding was PDL widening.^[13,16]

In the current study, MTA treated teeth did not show internal and external resorption. Similar findings were observed in some other study in which MTA was used to treat internal resorption.^[17] However, internal resorption was noted in pulpotomies performed with ferric sulfate pulpotomy (54.5%) and glutaraldehyde (14.3%). External resorption in case of patients treated with ferric sulfate and glutaraldehyde could be attributed to periapical inflammatory lesion which resulted in the loss of lamina dura around the apex.

Periapical radiolucency observed in cases of ferric sulfate and glutaraldehyde could be attributed to the release of bacteria and their toxins via the apical foramina.^[18] In our study, MTA did not show any periapical radiolucency, which could be due to its biocompatibility and the resistance to bacterial penetration in the periapical areas.

Obliteration of the pulp canal was found in approximately one-third of the teeth treated with glutaraldehyde after 6 months in the present study which is also supported by some other study.^[19] Furcation radiolucency was observed in more than 70% of teeth treated with ferric sulfate and all the patients treated with glutaraldehyde. These findings were consistent with other studies.^[16,20] However, radiographic success with ferric sulfate was reported in some other study.^[21] In our study MTA did not show

any signs of furcation radiolucency which could be explained on the basis of hard tissue bridge formation due to its high sealing ability, biocompatibility, alkalinity and superior seal against bacteria.

To summarize, MTA was found to be a more successful medicament for cariously exposed primary molar as compared to 15.5% ferric sulfate and 2% buffered glutaraldehyde.

In order to come to conclusive results, a detailed longitudinal study involving larger follow ups is required and teeth need to be monitored until their physiological exfoliation. Moreover, studies involving large samples should be conducted to make the results more generalizable.

CONCLUSION

At the end of the study, it was observed that Group III (MTA) exhibited overall best results as pulpotomy agent for primary molars followed by 15.5% ferric sulfate, whereas, 2% buffered glutaraldehyde showed least favorable results both clinically and radiographically. However further larger sample size and longer observational period should be carried out to reach sound conclusion.

Financial support and sponsorship

Nil.

Conflicts of interest

There are no conflicts of interest.

REFERENCES

1. Corica A, Caprioglio A. Meta-analysis of the prevalence of tooth wear in primary dentition. *Eur J Paediatr Dent* 2014;15:385-8.
2. Shirazi AS, Rezaifar M, Talebi M, Mortazavi A, Malekabadi KS. Application of bonding system as a sub-base material following electrosurgical pulpotomy treatment in primary teeth: A novel technique. *Iran J Med Hypotheses Ideas* 2009;3:12.
3. Agamy HA, Bakry NS, Mounir MM, Avery DR. Comparison of mineral trioxide aggregate and formocresol as pulp-capping agents in pulpotomized primary teeth. *Pediatr Dent* 2004;26:302-9.
4. Chandrashekar S, Shashidhar J. Formocresol, still a controversial material for pulpotomy: A critical literature review. *J Res Dent* 2014;2:114-24.
5. Havale R, Aneundi RT, Indushekar K, Sudha P. Clinical and radiographic evaluation of pulpotomies in primary molars with formocresol, glutaraldehyde and ferric sulphate. *Oral Health Dent Manag* 2013;12:24-31.
6. Eidelman E, Holan G, Fuks AB. Mineral trioxide aggregate vs. formocresol in pulpotomized primary molars: A preliminary report. *Pediatr Dent* 2001;23:15-8.
7. Farsi N, Alamoudi N, Balto K, Al Mushayt A. Clinical assessment of mineral trioxide aggregate (MTA) as direct pulp capping in young permanent teeth. *J Clin Pediatr Dent* 2006;31:72-6.
8. Huth KC, Hajek-Al-Khatat N, Wolf P, Ilie N, Hickel R, Paschos E. Long-term effectiveness of four pulpotomy techniques:

- 3-year randomised controlled trial. Clin Oral Investig 2012;16:1243-50.
9. Naik S, Hegde AH. Mineral trioxide aggregate as a pulpotomy agent in primary molars: An *in vivo* study. J Indian Soc Pedod Prev Dent 2005;23:13-6.
 10. Holan G, Eidelman E, Fuks AB. Long-term evaluation of pulpotomy in primary molars using mineral trioxide aggregate or formocresol. Pediatr Dent 2005;27:129-36.
 11. Farrokh Gisoure E. Comparison of three pulpotomy agents in primary molars: A randomised clinical trial. Iran Endod J 2011;6:11-4.
 12. Farsi N, Alamoudi N, Balto K, Mushayt A. Success of mineral trioxide aggregate in pulpotomized primary molars. J Clin Pediatr Dent 2005;29:307-11.
 13. Casas MJ, Kenny DJ, Johnston DH, Judd PL. Long-term outcomes of primary molar ferric sulfate pulpotomy and root canal therapy. Pediatr Dent 2004;26:44-8.
 14. Huth KC, Paschos E, Hajek-Al-Khatat N, Hollweck R, Crispin A, Hickel R, *et al.* Effectiveness of 4 pulpotomy techniques – Randomized controlled trial. J Dent Res 2005;84:1144-8.
 15. Torabinejad M, Pitt Ford TR, McKendry DJ, Abedi HR, Miller DA, Kariyawasam SP. Histologic assessment of mineral trioxide aggregate as a root-end filling in monkeys 1997. Int Endod J 2009;42:408-11.
 16. Ranly DM, Garcia-Godoy F, Horn D. Time, concentration, and pH parameters for the use of glutaraldehyde as a pulpotomy agent: An *in vitro* study. Pediatr Dent 1987;9:199-203.
 17. Sari S, Sönmez D. Internal resorption treated with mineral trioxide aggregate in a primary molar tooth: 18-month follow-up. J Endod 2006;32:69-71.
 18. Caicedo R, Abbott PV, Alongi DJ, Alarcon MY. Clinical, radiographic and histological analysis of the effects of mineral trioxide aggregate used in direct pulp capping and pulpotomies of primary teeth. Aust Dent J 2006;51:297-305.
 19. Tsai TP, Su HL, Tseng LH. Glutaraldehyde preparations and pulpotomy in primary molars. Oral Surg Oral Med Oral Pathol 1993;76:346-50.
 20. Fei AL, Udin RD, Johnson R. A clinical study of ferric sulfate as a pulpotomy agent in primary teeth. Pediatr Dent 1991;13:327-32.
 21. Yildiz E, Tosun G. Evaluation of formocresol, calcium hydroxide, ferric sulfate, and MTA primary molar pulpotomies. Eur J Dent 2014;8:234-40.