

Biocompatibility of a new epoxy resin-based root canal sealer in subcutaneous tissue of rat

Neslihan Simsek¹, Levent Akinci¹, Orhan Gecor², Hilal Alan², Fuat Ahmetoglu¹, Elif Taslidere³

Correspondence: Dr. Neslihan Simsek
Email: dtneslihan@hotmail.com

¹Department of Endodontics, Faculty of Dentistry, Inonu University, Malatya, Turkiye,

²Department of Oral and Maxillofacial Surgery, Faculty of Dentistry, Inonu University, Malatya, Turkiye,

³Department of Histology and Embriology, Faculty of Medicine, Inonu University, Malatya, Turkiye

ABSTRACT

Objective: The objective was to evaluate the subcutaneous biocompatibility of two root canal sealers. **Materials and Methods:** Thirty female rats were distributed into two groups of 15 animals. Each received subcutaneous dorsal implants: Silicone tubes filled with AH Plus or Obtuseal. After the 11th, 14th, and 45th days, tissues were collected for biopsy and fixed and processed for histologic evaluation. Observations of the cellular inflammatory components, such as lymphocytes and macrophages, were made. The data were analyzed using Kruskal–Wallis and Conover tests ($P < 0.05$). **Results:** By the 7th day, lymphocyte infiltration increased in both groups ($P = 0.0104$). However, macrophage infiltration increased only in the AH Plus group ($P = 0.0011$). By the 14th and 45th days, lymphocyte and macrophage infiltrations were reduced. At the end of the experimental period, no statistically significant differences were found between the AH Plus group and the Obtuseal group ($P > 0.05$). **Conclusion:** After 45 days, Obtuseal yielded a satisfactory tissue reaction; it was biocompatible when tested in subcutaneous rat tissue. On the basis of the obtained results, it was concluded that Obtuseal root canal sealer caused a satisfactory tissue reaction as AH plus, because it was biocompatible when tested in the subcutaneous tissue of rats.

Key words: Biocompatibility, endodontics, epoxy resin-based sealers, tissue reaction

INTRODUCTION

The purpose of root canal treatment is to eliminate infection in the root canals and improve the esthetic and functional longevity of teeth in the oral cavity via a complete filling of the root canal spaces.^[1] The best root canal treatment results are achieved with adequate instrumentation and homogeneous root canal filling in the apical limits,^[2,3] while poor outcomes occur as a result of over instrumentation and filling beyond the apical limit.^[2] Biocompatibility is one of the most important characteristics of root filling materials, because the release of certain chemicals by the sealers may cause various reactions in the periapical tissues.^[4,5] One of the commonly accepted definitions of biocompatibility is that the material used will have

an appropriate biological response to host tissue during a specific application. This definition includes the interactions between the host, the material and its expected function. If a material is biocompatible, these three components should be in harmony.^[6]

This interaction occurs where the root canal sealers come into contact with living tissues, and consequently, the biological response that occurs is an immune reaction.^[7]

The effect of endodontic sealers on macrophage activity is important, because these cells play a key role in native and acquired immune defenses and in the pathogenesis of inflammation.^[8] Furthermore, macrophages are the dominant cells in periradicular tissues.^[9]

How to cite this article: Simsek N, Akinci L, Gecor O, Alan H, Ahmetoglu F, Taslidere E. Biocompatibility of a new epoxy resin-based root canal sealer in subcutaneous tissue of rat. *Eur J Dent* 2015;9:31-5.

Copyright © 2015 Dental Investigations Society.

DOI: 10.4103/1305-7456.149635

A simple, preferred method of testing the biocompatibility of endodontic sealers is the implantation of the material into the subcutaneous connective tissue of rats. The irritating effect of the materials can be evaluated via the histopathological examination of tissue response around the implants.^[10-12] There have been many studies of the biocompatibility of AH Plus (Dentsply De Trey GmbH, Germany) root canal sealers in the literature.^[13-15] Recently, Obtuseal (A.T.O., Zizine, France), an epoxy resin-based root canal sealer, was developed. Obtuseal's base tube contains TCD-diamine, a radiopaque excipient (excipient radiopaque), and the catalyst tube contains calcium hydroxide, diglycidyl ether of bisphenol A (DGEBA) and radiopaque excipient. In contrast, AH Plus does not contain DGEBA or, more importantly, calcium hydroxide.

There has not been any experimental animal study to assess Obtuseal root canal sealer's biocompatibility in comparison with other materials yet. Thus, this study aims to compare the biocompatibility of this new endodontic filling material with the AH plus. Both of these materials are epoxy resin-based. AH Plus has been used for a long time, but Obtuseal root canal sealer is a relatively new material.

MATERIALS AND METHODS

The study protocol was reviewed and approved by the experimental animal Ethics Committee of Inonu University of Health Sciences (2013/A-16). Thirty healthy Wistar-Albino female rats (3–4 months and approximately 240–280 g) were used in the study. The animals were randomly divided into two experimental groups: Group 1 was the AH Plus group; Group 2 was the Obtuseal group.

Before surgery, the rats were anesthetized via intraperitoneal ketamine HCL (50 mg/kg) and xylazine (7 mg/kg) injection. When an anesthetized rat became unresponsive, a 40 mm × 40 mm area on the neck was shaved and disinfected with povidone-iodine. A 1.5 mm incision was made through the skin with a scalpel, and four separate subcutaneous pockets were prepared via blunt dissection at each side of the incision.

One hundred and twenty sterilized polyethylene tubes (10 mm in length and 0.9 mm in diameter) were prepared with one side open and the other side closed. Two of four tubes for each experimental animal were filled with the specified root canal sealer according to the manufacturer's instructions and under aseptic conditions; the other two tubes were left empty

as a control. The filled tubes and the empty tubes were carefully placed in the left-side incision and in the right-side incision, respectively. After placing the tubes, the wound area was surgically stitched with a resorbable single suture (4/0 silk suture) and disinfected with povidone-iodine.

After the tubes were placed, the experimental animals were put into identified cages and received a normal diet (solid food) and water *ad libitum* during the entire study period.

At the end of each period (7, 14, and 45 days), five animals were killed. The animals were sacrificed via cervical dislocation (after anesthesia), as proposed by the Ethics Committee.

Histological evaluation

Tissue samples from the areas that contained the tubes were fixed in 10% formalin for 24 h and embedded in paraffin. Sections were cut at 5 µm, mounted on slides and stained with hematoxylin and eosin to view the general tissue structure. Tissue inflammation was scored for each of the following tissue inflammation indicators: Lymphocyte and macrophage infiltration were scored on a moderate scale of 0–3: Zero for normal tissue, one for mild, two for moderate, and three for severe reactions.^[16] The total histology score is the sum of the scores for all the parameters. Tissues were examined using a Leica DFC280 light microscope and a Leica Q Win Image Analysis system (Leica Micros Imaging Solutions Ltd., Cambridge, UK).

Statistical analysis

Statistical analysis was performed using Statistical Package for the Social Sciences (SPSS) for Windows (Version 15.0, SPSS Inc., Chicago, IL, USA) and given as means ± standard deviations. Within the groups, the normality of the variables was measured using the Shapiro–Wilk test. The data were analyzed using Kruskal–Wallis and Conover tests. A value of $P < 0.05$ was considered significant.

RESULTS

Histopathological findings

The data were compared during each period of time and are presented in Table 1. The experimental and control groups of tested materials are shown in Figures 1 and 2, respectively.

Lymphocyte infiltration

There were statistically significant changes in lymphocyte infiltration in the 7th-day groups when

Table 1: Means and SDs of the histopathological scores for lymphocyte and macrophage infiltration

Groups	Mean±SD					
	7 th day		14 th day		45 th day	
	Lymphocytes infiltration	Macrophages infiltration	Lymphocytes infiltration	Macrophages infiltration	Lymphocytes infiltration	Macrophages infiltration
AH plus control	0.10±0.30 ^{†,§}	0.05±0.22 ^{†,#}	0.12±0.33	0.07±0.26	0.07±0.26	0.02±0.15
AH plus	0.32±0.47 [†]	0.30±0.46 [§]	0.20±0.40	0.22±0.42	0.15±0.36	0.20±0.40
Obtuseal control	0.07±0.26 [§]	0.05±0.22 [#]	0.02±0.15	0.10±0.30	0.05±0.22	0.07±0.26
Obtuseal	0.25±0.43 ^{†,§}	0.27±0.45 ^{†,§,#}	0.17±0.38	0.17±0.38	0.12±0.33	0.15±0.36
<i>P</i>	0.0104	0.0011	0.0994	0.2042	0.4301	0.0653

Different superscript symbols in the same column mean statistical significant difference within the group. SD: Standard deviation, † means a, § means b, # means c

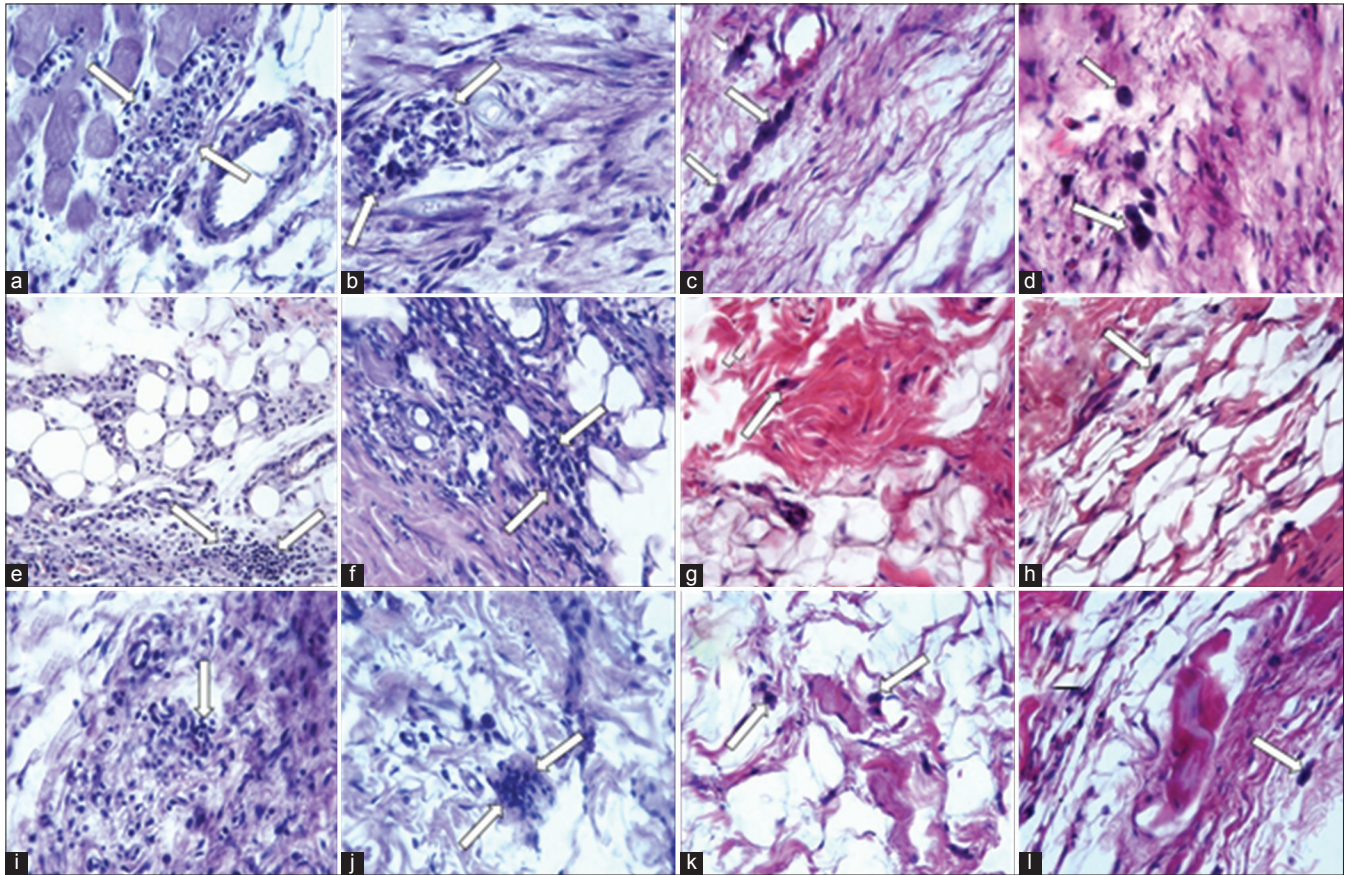


Figure 1: View of lymphocyte and macrophage cells (arrows) in the AH Plus and Obtuseal groups over all the experimental periods. A slight inflammatory reaction was observed in all test groups. 7 days: (a and b) Lymphocyte infiltration for the AH Plus and Obtuseal experimental groups, respectively. (c and d) Macrophage infiltration for the AH Plus and Obtuseal groups, respectively. 14 days: (e-h) Lymphocyte and macrophage infiltration for the two groups as described above. 45 days: (i-l) Lymphocyte and macrophage infiltration for the two groups as described above (H and E; ×40)

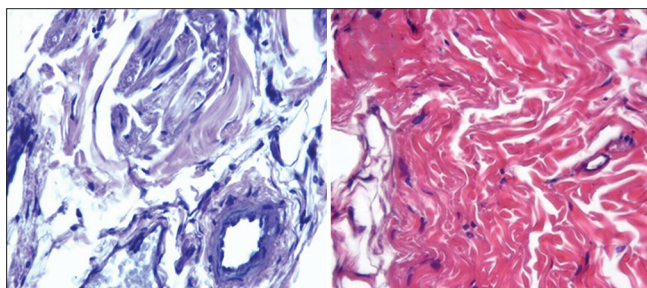


Figure 2: No inflammation was observed in control groups from 7th days

compared with the 14th and 45th day groups ($P = 0.0104$). However, no statistically significant differences were found between the AH Plus and Obtuseal groups on the 14th or 45th days ($P = 0.0994$, $P = 0.4301$).

Macrophages infiltration

While the AH Plus group showed a statistically significant increase in macrophage infiltration on the 7th day compared with the control group ($P = 0.0011$), there were no significant changes in the Obtuseal

group. No statistically significant differences were found between the AH Plus and Obtuseal groups on the 14th or 45th days ($P = 0.2042$, $P = 0.0653$).

DISCUSSION

The biocompatibility of dental materials is an important topic, because these materials contain toxic components that may cause irritation or distortion when placed in contact with periapical tissues and the surrounding tissues.^[17] Numerous procedures have been used to evaluate the biocompatibility of endodontic materials, including subcutaneous implantation tests. Rats were used in the present study because they are less susceptible to postoperative infection, easily obtainable and an acknowledged model for determining tissue biocompatibility.^[18] To confirm the resemblance to clinical circumstances and standardization, polyethylene tubes were selected for this study. Polyethylene tubes are passive in nature and are effective for testing materials in contact with nearby tissue.^[19]

The objective of this study was to conduct an *in vivo* experiment to evaluate the biocompatibility of the new endodontic sealer Obtuseal and another resinous sealer, AH Plus. Both are epoxy-resin-based sealers, but Obtuseal is also calcium-hydroxide-based. Root canal sealers including calcium hydroxide can speed up repair progressions and decrease the inflammatory replies produced by irritating components of the material in periapical tissues.^[1,20,21]

One of the most important granulation tissue components are macrophages. These cells remove cell remnants, fibrin, and other materials from the repair zone. They also stimulate the proliferation and migration of other inflammatory cells such as neutrophils, lymphocytes, and mast cells if only the adequate chemotactic stimuli are present. All these procedures are a part of migration and proliferation of fibroblasts for tissue recovery. However, when the inflammatory reply produced by root canal fillings is persistent, it may hinder the repair process, rather than playing the estimated defensive role, due to the toxic inflammatory components.^[22]

Although Obtuseal is already available on the market, there is currently no *in vivo* model that studies its tissue response in the literature. It is necessary to know if the handicaps can be observed in the *in vivo* model of research. This sealer contains both epoxy resin and calcium hydroxide. Sealers containing calcium hydroxide will only be biologically active if

calcium and hydroxyl ions are released over time.^[23,24] The diffusion of hydroxyl ions from the root canal sealers increases the pH at the root surface, adjacent to the periodontal tissues, favoring repair.^[25] Sealers based on calcium hydroxide are used to enhance the healing process. Oliveira *et al.*^[22] determined that the addition of 5% calcium hydroxide to AH Plus sealer improved its biocompatibility in the subcutaneous connective tissue of rats. These results agree with those of the present study, in which only a mild to moderate inflammatory response to Obtuseal was elicited at 7 days, which was reduced on the following evaluation days. In this regard, the Obtuseal group's results are slightly better than the AH Plus group's. But these results are not statistically significant. There are no reports in the literature to support or refute the present findings on the tissue response to Obtuseal.

In this study, AH Plus result in a slightly more concentration of lymphocytes and macrophages in all the experimental periods. At 7 days, the AH Plus group exhibited macrophages in contact with the material, and the score was significantly higher than in the other periods. Based on this observation, it can be stated that AH Plus was more aggressive during the initial period of contact with connective tissue than Obtuseal. Batista *et al.*^[12] observed that AH Plus Sealer irritated tissues after a period of 7 days and that this aggression was reduced over time. In this study, tissues' reaction to the materials was evaluated after seven, 14 and 45 days.^[26] The results showed that both AH Plus and Obtuseal exhibited the most inflammatory reaction on the 7th day, but the response decreased and the numbers of macrophages and lymphocytes were reduced over time. In some studies, a material that allows for a reduction in inflammatory response over time, such as 14 days, can be considered a biocompatible material.^[10,27]

On the other hand, these sealers were used in solid form in this study. This form could provide information about the long-term effect of sealers. One recent study showed that freshly mixed and solid-form sealers had no significant effect on macrophages.^[8] However, our findings might change if the sealers implanted in subcutaneous tissue in the freshly mixed phase.

CONCLUSIONS

The tissues' reactions to both materials were similar. On the basis of the obtained results, it was concluded that Obtuseal root canal sealer caused a

satisfactory tissue reaction as AH plus because it was biocompatible when tested in the subcutaneous tissue of rats. Further studies are required to fully assess the biologic response to and cytotoxic effects of Obtuseal on periapical tissues in the long-term.

ACKNOWLEDGMENTS

This project was supported by Inonu University/Turkey, Scientific Research Projects Unit (2013/117).

REFERENCES

- Miletic I, Devcic N, Anic I, Borcic J, Karlovic Z, Osmak M. The cytotoxicity of RoekoSeal and AH plus compared during different setting periods. *J Endod* 2005;31:307-9.
- Ricucci D, Langeland K. Apical limit of root canal instrumentation and obturation, part 2. A histological study. *Int Endod J* 1998;31:394-409.
- Ricucci D. Apical limit of root canal instrumentation and obturation, part 1. Literature review. *Int Endod J* 1998;31:384-93.
- Kaplan AE, Ormaechea MF, Picca M, Canzobre MC, Ubios AM. Rheological properties and biocompatibility of endodontic sealers. *Int Endod J* 2003;36:527-32.
- Hauman CH, Love RM. Biocompatibility of dental materials used in contemporary endodontic therapy: A review. Part 2. Root-canal-filling materials. *Int Endod J* 2003;36:147-60.
- Wataha JC. Principles of biocompatibility for dental practitioners. *J Prosthet Dent* 2001;86:203-9.
- Giovanini AF, Leonardi DP, Baratto-Filho F, Vlença PC, Moresca RC, Moro A, *et al.* An endodontic sealer induces a pathological condition when associated with persistent tissue toxicity and presence of myofibroblasts. *Braz Dent J* 2011;22:369-76.
- de Oliveira Mendes ST, Ribeiro Sobrinho AP, de Carvalho AT, de Souza Côrtes MI, Vieira LQ. *In vitro* evaluation of the cytotoxicity of two root canal sealers on macrophage activity. *J Endod* 2003;29:95-9.
- Kettering JD, Torabinejad M. Cytotoxicity of root canal sealers: A study using HeLa cells and fibroblasts. *Int Endod J* 1984;17:60-6.
- Silveira CM, Pinto SC, Zedebski Rde A, Santos FA, Pilatti GL. Biocompatibility of four root canal sealers: A histopathological evaluation in rat subcutaneous connective tissue. *Braz Dent J* 2011;22:21-7.
- Economides N, Kotsaki-Kovatsi VP, Pouloupoulos A, Kolokuris I, Rozos G, Shore R. Experimental study of the biocompatibility of four root canal sealers and their influence on the zinc and calcium content of several tissues. *J Endod* 1995;21:122-7.
- Batista RF, Hidalgo MM, Hernandez L, Consolaro A, Velloso TR, Cuman RK, *et al.* Microscopic analysis of subcutaneous reactions to endodontic sealer implants in rats. *J Biomed Mater Res A* 2007;81:171-7.
- Scarpato RK, Grecca FS, Fachin EV. Analysis of tissue reactions to methacrylate resin-based, epoxy resin-based, and zinc oxide-eugenol endodontic sealers. *J Endod* 2009;35:229-32.
- Sousa CJ, Montes CR, Pascon EA, Loyola AM, Versiani MA. Comparison of the intraosseous biocompatibility of AH Plus, EndoREZ, and Epiphany root canal sealers. *J Endod* 2006;32:656-62.
- Azar NG, Heidari M, Bahrami ZS, Shokri F. *In vitro* cytotoxicity of a new epoxy resin root canal sealer. *J Endod* 2000;26:462-5.
- Mori GG, de Moraes IG, Nunes DC, Castilho LR, Poi WR, Capaldi ML. Biocompatibility evaluation of alendronate paste in rat's subcutaneous tissue. *Dent Traumatol* 2009;25:209-12.
- Huang FM, Tsai CH, Yang SF, Chang YC. Induction of interleukin-6 and interleukin-gene expression by root canal sealers in human osteoblastic cells. *J Endod* 2005;31:679-83.
- Farhad AR, Hashemina S, Razavi S, Feizi M. Histopathologic evaluation of subcutaneous tissue response to three endodontic sealers in rats. *J Oral Sci* 2011;53:15-21.
- Torneck CD. Reaction of rat connective tissue to polyethylene tube implants. I. *Oral Surg Oral Med Oral Pathol* 1966;21:379-87.
- Berbert FL, Leonardo MR, Silva LA, Tanomaru Filho M, Bramante CM. Influence of root canal dressings and sealers on repair of apical periodontitis after endodontic treatment. *Oral Surg Oral Med Oral Pathol Oral Radiol Endod* 2002;93:184-9.
- Huang FM, Tai KW, Chou MY, Chang YC. Cytotoxicity of resin-, zinc oxide-eugenol-, and calcium hydroxide-based root canal sealers on human periodontal ligament cells and permanent V79 cells. *Int Endod J* 2002;35:153-8.
- de Oliveira RL, Oliveira Filho RS, Gomes Hde C, de Franco MF, Enokihara MM, Duarte MA. Influence of calcium hydroxide addition to AH Plus sealer on its biocompatibility. *Oral Surg Oral Med Oral Pathol Oral Radiol Endod* 2010;109:e50-4.
- Estrela C, Sydney GB, Bammann LL, Felipe Júnior O. Mechanism of action of calcium and hydroxyl ions of calcium hydroxide on tissue and bacteria. *Braz Dent J* 1995;6:85-90.
- Tagger M, Tagger E, Kfir A. Release of calcium and hydroxyl ions from set endodontic sealers containing calcium hydroxide. *J Endod* 1988;14:588-91.
- Gomes-Filho JE, Bernabé PF, Nery MJ, Otoboni-Filho JA, Dezan-Júnior E, de Moraes Costa MM, *et al.* Reaction of rat connective tissue to a new calcium hydroxide-based sealer. *Oral Surg Oral Med Oral Pathol Oral Radiol Endod* 2008;106:e71-6.
- de Campos-Pinto MM, de Oliveira DA, Versiani MA, Silva-Sousa YT, de Sousa-Neto MD, da Cruz Perez DE. Assessment of the biocompatibility of Epiphany root canal sealer in rat subcutaneous tissues. *Oral Surg Oral Med Oral Pathol Oral Radiol Endod* 2008;105:e77-81.
- Hauman CH, Love RM. Biocompatibility of dental materials used in contemporary endodontic therapy: A review. Part 1. Intracanal drugs and substances. *Int Endod J* 2003;36:75-85.

Access this article online

Quick Response Code:



Website:

www.eurjdent.com

Source of Support: This project was supported by Inonu University/Turkey, Scientific Research Projects Unit (2013/117). **Conflict of Interest:** None declared