

Coronectomy of a lower third molar in combination with vital pulp therapy

Young-Bin Kim¹, Woo-Hee Joo², Kyung-San Min²

Correspondence: Dr. Kyung-San Min
Email: endomin@gmail.com

¹Department of Oral and Maxillofacial Surgery, Chonbuk National University, School of Dentistry, Jeonju, Korea,
²Department of Conservative Dentistry, Chonbuk National University, School of Dentistry, Jeonju, Korea

ABSTRACT

Coronectomy is a procedure that intentionally spares the vital root after removal of the crown of the lower third molar to avoid damage to the inferior alveolar nerve. Vital pulp therapy is one option for managing exposed pulp tissue to reduce the risk of pulpal inflammation or necrosis. Among various dental materials, mineral trioxide aggregate (MTA) has been successfully used for vital pulp therapy. Thus, this case report discusses a coronectomy procedure in combination with vital pulp therapy using MTA. This case also attempts to highlight the formation of tertiary dentin, evidence of successful vital pulp therapy.

Key words: Coronectomy, inferior alveolar nerve, mineral trioxide aggregate, tertiary dentin, vital pulp therapy

INTRODUCTION

The incidence of sensory loss after lower third molar (LTM) surgery ranges from 0.5% to 8.0% for the inferior alveolar nerve (IAN).^[1] Coronectomy is a surgical procedure designed to avoid manipulation of the IAN, by only removing the crown of an impacted third molar while leaving the root undisturbed.^[2] However, this technique did not gain universal acceptance because there was a perceived risk of late complication associated with the retained root.^[3]

Vital pulp therapy is one option for sealing the pulp space from the oral cavity to facilitate tertiary dentin formation.^[4] Although calcium hydroxide has been widely used for vital pulp therapy, mineral trioxide aggregate (MTA) appears to have more reliable effects than the other materials previously used.^[5-7] This case report describes the use of MTA for a coronectomy procedure. We also show the histological features of the extracted tooth to verify the formation of tertiary dentin.

CASE REPORT

A 28-year-old woman presented complaining of mild pain in her right lower molar area. About 3 years previous, she postponed extraction of the right LTM because of potential nerve injury to the IAN. Her clinical examination showed that the crown of the LTM was partially exposed, and there were signs of mild inflammation. A panoramic radiograph confirmed partial bony, horizontal impaction of the right LTM [Figure 1a]. Two roots were converging toward the root apex and were in contact with the inferior border of the nerve canal. According to the clinical and radiographic examination, the diagnosis of pericoronitis of the right mandibular third molar was made. The patient was informed of the risk of IAN injury and given the options of operculectomy, conventional surgical extraction, or coronectomy with pulpotomy using MTA. Coronectomy with pulpotomy was select, and informed consent was obtained for a possible secondary operation due to the possibility of retained root eruption.

How to cite this article: Kim Y, Joo W, Min K. Coronectomy of a lower third molar in combination with vital pulp therapy. *Eur J Dent* 2014;8:416-8.

Copyright © 2014 Dental Investigations Society.

DOI: 10.4103/1305-7456.137660

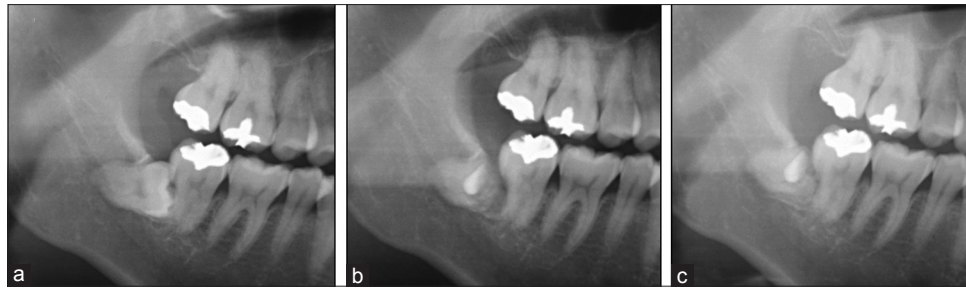


Figure 1: (a) Preoperative radiography. (b) Radiograph after coronectomy. (c) Radiograph 4 months after coronectomy

The surgical procedure was performed under local anesthesia with lidocaine HCl solution containing 1:100,000 epinephrine (Xylestesin-A, 3M ESPE, Seefeld, Germany). Crown cutting was performed along the cemento-enamel junction. Residual pulp tissue of the chamber was removed using a low-speed handpiece, and copious saline irrigation was performed. MTA (Endocem; Maruchi, Wonju, Korea) was then mixed according to the manufacturer's recommendation and was applied to the pulpal chamber with a Hollenback carver. After 4 min was allowed for setting, the surgical field was irrigated with copious saline, and the mucoperiosteal flaps were replaced. A postoperative panoramic radiograph showed sufficient space for the second molar and retained root [Figure 1b].

After 4 months, she revisited for follow-up. She was anxious about possible complications related to retained roots because of a planned pregnancy. For this reason, we decided to extract the roots although the patient did not have any discomfort at the coronectomy site. A panoramic radiograph was taken, which showed root migration in the anterior-superior direction with new bone formation under the roots [Figure 1c]. After routine flap elevation, the retained root portion was removed. There was no sign of IAN injury after extraction, and healing was uneventful.

Histological observation was scheduled to verify tertiary dentin formation beneath the MTA. Informed consent was obtained from the patient. The extracted roots were placed in 4% p-formaldehyde and subsequently decalcified using 18% ethylene diamine tetra acetic acid solution. The root portion was embedded in paraffin wax and serially sectioned. The specimens were then stained with hematoxylin and eosin for the evaluation of tertiary dentin formation beneath the MTA. Microscopic examination revealed the presence of tertiary dentin at the pulp-MTA interface [Figure 2].

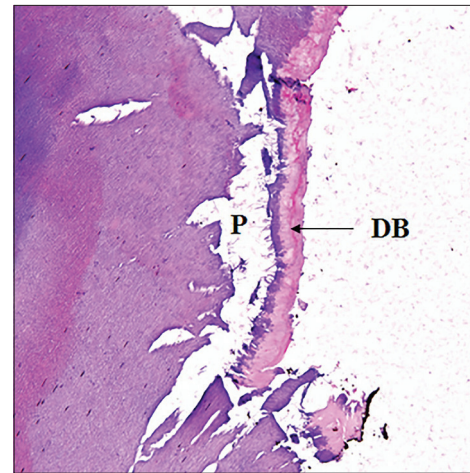


Figure 2: Histologic observation of the capped pulp stained with hematoxylin and eosin 4 weeks after treatment with mineral trioxide aggregate ($\times 100$). P: Pulp space; DB: Dentin bridge

DISCUSSION

Although the incidence of IAN injury after LTM extraction is reported to be 0.5-8%, it is one of the most important clinical and medico legal considerations.^[1] Coronectomy is a relatively simple procedure that decreases the risk of IAN injury and hence it can be a good alternative for patients concerned about IAN injury.^[8] However, vital pulp of the retained root after coronectomy may develop pulpitis and acute apical periodontitis, which can induce degeneration of the IAN.^[9] In this respect, treatment of the exposed pulp should be considered to minimize the risk of these complications.

The patient in this case preferred that the roots be extracted to eliminate the possibility of complications such as pulp necrosis or inflammation in the setting of a planned pregnancy. In this case, there was sufficient migration, so the retained root was successfully removed without IAN injury. A histological evaluation of the extracted tooth showed the formation of tertiary dentin beneath the cement. This finding suggests that the application of MTA to manage the exposed pulp may be successful.

CONCLUSION

This case indicates that coronectomy in combination with MTA can be a safe and effective method. Furthermore, in some situations, delayed extraction can be performed safely after sufficient root migration.

ACKNOWLEDGMENT

This research was supported by Basic Science Research Program through the National Research Foundation of Korea (NRF) funded by the Ministry of Education, Science and Technology (2013-R1A1A4A01006389).

REFERENCES

1. Sisk AL, Hammer WB, Shelton DW, Joy ED Jr. Complications following removal of impacted third molars: The role of the experience of the surgeon. *J Oral Maxillofac Surg* 1986;44:855-9.
2. Ghaeminia H. Coronectomy may be a way of managing impacted third molars. *Evid Based Dent* 2013;14:57-8.
3. Patel V, Sproat C, Kwok J, Beneng K, Thavaraj S, McGurk M. Histological evaluation of mandibular third molar roots retrieved after coronectomy. *Br J Oral Maxillofac Surg* 2014;52:415-9.
4. Min KS, Yang SH, Kim EC. The combined effect of mineral trioxide aggregate and enamel matrix derivative on odontoblastic differentiation in human dental pulp cells. *J Endod* 2009;35:847-51.
5. Min KS, Park HJ, Lee SK, Park SH, Hong CU, Kim HW, *et al.* Effect of mineral trioxide aggregate on dentin bridge formation and expression of dentin sialoprotein and heme oxygenase-1 in human dental pulp. *J Endod* 2008;34:666-70.
6. Dominguez MS, Witherspoon DE, Gutmann JL, Opperman LA. Histological and scanning electron microscopy assessment of various vital pulp-therapy materials. *J Endod* 2003;29:324-33.
7. Faraco IM Jr, Holland R. Response of the pulp of dogs to capping with mineral trioxide aggregate or a calcium hydroxide cement. *Dent Traumatol* 2001;17:163-6.
8. Leung YY, Cheung LK. Safety of coronectomy versus excision of wisdom teeth: A randomized controlled trial. *Oral Surg Oral Med Oral Pathol Oral Radiol Endod* 2009;108:821-7.
9. Renton T, Hankins M, Sproate C, McGurk M. A randomised controlled clinical trial to compare the incidence of injury to the inferior alveolar nerve as a result of coronectomy and removal of mandibular third molars. *Br J Oral Maxillofac Surg* 2005;43:7-12.

| Access this article online | |
|---|---|
| Quick Response Code:  | Website: www.eurjdent.com |
| Source of Support: This research was supported by Basic Science Research Program through the National Research Foundation of Korea (NRF) funded by the Ministry of Education, Science and Technology (2013-R1A1A4A01006389). | |
| Conflict of Interest: None declared | |