

# Immediate esthetic crown with a facet of the extracted element

Giovanni de Almeida Prado Di Giacomo<sup>1,2</sup>, Amanda Magalhães<sup>3</sup>, Sergio Ajzen<sup>1</sup>

<sup>1</sup>Department of Diagnostic Imaging, School of Medicine, Federal University of São Paulo, São Paulo, Brazil,

<sup>2</sup>Department of 3D Technologies, Center of Information Technology Renato Acher, Campinas, Brazil,

<sup>3</sup>Department of Dental Prosthesis, Camilo Castelo Branco University, São Paulo, Brazil

**Correspondence:** Dr. Giovanni de Almeida Prado Di Giacomo  
Email: giovannidi@uol.com.br

## ABSTRACT

The present report describes a case of implant loading with an immediate temporary crown. The buccal crown surface was removed from the extracted tooth to obtain an aesthetically satisfactory result. After periodontal treatment, tooth 21 appeared proclined and showed Grade 3 mobility, indicating the need for its extraction. The remaining bone was imaged using computed tomography, and virtual surgical planning was performed using these results. The implant was immediately loaded postextraction into the fresh alveolus without a graft and flap procedure. The temporary tooth, which was manufactured using the extracted buccal surface, was a simple, fast, and low cost procedure that produced an excellent esthetic outcome.

**Key words:** Dental implants, immediate loading, temporary crown

## INTRODUCTION

The treatment duration and esthetic outcome are fundamental factors for patients considering dental implantation.<sup>[1]</sup> Thus, the immediate loading technique, which allows dental graft masticatory function soon after the surgical procedure, is preferred because it avoids the need to wait for complete osteointegration.

This procedure is both safe and comfortable for patients, who can depend on receiving a fixed prosthetic piece shortly after surgery. This is especially appreciated by patients who were previously using a removable prosthetic piece. Immediate implant loading after tooth extraction not only reduces the number of surgical sessions, but also achieves rapid soft tissue remodeling around the implant. Some studies report that placing temporary prostheses maintains the tissue in dimensions identical to those of the extracted tooth.<sup>[2]</sup>

Immediate loading is a treatment option only under certain conditions. One of the major prerequisites for treatment success is high primary stability of the implant, which requires a high insertion torque of the implant<sup>[3]</sup> between 35 and 45 Ncm. This torque can be reliably generated by choosing patients with sufficient bone quality and quantity, adequately sized implants and surfaces, and using a minimally traumatic surgical technique.<sup>[2,3]</sup> However, successful immediate loading may be jeopardized by masticatory overloading and infection.<sup>[3]</sup>

The prosthesis must have good marginal adaptation and passivity.<sup>[4]</sup> Periodontal evaluation before extraction is of fundamental importance and should include the following clinical details: The smile type (low, medium, and high), periodontal biotype (fine, medium, and thick), presence of interproximal negro triangles, any asymmetric gingival contour, any periodontal bags, malpositioned teeth, average line deviation, relative positions of

**How to cite this article:** Di Giacomo GA, Magalhães A, Ajzen S. Immediate esthetic crown with a facet of the extracted element. *Eur J Dent* 2014;8:412-5.

Copyright © 2014 Dental Investigations Society.

DOI: 10.4103/1305-7456.137658

the anterior-superior teeth to the lower lip, and the aesthetic goals.<sup>[5]</sup>

Gingival conditioning is considered one of the most satisfying and simple clinical procedures optimizing the aesthetic outcome. It is performed using techniques including gradual pressure and scarification. Regardless of the procedure, the temporary prostheses are critical to the success of gingival conditioning.<sup>[5]</sup>

Surgical and prosthetic planning is important in ensuring successful dental rehabilitation in implantodontology.<sup>[6]</sup> By using surgical planning software and computed tomography data, a three-dimensional surgical simulation can be created, which provides a detailed study of the surgical site.<sup>[6,7]</sup>

The present report describes a clinical case of immediate implant loading using the natural crown of the extracted central incisor to obtain an excellent aesthetic result.

## CASE REPORT

A 50-year-old male patient had a low smile line, dental misalignment, and dental occlusion on initial presentation. Clinical and radiographic exams revealed buccal bone loss and a Grade 3 mobility at tooth 21, indicating the need for its extraction [Figure 1]. In addition, the prosthetic space was lost at the site; therefore, minimal orthodontic movement of the neighboring teeth was indicated.

The stabilization, surgical, and prosthesis were virtually planned.<sup>[8,9]</sup> Based on the simulation, the implant dimensions (13 mm length and 55 mm diameter) and positioning were determined [Figures 2 and 3]. To minimize orthodontic movement, the mesial surfaces of teeth 11 and 22 and the proximal crown of the tooth to be extracted were slightly worn down.

During the extraction, care was taken to maintain the alveolus and soft tissue integrity without creating a gingival flap. Later, the implant was loaded at a 45 Ncm torque, and the temporary abutment, which was covered with an opaque resin [Figure 4], was screwed onto the implant.

The buccal crown surface of the extracted tooth was secured onto the implant with a small amount of nonpolymerized composite resin. Once the crown

was correctly positioned on the dental arch, the resin was polymerized. The assembly (surface and temporary abutment) was removed [Figure 5], and a photopolymerizable resin was filled into the space between the surface and metallic cylinder to establish

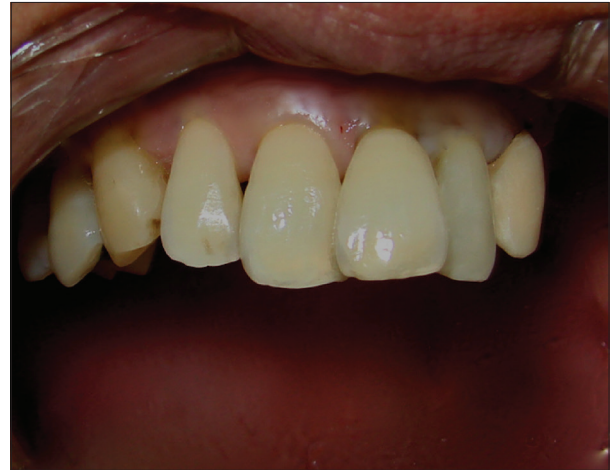

Figure 1: The patient immediately after periodontal treatment

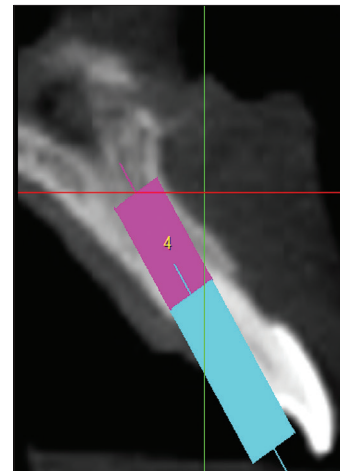


Figure 2: Virtual surgical and prosthetic planning

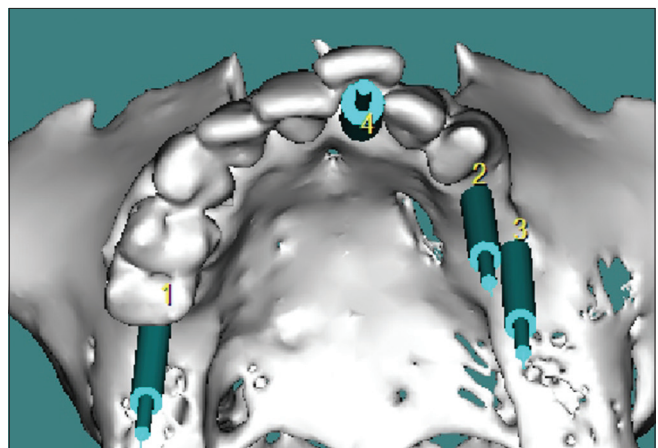

Figure 3: Virtual surgical and prosthetic planning

a temporary profile [Figure 6]. Initially, a small cervical diameter profile was used, which was later resized after the initial tissue cicatrization. The crown profile was finished and polished, and the crown was placed [Figure 7].

## DISCUSSION

The decision to perform immediate or delayed implantation following extraction is controversial. A previous systematic review reports that both immediate and delayed implantation techniques show similar clinical outcomes.<sup>[10]</sup> Others<sup>[11]</sup> assert that immediate implantation better preserves the soft tissue and bone architecture, prevents postextraction collapse, limits bone reabsorption, and consequently, minimizes the inherent esthetic losses.

In the present case, the surgical and prosthetic plan was designed in advance using surgical planning software, which allowed visualization

of the available bone and simulated the implant position. These diagnostic findings favored implant loading immediately after extraction. The lack of instrumentation at the surgical bed<sup>[1,8,9]</sup> was crucial for achieving the high insertion torque necessary for primary implant stability.

Placing a temporary crown over the implant not only enhanced the aesthetic and functional outcomes, but also enabled monitoring of the tissue architecture to ensure a well-fitted cervical design in the final prosthesis. Using the buccal crown surface of the extracted tooth was a simple procedure with excellent esthetic results. Although this therapeutic strategy did not resolve the preexisting defect in the cervical gingival contour, the clinical result met the expectations of both the clinician and patient.

## CONCLUSION

Manufacturing a temporary tooth using the natural surface of the extracted tooth was a simple, fast,



Figure 4: Abutment with opaque resin




Figure 5: Buccal crown surface secured onto the temporary cylinder



Figure 6: Temporary crown

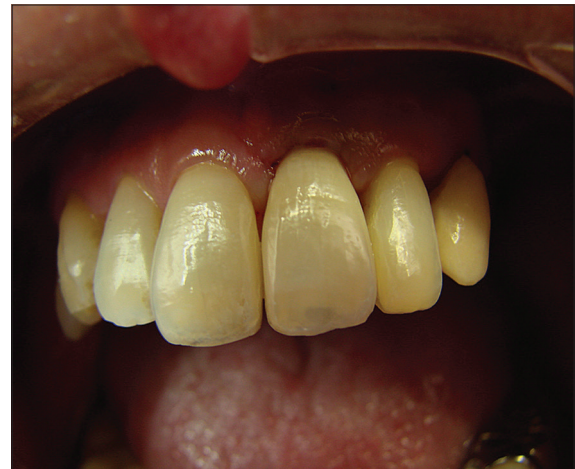

Figure 7: Loaded temporary crown

and low cost procedure that produced an excellent esthetic result.

## REFERENCES

1. Peredo-Paz LG, Francischone CA, Ferreira E, Sidney R. Immediate loading on unitary prostheses after exodonty in esthetics. *Rev Dent Press Periodontia Implantol* 2008;2:92-109.
2. Schioli G. Immediate tooth extraction, placement of a Tapered Screw-Vent implant, and provisionalization in the esthetic zone: A case report. *Implant Dent* 2003;12:123-31.
3. Esposito M, Grusovin MG, Willings M, Coulthard P, Worthington HV. The effectiveness of immediate, early, and conventional loading of dental implants: A Cochrane systematic review of randomized controlled clinical trials. *Int J Oral Maxillofac Implants* 2007;22:893-904.
4. Schropp L, Kostopoulos L, Wenzel A. Bone healing following immediate versus delayed placement of titanium implants into extraction sockets: A prospective clinical study. *Int J Oral Maxillofac Implants* 2003;18:189-99.
5. Maynard JG Jr, Wilson RD. Physiologic dimensions of the periodontium significant to the restorative dentist. *J Periodontol* 1979;50:170-4.
6. Jacobs R, Adriansens A, Naert I, Quirynen M, Hermans R, Van Steenberghe D. Predictability of reformatted computed tomography for pre-operative planning of endosseous implants. *Dentomaxillofac Radiol* 1999;28:37-41.
7. Di Giacomo GA, Cury PR, de Araujo NS, Sendyk WR, Sendyk CL. Clinical application of stereolithographic surgical guides for implant placement: Preliminary results. *J Periodontol* 2005;76:503-7.
8. Giacomo GD, Silva J, Martines R, Ajzen S. Computer-designed selective laser sintering surgical guide and immediate loading. *Eur J Dent* 2014;8:100-6.
9. Di Giacomo GA, da Silva JV, da Silva AM, Paschoal GH, Cury PR, Szarf G. Accuracy and complications of computer-designed selective laser sintering surgical guides for flapless dental implant placement and immediate definitive prosthesis installation. *J Periodontol* 2012;83:410-9.
10. Ortega-Martínez J, Pérez-Pascual T, Mareque-Bueno S, Hernández-Alfaro F, Ferrés-Padró E. Immediate implants following tooth extraction. A systematic review. *Med Oral Patol Oral Cir Bucal* 2012;17:e251-61.
11. Pelegrine AA, Costa CE, Sendyk WR. Enxerto de tecido conjuntivo, uma alternativa para alcançar a estética perimplantar. *Relato de caso clínico. Implant News* 2006;3:250-4.

Access this article online	
<b>Quick Response Code:</b> 	<b>Website:</b> <a href="http://www.eurjdent.com">www.eurjdent.com</a>
<b>Source of Support:</b> Nil. <b>Conflict of Interest:</b> None declared	