

# Three-dimensional evaluation of the mandibular third molars' development in unilateral crossbite patients: A cone beam computed tomography study

Koray Halicioglu<sup>1</sup>, Mevlut Celikoglu<sup>2</sup>, Suleyman Kutalmis Buyuk<sup>3</sup>, Ahmet Ercan Sekerci<sup>4</sup>, Faruk Izzet Ucar<sup>5</sup>, Ibrahim Yavuz<sup>3</sup>

<sup>1</sup>Department of Orthodontics, Faculty of Dentistry, Abant Izzet Baysal University, Bolu, Turkiye,

<sup>2</sup>Department of Orthodontics, Faculty of Dentistry, Akdeniz University, Antalya, Turkiye,

<sup>3</sup>Department of Orthodontics, Faculty of Dentistry, Erciyes University, Kayseri, Turkiye,

<sup>4</sup>Department of Oral and Maxillofacial Radiology, Faculty of Dentistry, Erciyes University, Kayseri, Turkiye,

<sup>5</sup>Department of Orthodontics, Faculty of Dentistry, Selcuk University, Konya, Turkiye

**Correspondence:** Dr. Mevlut Celikoglu  
Email: mevlutcelikoglu@hotmail.com

## ABSTRACT

**Objectives:** The aim was to investigate mandibular third molar (3M)'s maturation in the crossbite and normal sides by two- and three-dimensional analyses using cone beam computed tomography (CBCT). **Materials and Methods:** A retrospective study was performed using CBCT of 25 patients (16 females and 9 males; mean age:  $16.8 \pm 2.9$  years) with unilateral posterior crossbite. The formation stages and the volume of the mandibular 3Ms were evaluated by means of CBCT data of the patients without knowing the crossbite side of the patients. **Results:** Statistically no significant differences were found in the development of the 3Ms between the crossbite and the control sides, whereas the volume of 3M was found to be less in the crossbite side than in the normal side ( $P = 0.021$ ). **Conclusions:** A volume of 3M was found to be less in the crossbite side than in the normal side.

**Key words:** Dental growth, dental maturation, third molar development, unilateral crossbite

## INTRODUCTION

Radiography is generally used in determining dental maturation and two-dimensional panoramic radiographs are mainly used in radiography as seen in the dental and forensic literature. However, different dental age estimation methods have been used to measure tooth development, which include diagrams,<sup>[1]</sup> charts,<sup>[2]</sup> and definition of the formative stages<sup>[2,3]</sup> at present. Cone beam computed tomography (CBCT) allows obtaining three-dimensional images of the tooth. Yang *et al.*<sup>[4]</sup> mentioned that the clinical use of CBCT has shown

new techniques for acquiring three-dimensional dental radiographs, resulting in good image quality with low radiation dose. In addition, CBCTs provide an opportunity to analyze volumetric measurements of teeth. Cameriere *et al.*<sup>[5]</sup> emphasized that volumetric study with CBCT would be the best method for dental age estimation. Yang *et al.*<sup>[4]</sup> first describe an approach to dental age estimation by CBCT using the ratio of pulp/tooth volume that could be calculated for living individuals. Maret *et al.*<sup>[6]</sup> indicated that to improve age estimation goal, including the volume of dental tissues and their ratio, "further investigation should aim: To acquire

**How to cite this article:** Halicioglu K, Celikoglu M, Buyuk SK, Sekerci AE, Ucar FI, Yavuz I. Three-dimensional evaluation of the mandibular third molars' development in unilateral crossbite patients: A cone beam computed tomography study. *Eur J Dent* 2014;8:389-94.

Copyright © 2014 Dental Investigations Society.

DOI: 10.4103/1305-7456.137653

larger sample sizes in order to reduce standard errors of age estimation, study the effect of several factors on model parameters, and investigate the use of all types of teeth together". Limited number of studies is available on the issue of ratio of pulp/tooth volume. Dental age estimation is usually done on the mandibular incisor,<sup>[7]</sup> canine,<sup>[8]</sup> or premolar<sup>[9]</sup> that is, always the monoradicular teeth<sup>[4,10]</sup> in the afore-mentioned studies. Nevertheless, no study has investigated the use of tooth germ volume for dental age estimation in multiradicular teeth.

In addition to this, it is a well-known fact that dental development is a multi-factorial phenomenon.<sup>[11]</sup> Garn *et al.*<sup>[12]</sup> in their study have reported in 1965 that they thought genes, harmonies, and even calories have an important role in tooth development. However, environmental factors are now better known to have a very important role in the dental development.<sup>[2]</sup> Orthodontic malocclusion is one of the most prominent of environmental factors. Orthodontic malocclusions on the sagittal,<sup>[13]</sup> vertical<sup>[14]</sup> and even horizontal<sup>[15]</sup> dimensions have been reported to have an effect on dental development.

Posterior crossbite is characterized as any abnormal buccopalatal relationship between mandibular and maxillary molars, premolars, or both in centric occlusion.<sup>[16]</sup> Unilateral crossbite is associated with asymmetric muscular function and asymmetric bite force.<sup>[17]</sup> Uysal *et al.*<sup>[15]</sup> indicated that the crossbite patient presented with a tendency to delayed dental maturation. Nevertheless, mandibular third molars (3Ms) were not included in their study. In addition to this, there is no study investigating the development of 3Ms in the crossbite and normal sides. In light of this fact, the aim of this study was to investigate mandibular 3Ms maturation and volume in the crossbite side and to compare them with the 3Ms in the normal sides by two-dimensional and three-dimensional analyses using CBCT data.

## MATERIALS AND METHODS

A retrospective study was performed using CBCT data of 25 patients (16 females and 9 males; aged 15-23 years), selected randomly from the archive of Faculty of Dentistry in Erciyes University. CBCT scans of these patients were previously obtained as a part of the diagnostic records for orthognathic surgery, temporomandibular dysfunction, and impacted canine; and for this reason they were not subjected to additional radiation. Ethics committee

approval was not required due to the archival nature of the research. However, as a usual protocol, all the patients (or parents) signed an informed consent agreeing to the use of the patients' data (age, gender, medical history, etc.) for scientific studies.

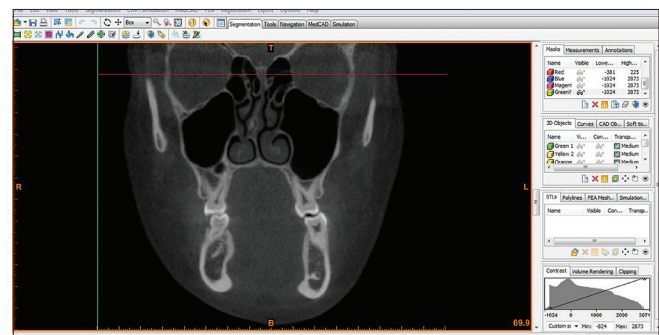
All images were obtained in the supine position by using CBCT (NewTom 5G, QR Verona, Italy). The scanning time was 18 s, collimation height 13 cm, exposure time 3.6 s, and voxel size 0.3 mm<sup>3</sup>. Patients in the study group met the following inclusion criteria:

- No history of trauma, developmental and acquired craniofacial disorders or maxillofacial surgery prior to orthodontic treatment.
- No missing tooth (excluding maxillary 3Ms) and no systemic disease.
- Skeletal Class I (determined by ANB; 0-4°) and normodivergent facial pattern (determined by SN-GoGn angle; 32° ± 5°).
- Unilateral crossbite of at least two teeth determined by plaster models (11 patients had all teeth in crossbite, 8 patients had three teeth in crossbite and 6 patients had two teeth in crossbite).

All records were examined in axial slices, and patients who had two or more unilateral posterior crossbite teeth were determined using the same device (NewTom 5G, QR Verona, Italy) [Figure 1]. Primary reconstructions of the data were performed with the Mimics software (Materialise HQ, Leuven, Belgium). Second, the exported digital imaging and communication in medicine (DICOM) files were viewed, and segmentations of the mandibular 3Ms were carried out using software. Observations were made regarding the patient's sex, chronological age, ANB, and SN-GoGn angles.

## Evaluation of dental maturation and dental volume

Panoramic radiograms were obtained by the Mimics software (Materialise HQ, Leuven, Belgium), and dental



**Figure 1:** Unilateral crossbite shown in a cone beam computed tomography image

development of the 3Ms was evaluated according to the method of Demirjian *et al.*<sup>[2]</sup> The formation stages of the tooth germs were evaluated based on the formative condition of the crowns and roots of the mandibular 3Ms. This method divides the formation of the crowns and roots of permanent teeth into eight stages. The formation stages are shown in Figure 2. The formation stage of the mandibular 3M on the side of the crossbite was evaluated. The formative condition of the 3M on the other side of the same jaw was used as the control [Figure 3]. DICOM files were imported in a CBCT diagnostic and treatment planning software allowing for tooth volume calculations. The program automatically calculated the volume of the obtained three-dimensional images of the tooth [Figure 4].

All measurements were carried out by a dentomaxillofacial radiologist without knowing the crossbite side and thus a blinding was performed.

### Statistical evaluation

To test the reproducibility of the assessments of dental developmental stages and volume of mandibular 3Ms, the same investigator re-evaluated 15 randomly selected CBCTs 2 weeks after the first evaluation. Intra-class correlation coefficients were performed to assess the reliability of volumetric measurements as described by Houston.<sup>[18]</sup> The coefficients of reliability according to the Houston method<sup>[18]</sup> for volumetric measurements were 0.92 (mandibular right molar volume) and 0.98 (mandibular left molar volume), confirming measurement reliability. Kappa coefficients were used to evaluate agreement between the first and second dental maturity assessments and Kappa values were found to be above 0.90.

The normality test of Kolmogorov-Smirnov was applied to the data, and all data were found normally distributed. Thus, the statistical evaluations of these data were performed using parametric tests. Student's *t*-test was used to assess gender differences in the patient's chronological age, ANB, and SN-GoGn angles. A paired *t*-test was used to compare the differences in the developmental stages and volume of the 3Ms between the crossbite and control sides. Since no gender difference was present for mandibular 3Ms' development stages and volume, the data from both sexes were pooled. A linear regression analysis was performed to evaluate the effect of the number of teeth in crossbite. All data were analyzed with SPSS for Windows (version 15.0, SPSS, Chicago, Illinois).  $P < 0.05$  was considered to be statistically significant.

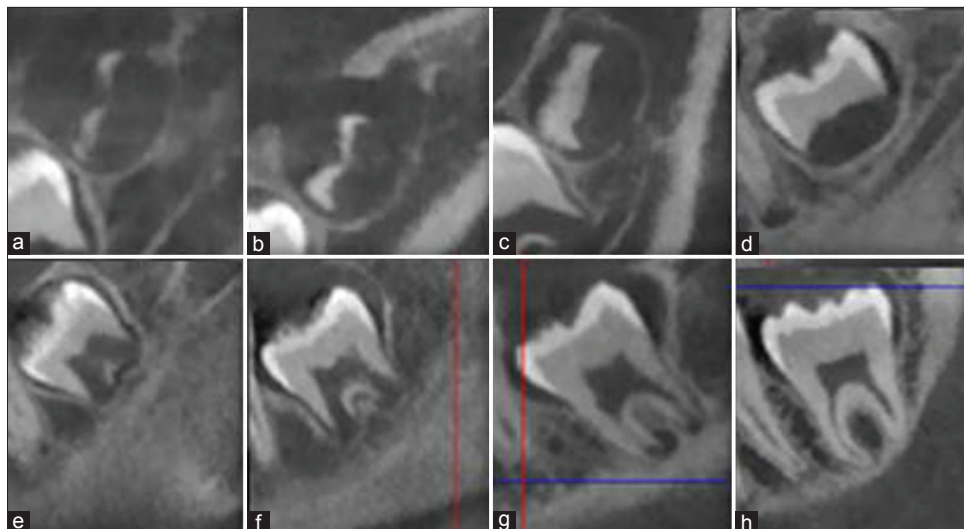
## RESULTS

Demographic features of the patients included to the study are shown in Table 1. Student's *t*-test showed no significant sex differences for skeletal facial patterns and chronological ages and thus both genders presented similar characteristic features.

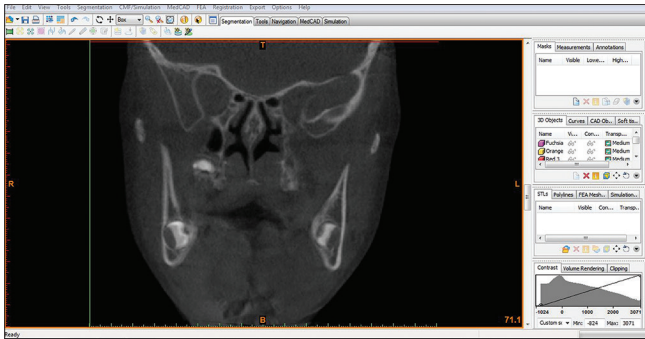
**Table 1: Demographic features of the subjects included to the study**

Study samples	<i>n</i>	ANB (°)*	SN-GoGn (°)*	CA (years)*
Females	16	2.8±1.2	34.1±5.1	16.2±1.9
Males	9	3.2±1.4	33.4±3.6	18.1±4.2
Total	25	3.0±1.2	33.8±4.6	16.8±2.9

\*No significant difference tested by Student's *t*-test. *n*: Number, CA: Chronological age



**Figure 2:** The eight stages of tooth development according to Demirjian method



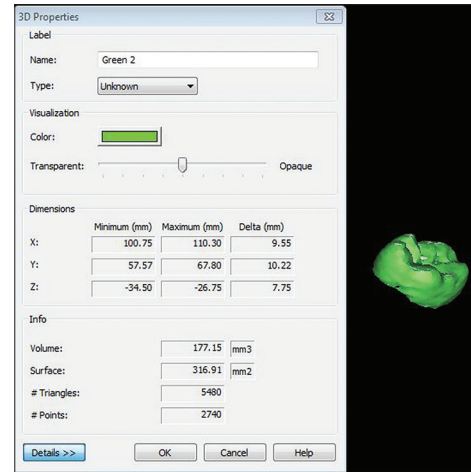
**Figure 3:** The formative condition of the third molar on the other side of the same jaw was used as the control

Third molars' development stages and volume in relation to crossbite presence are shown in Table 2. Paired *t*-test showed that no statistically significant differences were found in the development of the mandibular 3Ms between the crossbite and control sides ( $P = 0.714$ ). In addition, when we evaluated patients one by one, we detected differences in seven patients according to the developmental stages of the 3Ms. On the other hand, 18 of 25 patients' development of the 3Ms were the same. Although three patients had one developmental stage delay of the mandibular 3M in the crossbite side, the other four patients had one developmental stage accelerated.

Because Student's *t*-test showed no significant sex differences for the volume parameters of the 3Ms, the data for both genders were pooled. In contrast to developmental stage similarities, paired *t*-test showed statistically significant differences for the volume of the mandibular 3Ms between the crossbite and control sides ( $P = 0.021$ ). The volume of mandibular 3M in the crossbite side was less than the volume of 3M in the control side ( $529.81 \pm 199.01 \text{ mm}^3$  and  $578.52 \pm 217.43 \text{ mm}^3$ , respectively). Results of the regression analysis showed that the number of the teeth in crossbite had no affect on the volume of the mandibular 3Ms ( $R^2 = 0.004$ ;  $P = 0.714$ ).

## DISCUSSION

Dental age determination is important in both medical jurisprudence and clinical dentistry.<sup>[19]</sup> The most common method by which dental age assessment is done is the method of Demirjian *et al.*<sup>[2]</sup> This classification method distinguishes the first four stages of crown development (A-D) and the last four stages of root development (E-G) so it is easy to use. Dhanjal *et al.*<sup>[20]</sup> have reported that this method performed intra- and inter-examination best for radiographic stage assessment of 3Ms. Therefore, this method was used in this study.



**Figure 4:** Volumetric measurement of third molar on the cone beam computed tomography images

**Table 2: Third molar development stage in relation to cross bite presence**

Parameters	Crossbite side	Normal side	P*
Root development stage	5.54±1.64	5.50±1.67	0.714
3M volume (mm <sup>3</sup> )	529.81±199.01	578.52±217.43	0.021

\*The result of paired *t*-test, 3M: Third molar

Dental development is a multi-factorial phenomenon. Malocclusions in the sagittal, vertical, and horizontal dimensions<sup>[13-15]</sup> were previously shown to affect dental development. Therefore, patients who were included in this study were compatible with the horizontal and vertical dimensions as shown in Table 1. Lately, it was shown that children with hypodontia showed a significant delay in dental development when compared with case controls.<sup>[21]</sup> To eliminate those factors, patients with hypodontia were not included to this study. Since above factors affecting dental development was eliminated, the effects of unilateral crossbite might be better understood.

Panoramic radiographs are noninvasive methods that are used in the formative condition of the teeth.<sup>[13,22,23]</sup> Dental maturation has been successfully determined from two-dimensional panoramic radiographs. However, these radiographic images were made from accumulated two-dimensional images of the horizontal or parallel aspects of the tooth<sup>[6]</sup> and therefore, would be difficult to accurately evaluate the development of the teeth, especially 3Ms that have generally different eruption and formation anomalies. Furthermore, the entire three-dimensional morphological assessment of 3Ms is not possible with panoramic radiographs. However, the clinical use of CBCT has created new opportunities for obtaining three-dimensional tooth radiographs, resulting in reasonable fair image quality at a low radiation dose.<sup>[4]</sup>

In a recent paper, Ahlowalia *et al.*<sup>[24]</sup> in their study have reported that CBCT was an accurate means of measuring the volume of artificially created bone cavities. Therefore, we used CBCT images to assess maturations and volume of 3Ms.

It was stated that deviation of tooth maturation on the two sides of the same jaw is frequent and few months of tooth maturation difference can be observed.<sup>[25]</sup> In this study, no statistically significant difference for the mandibular 3M developmental stage between the crossbite and the normal sides was present. We detected differences only in seven patients in relation to the developmental stages of the 3Ms. Although there was no difference in dental maturation as assessed by two-dimensional analyses method, there were statistically significant volume differences between the crossbite and control sides ( $P = 0.021$ ). It was found that mean volume ( $529.81 \pm 199.01 \text{ mm}^3$ ) of mandibular 3Ms in the crossbite side was less than the mean volume ( $578.52 \pm 217.43 \text{ mm}^3$ ) of mandibular 3Ms in the normal side. This result suggests that the presence of mandibular 3Ms has a different growth potential even if a similar development stage was observed in two-dimensional radiographs. This difference might be due to the difference in crown volume in the erupted teeth. This finding adds new information to the literature. However, we did not differ crown and root volume due to the difficulties in performing this. Furthermore, we investigated the effects of tooth number in the crossbite on volume difference and no effect was found according to the results of the linear regression analysis ( $R^2 = 0.004$ ;  $P = 0.714$ ).

The strength of this study is that it is the first study using CBCT for the evaluation of mandibular 3M maturation in unilateral crossbite patients. However, limitation of this study might be the number of the patients (25 patients) included to the study. CBCT data from the archives were used in the present study because it is not ethically acceptable to expose patients to radiation. According to the findings of Celikoglu *et al.*,<sup>[13]</sup> dental age of patients with sagittal skeletal malocclusions was approximately twice more advanced when compared with patients without sagittal skeletal anomaly patterns. A recently published study<sup>[26]</sup> have shown that the dental age has been estimated to be more advanced than chronological age in all skeletal malocclusions and dental maturation advanced in cases with a tendency to develop Class II malocclusions. Therefore, the inclusion criteria such as no hypodontia, no sagittal

and vertical skeletal anomaly reduced the study sample of the present study. Future studies including larger study samples and performed on CBCT archive could be welcome to discuss and confirm our findings.

## CONCLUSION

As a result, although two-dimensional data showed that no statistically significant difference was present for the development of mandibular 3Ms in the normal and crossbite sides, the volume of 3M that was calculated by means of CBCT was found to be less in the crossbite side than in the normal side.

## REFERENCES

- Schour I, Massler M. The development of the human dentition. *J Am Dent Assoc* 1941;28:1153-60.
- Demirjian A, Goldstein H, Tanner JM. A new system of dental age assessment. *Hum Biol* 1973;45:211-27.
- Moorrees CF, Fanning EA, Hunt EE Jr. Age variation of formation stages for ten permanent teeth. *J Dent Res* 1963;42:1490-502.
- Yang F, Jacobs R, Willems G. Dental age estimation through volume matching of teeth imaged by cone-beam CT. *Forensic Sci Int* 2006;159 Suppl 1:578-83.
- Cameriere R, Ferrante L, Belcastro MG, Bonfiglioli B, Rastelli E, Cingolani M. Age estimation by pulp/tooth ratio in canines by mesial and vestibular peri-apical X-rays. *J Forensic Sci* 2007;52:1151-5.
- Maret D, Peters OA, Dedouit F, Telmon N, Sixou M. Cone-Beam Computed Tomography: A useful tool for dental age estimation? *Med Hypotheses* 2011;76:700-2.
- Someda H, Saka H, Matsunaga S, Ide Y, Nakahara K, Hirata S, *et al.* Age estimation based on three-dimensional measurement of mandibular central incisors in Japanese. *Forensic Sci Int* 2009;185:110-4.
- Tardivo D, Sastre J, Ruquet M, Thollon L, Adalian P, Leonetti G, *et al.* Three-dimensional modeling of the various volumes of canines to determine age and sex: A preliminary study. *J Forensic Sci* 2011;56:766-70.
- Aboshi H, Takahashi T, Komuro T. Age estimation using microfocus X-ray computed tomography of lower premolars. *Forensic Sci Int* 2010;200:35-40.
- Star H, Thevissen P, Jacobs R, Fieuws S, Solheim T, Willems G. Human dental age estimation by calculation of pulp-tooth volume ratios yielded on clinically acquired cone beam computed tomography images of monoradicular teeth. *J Forensic Sci* 2011;56 Suppl 1:577-82.
- Halicioglu K. Dental age in patients with impacted maxillary canines related to the position of the impacted teeth. *Eur J Orthod* 2012;34:394.
- Garn SM, Lewis AB, Kerewsky RS. Genetic, nutritional, and maturational correlates of dental development. *J Dent Res* 1965;44 Suppl: 228-42.
- Celikoglu M, Erdem A, Dane A, Demirci T. Dental age assessment in orthodontic patients with and without skeletal malocclusions. *Orthod Craniofac Res* 2011;14:58-62.
- Janson GR, Martins DR, Tavano O, Dainesi EA. Dental maturation in subjects with extreme vertical facial types. *Eur J Orthod* 1998;20:73-8.
- Uysal T, Yagci A, Ramoglu SI. Dental maturation in patients with unilateral posterior crossbite. *World J Orthod* 2009;10:383-8.
- Kennedy DB, Osepchook M. Unilateral posterior crossbite with mandibular shift: A review. *J Can Dent Assoc* 2005;71:569-73.
- Sonnesen L, Bakke M. Bite force in children with unilateral crossbite before and after orthodontic treatment. A prospective longitudinal study. *Eur J Orthod* 2007;29:310-3.
- Houston WJ. The analysis of errors in orthodontic measurements. *Am J Orthod* 1983;83:382-90.
- Miloglu O, Celikoglu M, Dane A, Cantekin K, Yilmaz AB. Is the assessment of dental age by the Nolla method valid for eastern Turkish children? *J Forensic Sci* 2011;56:1025-8.

20. Dhanjal KS, Bhardwaj MK, Liversidge HM. Reproducibility of radiographic stage assessment of third molars. *Forensic Sci Int* 2006;159 Suppl 1:S74-7.
21. Ruiz-Mealin EV, Parekh S, Jones SP, Moles DR, Gill DS. Radiographic study of delayed tooth development in patients with dental agenesis. *Am J Orthod Dentofacial Orthop* 2012;141:307-14.
22. Nur B, Kusgoz A, Bayram M, Celikoglu M, Nur M, Kayipmaz S, *et al.* Validity of demirjian and nolla methods for dental age estimation for Northeastern Turkish children aged 5-16 years old. *Med Oral Patol Oral Cir Bucal* 2012;17:e871-7.
23. Cantekin K, Yilmaz Y, Demirci T, Celikoglu M. Morphologic analysis of third-molar mineralization for eastern Turkish children and youth. *J Forensic Sci* 2012;57:531-4.
24. Ahlowalia MS, Patel S, Anwar HM, Cama G, Austin RS, Wilson R, *et al.* Accuracy of CBCT for volumetric measurement of simulated periapical lesions. *Int Endod J* 2013;46:538-46.
25. Celikoglu M, Cantekin K, Ceylan I. Dental age assessment: The applicability of Demirjian method in eastern Turkish children. *J Forensic Sci* 2011;56 Suppl 1:S220-2.
26. Esenlik E, Atak A, Altun C. Evaluation of dental maturation in children according to sagittal jaw relationship. *Eur J Dent* 2014;8:38-43.

Access this article online	
<p><b>Quick Response Code:</b></p> 	<p><b>Website:</b> www.eurjdent.com</p>
<p><b>Source of Support:</b> Nil. <b>Conflict of Interest:</b> None declared</p>	