

A cone-beam computed tomography study of the root canal morphology of anterior teeth in a Turkish population

Mustafa Altunsoy¹, Evren Ok², Bilge Gulsum Nur¹, Osman Sami Aglarci³,
Enes Gungor⁴, Mehmet Colak⁴

¹Department of Pediatric Dentistry, Faculty of Dentistry, Sifa University, Izmir, Turkiye,

²Department of Endodontics, Faculty of Dentistry, Sifa University, Izmir, Turkiye,

³Department of Oral and Maxillofacial Radiology, Faculty of Dentistry, Sifa University, Izmir, Turkiye,

⁴Department of Oral and Maxillofacial Radiology, Faculty of Dentistry, Dicle University, Diyarbakir, Turkiye

Correspondence: Dr. Mustafa Altunsoy
Email: dtaltunsoy@gmail.com

ABSTRACT

Objective: The aim of this study was to determine the root and canal morphology of the maxillary and mandibular anterior teeth in a Turkish population by analyzing cone-beam computed tomography (CBCT) images. **Materials and Methods:** CBCT images of 417 females and 410 males with a mean age of ranging from 14 to 70 years were examined in this study. A total of 1453 maxillary central incisors, 1504 maxillary lateral incisors, 1523 maxillary canines, 1582 mandibular central incisors, 1603 mandibular lateral incisors, and 1604 mandibular canines were analyzed. The number of root canals and the canal configurations were investigated and then were classified according to Vertucci's classification. The data were analyzed with the Pearson Chi-square test. **Results:** The Type 1 canal configuration was most prevalent in the maxillary anterior teeth (96.8-99.7%). The Types 2, 3, 4, and 5 canal configurations were observed within the range of 0-1.3%, 0-0.8%, 0-0.7%, and 0-1.8%, respectively. In the mandibular anterior teeth, the Type 1 canal configuration was most prevalent (77-95%). The Types 2, 3, 4, and 5 canal configurations were observed within a range of 0.2-2.7%, 0.2-1.6%, 0.9-5.9%, and 1.8-14.4%, respectively. The prevalence of two canals was higher in males than in females both in the maxillary and mandibular anterior teeth ($P < 0.05$). **Conclusions:** Type 1 was the most prevalent canal configuration of maxillary and mandibular anterior teeth in the Turkish population. Type 5 was the most frequently observed canal configuration of the two canal teeth. The incidence of root canal numbers and configurations differed with sex.

Key words: Anterior teeth, cone-beam computed tomography, endodontics, root canal morphology

INTRODUCTION

Identification of root canal morphology and configuration plays an important role in successful endodontic diagnosis and treatment. There are differences in the root canal morphologies of different populations; thus, identifying the root canal anatomy of different ethnic populations is required for successful endodontic treatment.^[1-3] Many studies have examined root and canal morphologies using

various methods. The methods used in analyzing root canal morphology are sectioning,^[4] canal staining and tooth clearing techniques,^[5] conventional radiography techniques,^[6] contrast medium-enhanced radiography,^[7] modified canal staining and clearing,^[1] and computed tomography (CT) scanning.^[8]

Cone-beam CT (CBCT) scanning has been used in the field of endodontics since 1990.^[9] CBCT uses a cone-shaped beam of radiation to acquire data in

How to cite this article: Altunsoy M, Ok E, Nur BG, Aglarci OS, Gungor E, Colak M. A cone-beam computed tomography study of the root canal morphology of anterior teeth in a Turkish population. *Eur J Dent* 2014;8:302-6.

Copyright © 2014 Dental Investigations Society.

DOI: 10.4103/1305-7456.137630

a single 360° rotation, which reveals the internal structure of an object. When CBCT is compared with conventional CT, it provides improved accuracy, higher resolution, lower scan time, and radiation doses.^[10] CBCT can be used for diagnosis in endodontic applications due to its nondestructive *in vivo* application.

Many studies have performed to assess the anatomic characteristics and types of root canal morphology by conventional techniques^[1,4,5,7] and only two studies performed by CBCT.^[11,12] To the best of our knowledge, few studies have evaluated the root and canal morphology in the Turkish population.^[13-15] However, no data are available on the determination of root and canal morphology of the anterior teeth with CBCT in a Turkish population. Therefore, the aim of this study was to investigate and determine the root and canal morphology of the maxillary and mandibular anterior teeth in a Turkish population by analyzing CBCT images.

MATERIALS AND METHODS

Cone-beam computed tomography images were obtained in the Dicle University, Department of Oral and Maxillofacial Radiology between May 2009 and April 2012. This study was approved by the Institutional Review Board of Sifa University, Izmir, Turkey (B.30.2.ŞFÜ.00.50.500/52). Subjects with fully erupted permanent maxillary and mandibular anterior teeth (centrals, laterals, and canines) were selected. CBCT images of 417 women and 410 men with a mean age of ranging from 14 to 70 years were examined. A total of 1453 maxillary central incisors, 1504 maxillary lateral incisors, 1523 maxillary canines, 1582 mandibular central incisors, 1603 mandibular lateral incisors, and 1604 mandibular canines were analyzed in the database.

The CBCT images were obtained using a CBCT imaging system (I-CAT Vision TM Imaging Science

International, Hatfield, USA, 2008) at 120 kVp, 18.54 mA with an exposure time of 9 s. The voxel size of the images was 0.3 mm. An experienced radiologist acquired the images according to the manufacturer's instructions. Tomography sections of 0.3 mm axial planes were created. Serial axial CBCT images were examined by carefully rolling the toolbar from the pulp chamber to the apex [Figure 1].

Two examiners assessed all the images separately, and any disagreement between them was discussed until a consensus was reached. To test the reproducibility, the two observers reexamined 60 randomly selected radiographs 6 weeks after the first evaluation. Examination of results using the Wilcoxon matched paired signed-rank test showed no statistically significant difference between the two observers. The number of root canals and the canal configurations were classified according to Vertucci's classification^[5] [Figure 2]. The data were analyzed with Chi-square test. All statistical analyses were performed using SPSS (Version 17.0; SPSS Inc., Chicago, IL, USA) software.

RESULTS

The prevalence of the root canal numbers of the maxillary and mandibular anterior teeth are shown in Table 1. The most prevalent root canal numbers in the maxillary anterior teeth was one canal (approximately 96.8-99.7%), followed by two canals (approximately 0.3-3.2%). The prevalence of two canals was higher in males than in females in the maxillary anterior teeth. The most prevalent root canal numbers in the mandibular anterior teeth was one canal with a range of 77-95%, followed by two canals with a range of 5.3-18.9%. The prevalence of two canals was higher in males than in females in the mandibular anterior teeth.

Table 2 shows the prevalence of the different canal configurations in the maxillary anterior teeth. The Type 1 canal configuration was most prevalent in the

Table 1: Root canal number of the maxillary and mandibular anterior teeth *n* (%)

Maxillary teeth	Centrals		Laterals		Canines	
	Male	Female	Male	Female	Male	Female
Number of canals						
1	772 (99.6)	766 (99.7)	735 (96.8)	732 (98.3)	748 (96.8)	740 (98.7)
2	3 (0.4)	2 (0.3)	24 (3.2)	13 (1.7)	25 (3.2)	10 (1.3)
Total	1543		1504		1523	
Mandibular teeth						
1	636 (81.1)	704 (88.2)	617 (77.2)	678 (84.3)	741 (92)	757 (94.7)
2	148 (18.9)	94 (11.8)	182 (22.8)	126 (15.7)	64 (8)	42 (5.3)
Total	1582		1603		1604	

Table 2: Root canal configurations of the maxillary and mandibular anterior teeth *n* (%)

Maxillary teeth	Centrals		Laterals		Canines	
	Male	Female	Male	Female	Male	Female
Canal configurations						
1	771 (99.5)	766 (99.7)	734 (96.7)	732 (98.3)	748 (96.8)	740 (98.7)
2	0	0	10 (1.3)	5 (0.7)	5 (0.6)	1 (0.1)
3	3 (0.4)	0	5 (0.7)	0	6 (0.8)	1 (0.1)
4	0	2 (0.3)	0	4 (0.5)	0	5 (0.7)
5	1 (0.1)	0	10 (1.3)	4 (0.5)	14 (1.8)	3 (0.4)
6	0	0	0	0	0	0
7	0	0	0	0	0	0
8	0	0	0	0	0	0
Mandibular teeth						
1	633 (80.7)	704 (88.2)	613 (76.7)	673 (83.7)	737 (91.6)	751 (94)
2	5 (0.6)	2 (0.3)	13 (1.6)	8 (1)	21 (2.6)	13 (1.6)
3	10 (1.3)	2 (0.3)	11 (1.4)	5 (0.6)	12 (1.5)	7 (0.9)
4	33 (4.2)	34 (4.3)	47 (5.9)	39 (4.9)	7 (0.9)	14 (1.8)
5	103 (13.1)	56 (7)	115 (14.4)	79 (9.8)	28 (3.5)	14 (1.8)
6	0	0	0	0	0	0
7	0	0	0	0	0	0
8	0	0	0	0	0	0

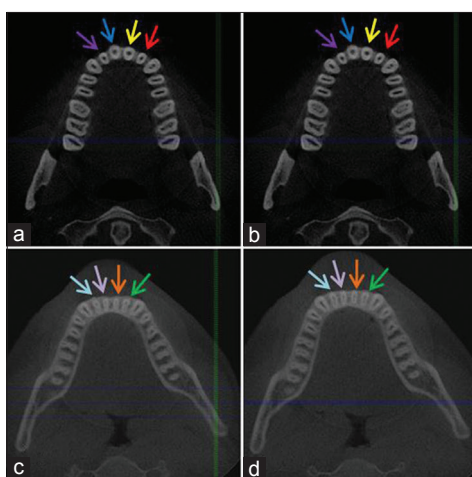


Figure 1: Images of teeth with root and canal configurations in axial section. (a) Coronal part of the root in maxillary teeth (b) apical part of the root in maxillary teeth (c) coronal part of the root in mandibular teeth (d) apical part of the root in mandibular teeth. (Same color arrows show the same color teeth)

maxillary anterior teeth (96.8-99.7%). The Type 2 canal configuration was observed within the range of 0-1.3%. The Type 3 canal configuration was observed within the range of 0-0.8%. The Type 4 canal configuration was observed within the range of 0-0.7%, and the Type 5 canal configuration was observed within the range of 0-1.8%. The distribution frequency for different canal configurations in the mandibular anterior teeth is shown in Table 2. The Type 1 canal configuration was the most prevalent in mandibular anterior teeth (77-95%). The Type 2 canal configuration was observed within the range of 0.2-2.7%. The Type 3 canal configuration was observed within the range of

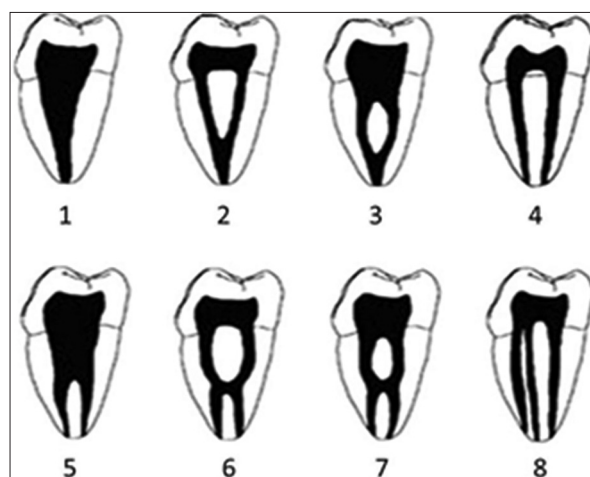


Figure 2: The Vertucci classification of root canal configurations

0.2-1.6%. The Type 4 canal configuration was observed within the range of 0.9-5.9%, and the Type 5 canal configuration was observed within the range of 1.8-14.4%.

DISCUSSION

Technological innovations have led to the improvement of new diagnostic and imaging techniques in dentistry. CBCT scanning provides an excellent imaging method to detect differences in external and internal dental anatomy. CBCT images offer high-resolution and are well-suited for endodontic applications.^[8,16] With the methods used in this study, the root and canal morphology of the teeth can be visualized in the three main plans.

Maxillary central incisor teeth have been reported to have one canal in 100% of American and Turkish populations.^[5,13] Sert and Bayirli^[15] have reported that maxillary central incisors have one canal in 98% of males and 99% of females in the Turkish population. Our study found that 99.6% and 99.7% of maxillary central incisors in males and females, respectively, had one canal. The canal configurations for teeth with two canals were Type 3 (0.4%) in males and Type 4 (0.3%) in females.

A study by Caliskan *et al.*^[13] have reported that 78.05% of maxillary laterals and 93.48% of maxillary canines had Type 1 canal configuration in a Turkish population. Sert and Bayirli^[15] reported that the root canal configurations for maxillary lateral incisors in males were 91% Type 1, 2% Type 2, 4% Type 3, and 5% Type 4. The root canal configuration of lateral incisors were 90% Type 1, 1.5% Type 2, and 5% Type 3 in females. In the same study, the root canal configurations for maxillary canines were 91% Type 1, 3% Type 2, 4% Type 3, and 2% Type 4 in males. The root canal configurations for female patients were 96% Type 1 and 4% Type 4. Weng *et al.*^[1] have reported that 95.8% of the maxillary central incisors, 97.1% of the maxillary lateral incisors, and 76.9% of the maxillary canines were Type 1 canal configuration in Han Nationality in China. In these studies, staining and clearing method were used. In the present investigation, Type 1 canal configuration was detected in 96.7% of maxillary laterals for males and 98.3% of maxillary laterals for females. Type 1 root canal configuration in maxillary canines was found in 96.8% of males and 98.7% of females. In our study, the prevalence of Type 1 canal configuration of the maxillary laterals and canines was higher than the results of these investigators mentioned above. However, our findings were close to the results reported by Sert and Bayirli.^[15]

Caliskan *et al.*^[13] have reported that 68.63% of the mandibular central and lateral incisors and 80.39% of the mandibular canines were found to have a Type 1 canal configuration in Turkish population. Al-Qudah and Awawdeh^[17] reported that 73.8% of the mandibular incisors had Type 1 canal configuration in a Jordanian population. In those studies, staining and clearing methods were used. In the studies performed by CBCT, Liu *et al.*^[12] have reported that the Type 1 canal configuration of the mandibular central and lateral incisors were 91.1% and 82.5%, respectively in a Chinese population and Aminsobhani *et al.*^[11] have reported that the Type 1 canal configuration of

the mandibular central, lateral incisors, and canines were 72.7%, 70.6%, and 71.8%, respectively in Iranian population. In this study, the Type 1 canal configuration of the mandibular centrals in males was 80.7% and 88.2% for females, mandibular laterals in males was 76.7% and 83.7% for females, and mandibular canines in males was 91.6% and 94% for females.

Sert and Bayirli^[15] reported that gender was an important factor to be considered in the preoperative evaluation of canal morphology for root canal treatment.^[8] In our study, the prevalence of two canals in the maxillary and mandibular anterior teeth was higher in males than in females, which is in agreement with the findings of Sert and Bayirli.^[15]

Our findings concerning the canal configurations of the maxillary and mandibular teeth are also different from the results of previous studies carried out in the Turkish population.^[13-15] These differences may be explained by certain factors. Regional differences in the country may have an influence on the outcome of morphological studies. It has been reported that differences between the results of morphological studies may be due to variations of examination methods, classification systems, sample sizes and ethnic backgrounds of tooth sources.^[14,18] To the best of our knowledge, there were only three studies in the literature concerned with canal numbers and configurations of maxillary and mandibular anterior permanent teeth in a Turkish population.^[13-15] These studies were performed with canal staining and tooth clearing techniques and used only 100 and 200 tooth samples for each type of tooth. In this study, the root canal numbers and configurations were determined with CBCT images. For each tooth, we evaluated approximately 1453-1604 images. Staining and clearing technique could give the most detailed information about the root canal anatomy in *in vitro* conditions.^[5,19] However, in clinical conditions this technique cannot be used and CBCT is a good option for identifying root canals, anatomical variations and root fractures and resorptions.^[20] Other factors affecting differences between the findings of current and previous studies may be differences in the region where studies were carried out. Previous studies were carried out in the Northwestern and Western regions of Turkey; however, in this study, we obtained CBCT images from patients who lived in the Southeastern of Turkey. These regions have profound environmental and climatic differences.

CONCLUSION

It can be concluded that a higher prevalence of maxillary and mandibular anterior teeth have a Type 1 canal configuration in the Turkish population. Type 5 was the most frequently observed canal configuration of two canaled teeth. The incidence of root canal numbers and configurations differed with gender. CBCT is a clinically useful device for endodontic diagnosis and treatment. We argue that this study provides supplemental information for dentists about root canal morphology of the anterior teeth in a Turkish population.

REFERENCES

1. Weng XL, Yu SB, Zhao SL, Wang HG, Mu T, Tang RY, *et al.* Root canal morphology of permanent maxillary teeth in the Han nationality in Chinese Guanzhong area: A new modified root canal staining technique. *J Endod* 2009;35:651-6.
2. Neelakantan P, Subbarao C, Ahuja R, Subbarao CV, Gutmann JL. Cone-beam computed tomography study of root and canal morphology of maxillary first and second molars in an Indian population. *J Endod* 2010;36:1622-7.
3. Unal GC, Kececi AD, Kaya BU, Tac AG. Quality of root canal fillings performed by undergraduate dental students. *Eur J Dent* 2011;5:324-30.
4. Weine FS, Healey HJ, Gerstein H, Evanson L. Canal configuration in the mesiobuccal root of the maxillary first molar and its endodontic significance. *Oral Surg Oral Med Oral Pathol* 1969;28:419-25.
5. Vertucci FJ. Root canal anatomy of the human permanent teeth. *Oral Surg Oral Med Oral Pathol* 1984;58:589-99.
6. Pineda F, Kuttler Y. Mesiodistal and buccolingual roentgenographic investigation of 7,275 root canals. *Oral Surg Oral Med Oral Pathol* 1972;33:101-10.
7. Fan B, Gao Y, Fan W, Gutmann JL. Identification of a C-shaped canal system in mandibular second molars-part II: The effect of bone image superimposition and intraradicular contrast medium on radiograph interpretation. *J Endod* 2008;34:160-5.
8. Zheng QH, Wang Y, Zhou XD, Wang Q, Zheng GN, Huang DM. A cone-beam computed tomography study of maxillary first permanent molar root and canal morphology in a Chinese population. *J Endod* 2010;36:1480-4.
9. Tachibana H, Matsumoto K. Applicability of X-ray computerized tomography in endodontics. *Endod Dent Traumatol* 1990;6:16-20.
10. Scarfe WC. Imaging of maxillofacial trauma: Evolutions and emerging revolutions. *Oral Surg Oral Med Oral Pathol Oral Radiol Endod* 2005;100:S75-96.
11. Aminsobhani M, Sadegh M, Meraji N, Razmi H, Kharazifard MJ. Evaluation of the root and canal morphology of mandibular permanent anterior teeth in an Iranian population by cone-beam computed tomography. *J Dent (Tehran)* 2013;10:358-66.
12. Liu J, Luo J, Dou L, Yang D. CBCT study of root and canal morphology of permanent mandibular incisors in a Chinese population. *Acta Odontol Scand* 2014;72:26-30.
13. Caliskan MK, Pehlivan Y, Sepetçioğlu F, Türkün M, Tuncer SS. Root canal morphology of human permanent teeth in a Turkish population. *J Endod* 1995;21:200-4.
14. Sert S, Aslanalp V, Tanalp J. Investigation of the root canal configurations of mandibular permanent teeth in the Turkish population. *Int Endod J* 2004;37:494-9.
15. Sert S, Bayirli GS. Evaluation of the root canal configurations of the mandibular and maxillary permanent teeth by gender in the Turkish population. *J Endod* 2004;30:391-8.
16. Park JB, Kim N, Park S, Kim Y, Ko Y. Evaluation of root anatomy of permanent mandibular premolars and molars in a Korean population with cone-beam computed tomography. *Eur J Dent* 2013;7:94-101.
17. Al-Qudah AA, Awawdeh LA. Root canal morphology of mandibular incisors in a Jordanian population. *Int Endod J* 2006;39:873-7.
18. Lambrianidis T, Lyroudia K, Pandelidou O, Nicolaou A. Evaluation of periapical radiographs in the recognition of C-shaped mandibular second molars. *Int Endod J* 2001;34:458-62.
19. Miyashita M, Kasahara E, Yasuda E, Yamamoto A, Sekizawa T. Root canal system of the mandibular incisor. *J Endod* 1997;23:479-84.
20. Cohenca N, Simon JH, Mathur A, Malfaz JM. Clinical indications for digital imaging in dento-alveolar trauma. Part 2: Root resorption. *Dent Traumatol* 2007;23:105-13.

Access this article online

Quick Response Code:



Website:

www.eurjdent.com

Source of Support: Manipal University.
Conflict of Interest: None declared