

# An unusual case of brown tumor of hyperparathyroidism associated with ectopic parathyroid adenoma

Mathan Mohan<sup>1</sup>, Ravana Sundaram Neelakandan<sup>1</sup>, D. Siddharth<sup>1</sup>, Ravi Sharma<sup>1</sup>

**Correspondence:** Dr. Ravi Sharma  
Email: ravisharma\_19@yahoo.com

<sup>1</sup>Department of Surgical Oncology, New Hope Medical Centre, Kilpauk, Chennai, Tamil Nadu, India

## ABSTRACT

Brown tumor is a giant cell lesion associated with hyperparathyroidism. It is a non-neoplastic condition and represents terminal stage of the remodeling process in hyperparathyroid state. We report a case of brown tumor with multiple lesions in craniofacial region associated with ectopic parathyroid adenoma revealed after acute L-thyroxine poisoning. This case report emphasizes on the need for routine biochemical investigations along with serum calcium, phosphorus and parathyroid hormone levels in patients on thyroxine therapy.

**Key words:** Brown tumor, ectopic parathyroid gland, giant cell lesions, hyperparathyroidism, parathyroid hormone, thyroxine

## INTRODUCTION

Brown tumor is a non-neoplastic giant cell lesion characterized by increased circulating levels of parathyroid hormone (PTH). This tumor represents the terminal stage of bone remodeling processes in hyperparathyroid state. It is usually an uncommon lesion occurring with the frequency of 4.5% in primary hyperparathyroidism (HPT) and 1.5-1.7% in cases of secondary HPT, with overall incidence of 0.1%.<sup>[1]</sup>

HPT can be classified into: primary, which occurs due to hyperplasia, benign or malignant neoplasm of one or more parathyroid gland. Secondary HPT is caused as a result of hypocalcemia, vitamin D deficiency or secondary to chronic renal insufficiency, which acts as a stimulus for PTH production. Tertiary HPT is associated with renal failure and autonomous functioning glands in long-standing secondary HPT cases. The fourth type of HPT has been recognized, which occurs due to increased PTH levels synthesized in patients with malignant diseases.<sup>[2]</sup>

We report an interesting and rather unique case of a brown tumor of maxilla and mandible developing

after acute exogenous thyroxine poisoning in a young female patient under treatment for hypothyroidism and ectopic intrathoracic parathyroid adenoma.

## CASE REPORT

A 23-year-old female reported to our department with the chief complaint of a swelling on the left side of the lower jaw for past 4 months producing facial asymmetry. Patient was a known hypothyroid and was under exogenous levothyroxine (L-thyroxine) therapy for the past 3 years. She gave history of L-thyroxine poisoning (approximately 4000 mcg stat dose) 4 months back after which she developed rapidly growing swelling on the left side of the jaw.

Extraoral examination revealed the presence of a well-circumscribed expansile swelling in the left mandibular body region measuring 5 cm × 4 cm, which was hard, non-tender and non-mobile without any surface changes. There was no paresthesia or lymphadenopathy associated with the swelling. Intraorally, obliteration of buccal vestibule on the left side with intact normal mucosa was seen. No

**How to cite this article:** Mohan M, Neelakandan RS, Siddharth D, Sharma R. An unusual case of brown tumor of hyperparathyroidism associated with ectopic parathyroid adenoma. *Eur J Dent* 2013;7:500-3.

Copyright © 2013 Dental Investigations Society.

DOI: 10.4103/1305-7456.120657

mobility, loss of vitality or tenderness was elicited with any teeth in the left quadrant.

Biochemical assay and blood analysis revealed an increased value of serum alkaline phosphatase (420 u/l; normal range: 100-172 u/l), serum PTH (370.40 pg/ml; normal range: 50-300 pg/ml) and serum calcium (13.3 mgs/dl; normal range: 8.5-11.0 mg/dl). The serum phosphorus level was decreased (2.4 mg/dl; normal range: 2.7-4.5 mg/dl).

Cone beam computed tomography (CT) scan of the facial region revealed a well-defined soft tissue lesion within the left body of the mandible of approximately 3.5 cm × 2.8 cm [Figure 1a and d]. It also represented well-defined hypodense lesions in relation to the right body of the mandible measuring 2.5 cm × 1.0 cm [Figure 1d] and anterior maxilla, measuring 3.5 cm × 3.6 cm [Figure 1b]. There was also lytic lesion on the left side skull bone with generalized reduction in bone density [Figure 1c]. A Full body skeletal survey was also performed, which revealed no such lesions in long bones.

Ultrasound of neck failed to reveal any pathology in thyroid and parathyroid glands. To further assess the parathyroid gland status <sup>99m</sup>Tc sestamibi-SPECT parathyroid scintigraphy was carried out, which demonstrated relatively prominent flow of activity toward left submandibular salivary gland region. Abnormal ovoid region of intense tracer concentration in the anterior mediastinum in right paratracheal region was noted. The findings were suggestive

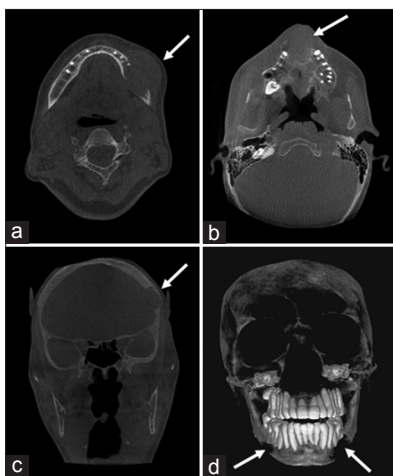
of ectopic (intrathoracic) parathyroid gland with neoplastic changes in left submandibular salivary gland region [Figure 2a]. Ultrasound of the abdomen, renal function tests were unremarkable.

CT scan of the chest was taken, which revealed a moderate size nodular lesion showing heterogeneous enhancement in right prevascular space measuring 3.0 cm × 2.4 cm [Figure 2b]. The history, biochemical values and imaging reports corroborated with the clinical features of the brown tumor of HPT associated with pathologic ectopic parathyroid gland.

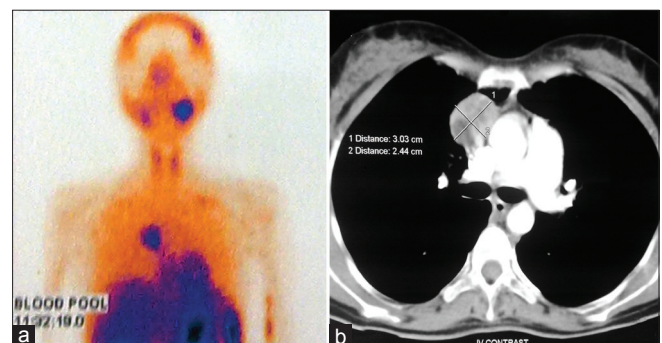
An incisional biopsy of the mandibular lesion was performed under local anesthesia that revealed fibro collagenous tissue containing plenty of osteoclastic giant cells dispersed throughout the lesion with small fragments of reactive bone, the features consistent with reparative giant cell granuloma.

The patient was then prepared for surgery under general anesthesia. Thoracotomy was carried out and ectopic intrathoracic parathyroid gland was excised [Figure 3a]. An intraoral buccal vestibular incision was used to access the mandibular lesion. A combination of sharp and blunt dissection was used to excise the mass and it was delivered per oral in total [Figure 3b]. The wound was closed in a single layer. Post-operative recovery was uneventful. Post-operative serum calcium level was 10.6 mg/dl and PTH level 11.90 pg/mg.

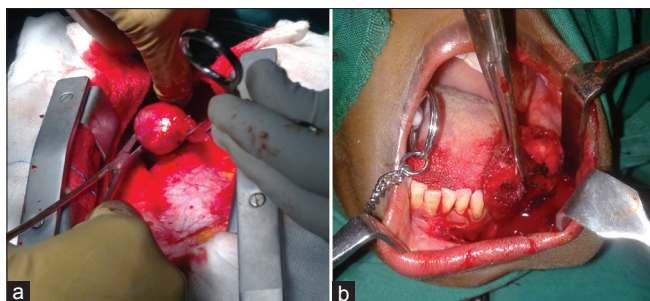
The intrathoracic mass and mandibular specimen was sent for histopathological examination. The intrathoracic mass revealed parathyroid neoplasm suggestive of atypical parathyroid adenoma [Figure 4a]. The mandibular lesion presented a giant cell proliferation in the background of a



**Figure 1:** (a) Computed tomography scan (axial section) showing well-defined soft tissue lesion within the left body of the mandible. (b) Axial section showing maxillary lesion. (c) Coronal section showing skull bone lesion on the left side. (d) 3D reconstruction showing bilateral lytic lesion within the body of the mandible and generalized reduction in the bone density (arrow indicating the lesion)



**Figure 2:** (a) <sup>99m</sup>Tc sestamibi-single photon emission computed tomography parathyroid scintigraphy image showing intense tracer concentration in right paratracheal region and left submandibular region. (b) Computed tomography scan (axial section) showing well defined mass in intrathoracic prevascular space



**Figure 3:** Intra-operative view of (a) Ectopic parathyroid gland. (b) Left mandibular lesion

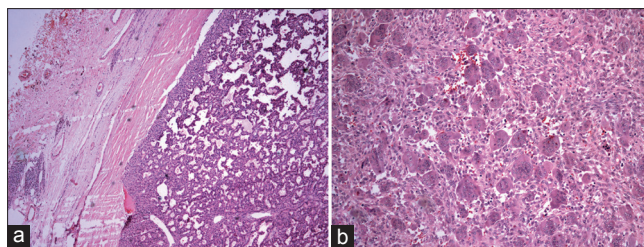
variably fibrotic stroma. The giant cells were arranged in sheets with little intervening spindle cell stroma. At the periphery osteopenic bone trabeculae were noted, showing both osteoblastic (prominent) and osteoclastic rimming. These features were suggestive of brown tumor of HPT [Figure 4b].

## DISCUSSION

PTH plays a key role in calcium and phosphate balance between extracellular fluid and bones. Brown tumor is relatively an uncommon lesion associated with HPT, which results in an abnormal osteoclastic and osteoblastic activity resulting in resorption and fibrous replacement of the bone.<sup>[1]</sup>

Brown tumor is more commonly found in ribs, clavicles, pelvis, femur and facial bones. In craniofacial region mandible is more frequently involved than maxilla.<sup>[3]</sup> Simultaneous involvement of both jaws is extremely rare.<sup>[2]</sup> Radiographically, this lesion appears as well-defined unilocular or multilocular radiolucencies causing cortical plate expansion and often thinning of the cortical plates. The density of jaw is decreased due to generalized demineralization of the medullary bones along with change in trabeculae pattern giving a mixed radiopaque-radiolucent appearance. Loss of lamina dura and root resorption is seldom seen.<sup>[3]</sup>

Brown tumor mimics giant cell lesions and it can be distinguished from the latter based upon the clinical history and biochemical profile of the patient indicating HPT.<sup>[3]</sup> Due to overlapping clinical and radiological features, patients presenting in maxillofacial department with suspected giant cell lesion should undergo biochemical assay to rule out HPT. Other differentials to be included are cherubism, aneurysmal bone cyst, Paget's disease, Langerhans cell histiocytosis, osteosarcoma and osteomyelitis.<sup>[2]</sup>



**Figure 4:** (a) Histopathological section of mandibular lesion showing giant cell proliferation with variable areas of haemorrhage and hemosiderin deposition (H and E,  $\times 20$ ). (b) Histopathological section of parathyroid neoplasm composed of nuclear pleomorphism with cystic changes, suggestive of parathyroid adenoma (H and E,  $\times 20$ )

Histopathologically, brown tumor reveals multinucleated giant cells in a background of spindle cell proliferation along with a large amount of hemosiderin deposition, vascularity and hemorrhage giving brown appearance to this lesion.<sup>[1,3]</sup>

The most interesting aspect of this case report is association of brown tumor with ectopic intrathoracic parathyroid gland with normal functioning anatomic parathyroid glands. Ectopic parathyroid glands are uncommon, mainly arising due to abnormal migration of parathyroid tissue during embryogenesis. It has been reported that in almost 16% cases of HPT, ectopic parathyroid glands are present, which may often go unnoticed and are a cause for failed parathyroid exploration.<sup>[4]</sup> The uniqueness of the case is further defined by its occurrence at a very young age (23 years) along with its bilateral presentation with simultaneous involvement of maxilla, mandible and skull bones in a brief period.

This patient was hypothyroid, under thyroxine therapy for past 3 years with an episode of acute poisoning of L-thyroxine before the onset of swelling of the jaw. The routine biochemical examination of patient taken 3 months prior to the onset of swelling revealed normal serum calcium and phosphorus levels and hypothyroid state. Unfortunately, consultant endocrinologist and physicians failed to observe any relation between the hyperparathyroid state of the patient and exogenous thyroxine.

To best of our knowledge, no case of brown tumor of HPT with such aggressive behavior and wide spectrum of clinical findings associated with acute thyroxine ingestion has been reported in the past.<sup>[5,6]</sup> Hence, we assume that either bolus toxic dose of thyroxine or chronic state of hypothyroidism has caused a high PTH and serum calcium levels resulting in a hyperparathyroid state causing bone remodeling events in the craniofacial region.

The exact mechanism of the interaction of thyroid and PTHs is unclear. Few authors have reported that prolonged thyroid-stimulating hormone (TSH) stimulation may lead to HPT or a state of HPT in hypothyroidism and vice versa.<sup>[7,8]</sup> This case report establishes a credible support for this hypothesis and brings out a definite correlation between TSH inhibition and onset of HPT.

The treatment of brown tumor mainly focuses on correction of the underlying disorder and maintenance of normal PTH and serum calcium levels. Use of systemic or intralesional corticosteroid have been reported to reduce the size of the lesion. Surgical excision is only indicated in large lesion causing severe disfigurement.<sup>[2]</sup> Long-term follow-up of such lesion is mandatory as variable clinical behavior of the lesion following normalization of the PTH and serum calcium levels has been reported.<sup>[9]</sup>

We have also adopted a similar protocol with surgical excision of the pathological ectopic parathyroid gland and mandibular tumor, which was causing severe disfigurement of the patient's face. PTH and serum calcium levels were found to be normal within 3 days after surgery. Patient has been maintained in euthyroid state with L-thyroxine therapy. Follow-up radiographs of the patient has revealed marked regression in the craniofacial lesions.

Ultra sonographic scan, CT scan and full body skeletal survey in conjunction with complete biochemical analysis can be carried out to assess the pathological parathyroid gland and extent of lesions in long bones. Latest imaging techniques such as <sup>99m</sup>Tc-sestamibi scan and <sup>18</sup>fluorine-fluorodeoxyglucose-positron emission tomography/CT have been proved to be an effective and useful diagnostic modality in assessing location and functioning of parathyroid glands.<sup>[4,10]</sup>

Our patient represents a rare case of brown tumor with a wide spectrum of associated clinical findings. In conclusion, the management of the brown tumor should involve early diagnosis, complete biochemical assay and full body skeletal survey followed by normalization of PTH, serum calcium and phosphorus levels and parathyroidectomy, if indicated. In the

absence of any pathology of anatomic parathyroid, ectopic sites should be assessed. This case emphasizes the need for periodic biochemical investigations in the hypothyroid patients on exogenous thyroxine therapy.

## ACKNOWLEDGMENTS

The authors would like to acknowledge the support of Dr. Joseph Arnold and Dr. Vinod Krishna for their sincere efforts in development of this article.

## REFERENCES

1. Soundarya N, Sharada P, Prakash N, Pradeep G. Bilateral maxillary brown tumors in a patient with primary hyperparathyroidism: Report of a rare entity and review of literature. *J Oral Maxillofac Pathol* 2011;15:56-9.
2. Selvi F, Cakarer S, Tanakol R, Guler SD, Keskin C. Brown tumour of the maxilla and mandible: A rare complication of tertiary hyperparathyroidism. *Dentomaxillofac Radiol* 2009;38:53-8.
3. Triantafillidou K, Zouloumis L, Karakinaris G, Kalimeras E, Iordanidis F. Brown tumors of the jaws associated with primary or secondary hyperparathyroidism. A clinical study and review of the literature. *Am J Otolaryngol* 2006;27:281-6.
4. Phitayakorn R, McHenry CR. Incidence and location of ectopic abnormal parathyroid glands. *Am J Surg* 2006;191:418-23.
5. Paggi A, Trimarchi CP, Cavallaro A. An ectopic parathyroid adenoma revealed by L-thyroxine side effect on bone. Case report. *Endocr Res* 1997;23:205-12.
6. Kwee HW, Marapin V, Verkeyn J, van Nederveen F. A man with thyroid abnormalities: Ectopic parathyroid adenoma and multifocal thyroid carcinoma. *Ned Tijdschr Geneesk* 2012;156:A5146.
7. Paloyan Walker R, Kazuko E, Gopalsami C, Bassali J, Lawrence AM, Paloyan E. Hyperparathyroidism associated with a chronic hypothyroid state. *Laryngoscope* 1997;107:903-9.
8. Castro JH, Genuth SM, Klein L. Comparative response to parathyroid hormone in hyperthyroidism and hypothyroidism. *Metabolism* 1975;24:839-48.
9. Daniels JS. Primary hyperparathyroidism presenting as a palatal brown tumor. *Oral Surg Oral Med Oral Pathol Oral Radiol Endod* 2004;98:409-13.
10. Santiago Chinchilla A, Ramos Font C, Muros de Fuentes MA, Navarro-Pelayo Láinez M, Palacios Gerona H, Moreno Caballero M, *et al.* False negative of the scintigraphy with <sup>99m</sup>Tc-sestamibi in parathyroid carcinoma with associated brown tumors. Contributions of the <sup>18</sup>F-FDG-PET/CT. *Rev Esp Med Nucl* 2011;30:174-9.

Access this article online	
<b>Quick Response Code:</b> 	<b>Website:</b> <a href="http://www.eurjdent.com">www.eurjdent.com</a>
<b>Source of Support:</b> Nil. <b>Conflict of Interest:</b> None declared	