

# The validation of a novel index assessing canine impactions

Chung How Kau<sup>1</sup>, John J. Lee<sup>2</sup>, Nada M. Souccar<sup>1</sup>

**Correspondence:** Dr. Chung How Kau  
Email: ckau@uab.edu

<sup>1</sup>Department of Orthodontics, University of Alabama, Birmingham, Alabama, USA,  
<sup>2</sup>Former Dental Student, Dental Branch, University of Texas Health Science Center at Houston, Houston, Texas, USA

## ABSTRACT

**Aim:** The aims of this study are to determine the level of agreement of orthodontists in the management of impacted maxillary canines and test this agreement against a novel three-dimensional (3D) classification system (KPG index). **Materials and Methods:** A total of 55 clinicians evaluated 18 impacted maxillary canines of variable complexity. For each case, they used a panoramic and maxillary standard occlusal radiographs derived from cone beam computed tomography. Clinicians were asked to rate each canine in one of four categories: Easy, moderate, difficult and extremely difficult. The obtained scores were tabulated and compared with a novel index rating the difficulty of canine impactions. Statistical package for the social science 17.0 was used to analyze the datasets and the kappa score was used to determine levels of agreement. **Results:** The kappa score was 0.437. The levels of agreement in the novel index and the clinician scoring were as follows; easy (62.73%), moderate (60.59%), difficult (61.80%) and extremely difficult (72.72%). **Conclusions:** The following conclusions can be drawn from this study: (1) Clinicians are variable in rating the complexity of canine impactions using traditional radiographic techniques. (2) The novel index shows a good level of agreement with the clinician's perception of difficulty in orthodontic cases especially at the extremes of the spectrum. (3) This index based on the 3D coordinates of the spatial arrangement of the canine may be incorporated into clinical practice.

**Key words:** Canine impactions, novel index, KPG index

## INTRODUCTION

The incidence of canine impaction varies across populations and has been reported to a range between 2% and 3% in the maxilla.<sup>[1,2]</sup> About two-thirds of impacted maxillary canines are positioned palatally.<sup>[3]</sup> Traditionally, orthodontists relied on clinical examination and radiographs to locate impacted teeth and decide on a treatment plan. With the availability of three-dimensional (3D) imaging techniques like the cone beam computed tomography (CBCT), it is possible to precisely position the impacted canines, determine the amount of bone covering it and evaluate the condition of adjacent anatomic structures.<sup>[4,5]</sup> CBCT uses a cone shaped X-ray beam, resulting in a 3D reconstruction of the teeth and jaws. Moreover, radiation dosage and scanning time are

significantly reduced compared with conventional computed tomography (CT).<sup>[6,7]</sup> Treatment of impacted canines usually requires a good cooperation between the Orthodontist and the oral surgeon or Periodontist.<sup>[8,9]</sup> One complication following canine impaction treatment is root resorption and may result in dental extraction and a significant increase in treatment time and/or expenses.<sup>[10,11]</sup>

Simple classifications two-dimensional (2D) classifications of canine impactions have been developed. These often require a second radiograph to be taken. The KPG index for the classification of canine impactions has been developed in an effort to standardize diagnosis and predict treatment difficulty.<sup>[12]</sup> This index represents the first index that uses the 3D of space in a 3D volume

**How to cite this article:** Kau CH, Lee JJ, Souccar NM. The validation of a novel index assessing canine impactions. *Eur J Dent* 2013;7:399-404.

Copyright © 2013 Dental Investigations Society.

DOI: 10.4103/1305-7456.120648

for understanding of spatial relationship of the impacted tooth. The aims of our present study are to:

- Determine the level of agreement of orthodontists in the management of impacted maxillary canines using conventional/traditional methods and
- Test this agreement against a previously described 3D classification system (KPG index).

## MATERIALS AND METHODS

### Subjects

In this study, 18 ectopic maxillary canines from 12 subjects were included. Six patients had two ectopic maxillary canines, one on the right and one on the left side. Four patients had four right ectopic maxillary canines and two patients had two left ectopic maxillary canines.

### Imaging modality

Cone beam images were taken on all patients at the 3D imaging facility at the University of Texas Health Science Center at Houston using the sirona Galileos system (Sirona Dental Systems LLC, NC, USA). This machine featured 14 s scanning time, radiation dosage of 29  $\mu$  Si and a field of view made-up of a sphere with a diameter of 16 cm. The voxel size was 0.15-0.30 mm

and the grayscale 12 bit. Image reconstruction time was 3 min. Using the Sidexis software (sirona), panoramic and occlusal views were examined for each patient. Sagittal, coronal and axial views were clearly visible and normal radiographic projections were possible as well.

### KPG index

The KPG Index<sup>[12]</sup> allows the clinician to score the position of a canine crown and root on a CBCT in the three dimensions of space: The mesiodistal position of the canine crown and root relative to the adjacent teeth is assessed on the X-axis of the CBCT panoramic view [Figure 1]. Similarly, the vertical position of the canine cusp tip or root tip relative to its normal developmental position is assessed on the Y-axis [Figures 2 and 3]. The Z-axis is visualized on axial cuts [Figure 4]. Distances measured perpendicularly from the cusp or root tip to the curved line of the occlusal line in 2 mm increments permit the evaluation of severity. This transverse dimension is of particular interest since it is not observable on 2D radiographs. The sum of all-three scores determines the complexity of treatment for a particular tooth: Easy cases range from 0 to 10, moderate from 10 to 14, difficult from 15 to 19. A score of 20 and above represent extreme difficulty.

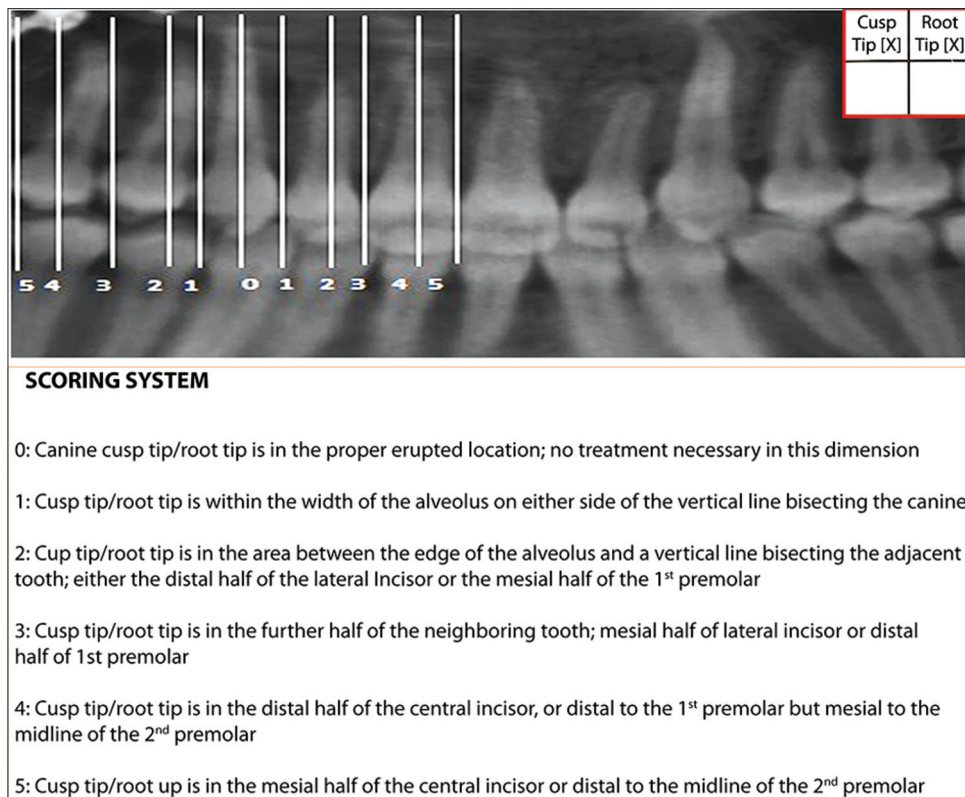


Figure 1: The KPG index showing the horizontal scoring

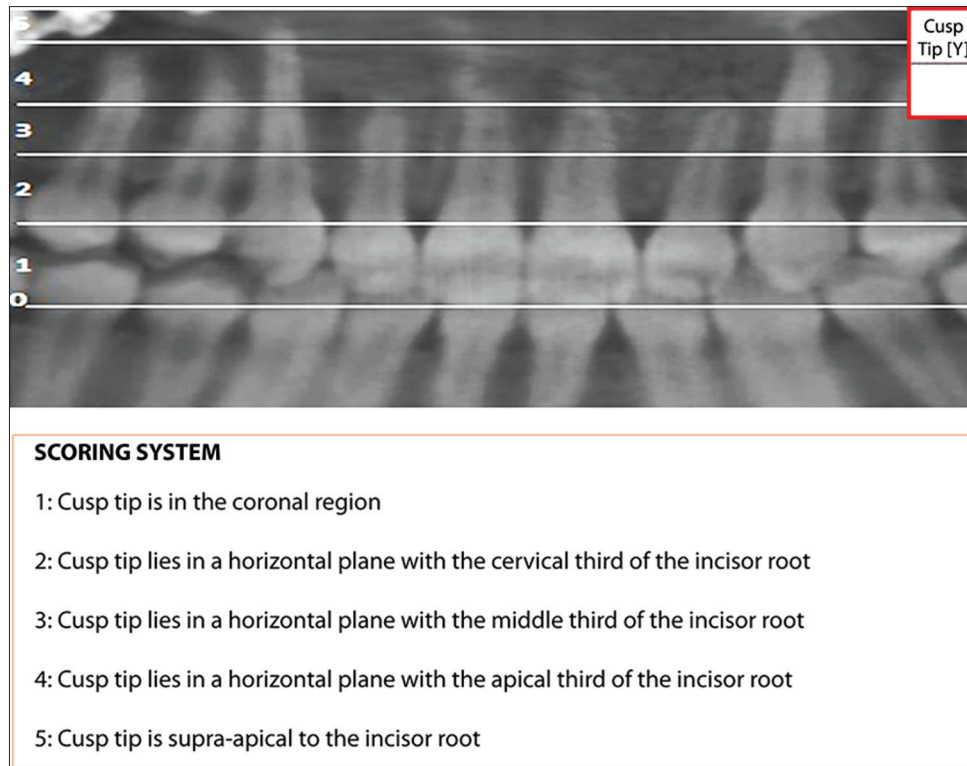


Figure 2: Vertical scoring of the cusp tip of the canine

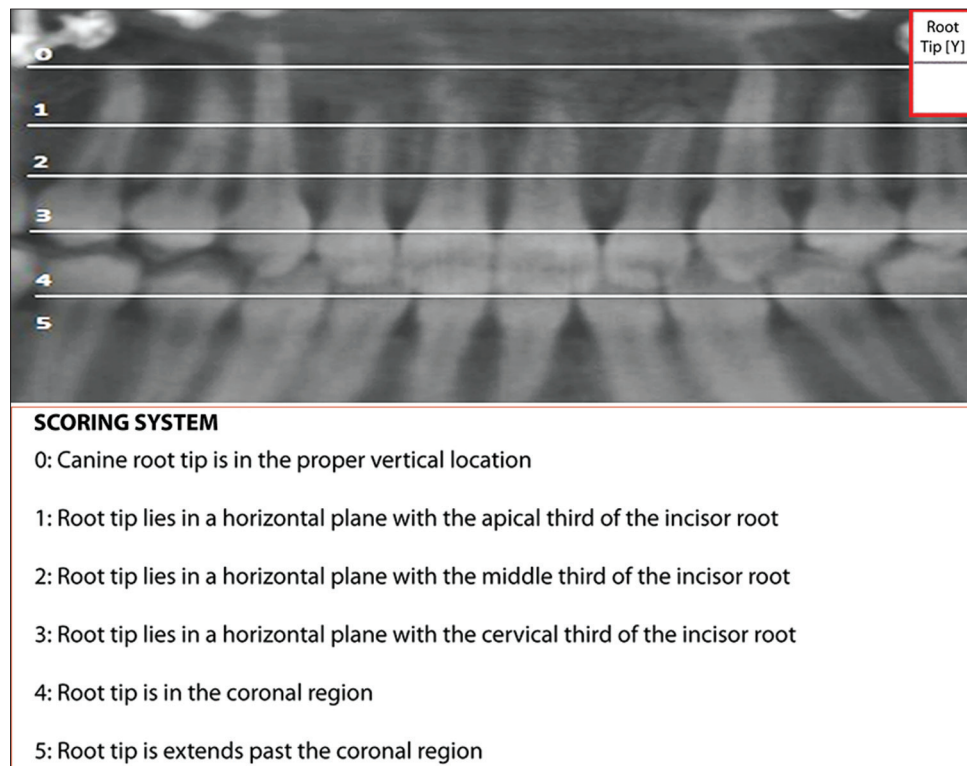


Figure 3: Vertical scoring of the root tip of the canine

### Validation process

#### Peer review

A panel of 55 clinicians was invited to evaluate, for each of the 12 patients, one panoramic and one

occlusal radiograph generated from the CBCT. Based on their experience, they were asked to assess the severity of canine impaction. One result per canine was reported in a table with four levels of

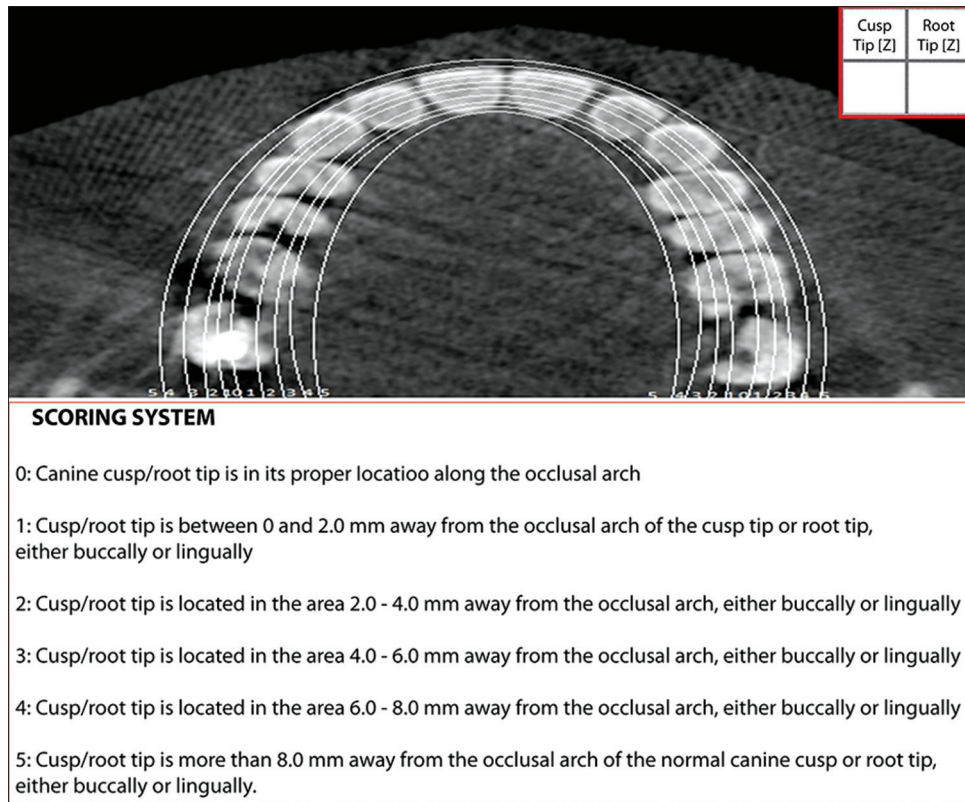


Figure 4: Scoring of the position of the canine to the line of occlusion from the axial view

difficulty: Easy, moderate, difficult and extremely difficult. Easy was to be marked by the clinicians if they felt that the case was within normal or routine orthodontic procedure, moderate if some extra care and orthodontic mechanics were required, difficult if special skills and extra orthodontic mechanics were needed and extremely difficult if it was a very complex case that called for canine extraction. Only one level of difficulty was selected per canine. 990 responses were expected. Microsoft office excel (2007) was used to gather the recorded data.

#### KPG score

Using the KPG index, one examiner (CHK) independently rated each of the ectopic canines. A score between 0 and 5 was assigned to the crown tip and for the root tip in each of the 3D views (X-, Y- and Z-axis). The final score for each tooth was obtained by adding the six subscores for a maximum total of 30. This score was not communicated to the panel of examiners.

#### Statistical analysis

Kappa statistics were used to test the level of agreement between the panel and the KPG index. Data was imported from Microsoft excel to statistical package for the social sciences (SPSS) software, (SPSS Inc., Chicago, IL, USA) version 17.0. Agreement

between the KPG score and clinician's evaluation on each canine was analyzed. In addition, percentages of responses agreeing with the KPG index were calculated.

## RESULTS

Three cases had no scores and were excluded from the final tabulation, resulting in a total of 987 evaluations. In order to better reflect the clinical evaluations, the index was modified, as shown in Table 1 and the cases were rated with both the initial and the modified KPG indices. Table 2 presents the cases relative distribution in the four level categories (easy, moderate, difficult and extreme) by means of the modified KPG index and the clinicians' judgment. The columns reflect the panel's opinion, whereas the rows show the KPG assignment of the cases into each category. The highest number of obtained responses/calculated scores was in the difficult category (179 cases). The calculated kappa score, which reflects observer variability, was 0.437. Table 3 shows the case by case percentages of agreement between clinician scoring and original KPG index ("matched for KPG original") and between clinician scoring and novel KPG index ("matched for KPG modified"). When the panel's opinion was divided between two adjacent

categories, the four groups were merged into 2 broad groups according to this split and the overall percentage of clinicians agreeing with the KPG index in these new large subgroups was calculated and reported under the “justification” column. For example, 25 clinicians consider patient 1’s case to be easy, whereas 30 consider it to be moderate to difficult. The controversy exists between the two adjacent columns “easy” and “moderate.” Since the modified KPG classifies the case as “moderate,” 30 clinicians out of 55 agree with the index (54.55%).

**Table 1: Modified KPG index. Cut point for “easy” and “moderate” categories are modified to better reflect clinical judgment**

Level	Original KPG	Modified KPG
Easy	0-9	0-7
Moderate	10-14	7-14
Difficult	15-19	15-19
Extreme	≥20	≥20

**Table 2: KPG index\* clinicians crosstabulation. The level of agreement between the original KPG index and clinical evaluation is shown for each category**

	Clinicians				Total
	Easy	Moderate	Difficult	Extreme	
KPG index					
Easy	69	29	10	1	109
Moderate	97	174	53	6	330
Difficult	11	114	179	25	329
Extreme	1	1	57	160	219
Total	178	318	299	192	987

The highest agreements were obtained for case #10 (94.54%) and #12 (80%). These cases represent the extreme of the spectrum since the KPG index classifies them as “extremely difficult” and “easy,” respectively.

## DISCUSSION

CBCT has been extensively used in diagnosing dental impactions. It allows visualization of the three dimensions of space and a precise evaluation of canine position relative to adjacent anatomic structures.<sup>[10,13-15]</sup> The KPG index employs a simple method to locate and assign a difficulty score to impacted canines using CBCTs. Particularly, the Z-axis view shows the distance of the canine crown or root tip relative to its ideal position on the maxillary arch. The first aim of our study was to test the clinical agreement among a panel of clinicians. Our results indicate that the panel’s reports were very variable, demonstrating the heterogeneity of judgment among clinicians. These findings are concordant with a recent study,<sup>[13]</sup> which compared the differences in the diagnosis and treatment planning of impacted canines between 2D and 3D images: Seven faculty members were asked to evaluate 25 maxillary impacted canines. Their answers did not seem to agree on the localization of the cuspid tips (bucco-lingual and mesio-distal). Moreover, the suggested treatment plans were shown to be influenced by the imaging modality. Likewise, another study<sup>[16]</sup> using traditional radiography and CBCTs to investigate pathologies and impactions in the anterior

**Table 3: Case by case level of agreement between clinician scoring, original KPG index and modified KPG**

Patient	Case	Easy	Moderate	Difficult	Extreme	KPG index	KPG original	KPG modified	Matched for KPG original (%)	Matched for KPG modified (%)	Justification (%)
1	LC	25	27	3	0	7	Easy	Moderate	45.45	49.09	54.55
1	RC	22	27	6	0	7	Easy	Moderate	40.00	49.09	60.00
2	LC	17	34	3	1	12	Moderate	Moderate	61.82	61.82	69.00
2	RC	24	27	4	0	9	Easy	Moderate	43.64	49.09	56.36
3	LC	0	0	14	41	20	Extreme	Extreme	74.55	74.55	74.54
3	RC	0	1	17	37	20	Extreme	Extreme	67.27	67.27	67.27
4	RC	0	9	38	8	15	Difficult	Difficult	69.09	69.09	83.63
5	LC	2	31	21	1	14	Moderate	Moderate	56.36	56.36	60.00
5	RC	25	21	8	1	4	Easy	Easy	45.45	45.45	45.45
6	RC	1	0	23	30	21	Extreme	Extreme	54.55	54.55	54.54
7	LC	1	19	33	2	16	Difficult	Difficult	60.00	60.00	63.63
7	RC	1	21	30	3	16	Difficult	Difficult	54.55	54.55	60.00
8	LC	1	22	28	4	15	Difficult	Difficult	50.91	50.91	58.18
8	RC	1	24	27	3	15	Difficult	Difficult	49.09	49.09	54.55
9	LC	7	28	16	4	10	Moderate	Moderate	50.91	50.91	63.64
10	RC	0	0	3	52	25	Extreme	Extreme	94.54	94.54	94.54
11	LC	7	19	23	5	16	Difficult	Difficult	41.82	41.82	50.91
12	LC	44	8	2	0	5	Easy	Easy	80.00	80.00	80.00

LC: Left Canine, RC: Right Canine

maxilla demonstrates the difference in pathology diagnosis and root resorption assessment among pediatric dentistry faculty members and residents. Therefore, there is a clear need for a standardized index that would estimate the complexity of canine impaction.

The second aim of this study was to test the agreement between clinical judgment and the KPG index. The panel was given one panoramic and one occlusal radiograph generated from the CBCT. The calculated Kappa score of 0.437 between the novel KPG index and the clinical evaluation of cases indicates moderate inter-observer agreement. When the KPG index was modified, better percentage agreements between the clinical perception of the case and the index reflection of its difficulty were reached. Similarly, when four levels of difficulty are considered, the index does not reflect well clinical evaluation since a little less than half of the panel agrees with the scoring. However, when the levels of difficulty are only divided into two broad groups based on the novel KPG index as explained in the previous section, the percentages of agreement increase as follows: Easy (62.73%), moderate (60.59%), difficult (61.80%) and extremely difficult (72.72%). Our study does not aim at comparing 2D and 3D imaging modalities. Nevertheless, one way to improve the percentages of agreement between the KPG index and clinical evaluation is to give the clinicians the full CBCT views, allowing them to have 3D observations of the canines.

The novel KPG index still needs to be validated longitudinally for biomechanical consideration and treatment time prediction. One way of achieving this goal is to reevaluate these 18 canines post-orthodontics regarding the chosen treatment plan, the mechanics used as well as the time spent in treatment and correlate these findings with the initial projection based on the KPG score.

## CONCLUSIONS

The following conclusions can be drawn from this study:

- Clinicians are variable in rating the complexity of canine impactions using traditional radiographic techniques
- The novel index shows a good level of agreement with the clinician's perception of difficulty in orthodontic cases

- A new index based on the 3D coordinates of the spatial arrangement of the canine may be incorporated into clinical practice.

## REFERENCES

1. Bedoya MM, Park JH. A review of the diagnosis and management of impacted maxillary canines. *J Am Dent Assoc* 2009;140:1485-93.
2. Baccetti T, Mucedero M, Leonardi M, Cozza P. Interceptive treatment of palatal impaction of maxillary canines with rapid maxillary expansion: A randomized clinical trial. *Am J Orthod Dentofacial Orthop* 2009;136:657-61.
3. Johnston WD. Treatment of palatally impacted canine teeth. *Am J Orthod* 1969;56:589-96.
4. Walker L, Enciso R, Mah J. Three-dimensional localization of maxillary canines with cone-beam computed tomography. *Am J Orthod Dentofacial Orthop* 2005;128:418-23.
5. Peck JL, Sameshima GT, Miller A, Worth P, Hatcher DC. Mesiodistal root angulation using panoramic and cone beam CT. *Angle Orthod* 2007;77:206-13.
6. De Vos W, Casselman J, Swennen GR. Cone-beam computerized tomography (CBCT) imaging of the oral and maxillofacial region: A systematic review of the literature. *Int J Oral Maxillofac Surg* 2009;38:609-25.
7. Kau CH, Bozic M, English J, Lee R, Bussa H, Ellis RK. Cone-beam computed tomography of the maxillofacial region – An update. *Int J Med Robot* 2009;5:366-80.
8. Bishara SE. Clinical management of impacted maxillary canines. *Semin Orthod* 1998;4:87-98.
9. Kokich VG. Surgical and orthodontic management of impacted maxillary canines. *Am J Orthod Dentofacial Orthop* 2004;126:278-83.
10. Liu DG, Zhang WL, Zhang ZY, Wu YT, Ma XC. Localization of impacted maxillary canines and observation of adjacent incisor resorption with cone-beam computed tomography. *Oral Surg Oral Med Oral Pathol Oral Radiol Endod* 2008;105:91-8.
11. Ericson S, Kuroi PJ. Resorption of incisors after ectopic eruption of maxillary canines: A CT study. *Angle Orthod* 2000;70:415-23.
12. Kau CH, Pan P, Gallerano RL, English JD. A novel 3D classification system for canine impactions: The KPG index. *Int J Med Robot* 2009;5:291-6.
13. Haney E, Gansky SA, Lee JS, Johnson E, Maki K, Miller AJ, *et al.* Comparative analysis of traditional radiographs and cone-beam computed tomography volumetric images in the diagnosis and treatment planning of maxillary impacted canines. *Am J Orthod Dentofacial Orthop* 2010;137:590-7.
14. Tantanapornkul W, Okouchi K, Fujiwara Y, Yamashiro M, Maruoka Y, Ohbayashi N, *et al.* A comparative study of cone-beam computed tomography and conventional panoramic radiography in assessing the topographic relationship between the mandibular canal and impacted third molars. *Oral Surg Oral Med Oral Pathol Oral Radiol Endod* 2007;103:253-9.
15. Kau CH, Richmond S, Palomo JM, Hans MG. Three-dimensional cone beam computerized tomography in orthodontics. *J Orthod* 2005;32:282-93.
16. Katheria BC, Kau CH, Tate R, Chen JW, English J, Bouquot J. Effectiveness of impacted and supernumerary tooth diagnosis from traditional radiography versus cone beam computed tomography. *Pediatr Dent* 2010;32:304-9.

### Access this article online

#### Quick Response Code:



#### Website:

[www.eurjdent.com](http://www.eurjdent.com)

Source of Support: Nil.

Conflict of Interest: None declared