

Isolated oligodontia in monozygotic twins

Koray Halicioglu¹, Hakan Sahin², Bayram Corekci¹, Celal Irgin¹, Orcun Toptas³

¹Department of Orthodontics, Faculty of Dentistry, Abant Izzet Baysal University, Bolu, Turkiye,

²Department of Pediatric Dentistry, Faculty of Dentistry, Abant Izzet Baysal University, Bolu, Turkiye,

³Department of Oral and Maxillofacial Surgery, Faculty of Dentistry, Abant Izzet Baysal University, Bolu, Turkiye

Correspondence: Dr. Koray Halicioglu

Email: korayhalicioglu@hotmail.com

ABSTRACT

This case report defines a case of isolated oligodontia of 9 and 10 permanent teeth in 9-year-old monozygotic twin sisters and gives information about the possible genetic and environmental etiology, related dental anomalies and treatment options. The twins have a negative family history of hypodontia and oligodontia in their parents, as well as their paternal and maternal grandmothers and first cousins. No other dental anomalies could be detected in either of the twins. With the occurrence of similarly located tooth agenesis, except for one tooth, in monozygotic twins, one may consider the influence of genetic and/or environmental factors in their etiology. Hereditary relationships associated with oligodontia could help the clinicians to predict the possibility of its occurrence in other family members and in the next generations. However, clinicians should consider oligodontia when it is not hereditary.

Key words: Congenitally missing teeth, monozygotic twins, oligodontia, severe hypodontia, tooth agenesis

INTRODUCTION

The terms of tooth agenesis or hypodontia can be explained as the developmental absence of one or more teeth in the dentition,^[1] which is a frequent anomaly for a permanent rather than deciduous dentition.^[2] Third molars were found to be the most commonly missing teeth, followed by either lower second premolars or upper lateral incisors in the literature.^[3]

The incidence of developmentally missing teeth might range from the absence of one or few teeth (hypodontia) to the absence of several teeth (oligodontia or severe hypodontia), or the failure of all teeth to develop (anadontia). The definition of oligodontia, which can occur as an isolated (nonsyndrome) condition or as a part of a syndrome, is the agenesis of six or more teeth, excluding the third molars^[4] and it is commonly seen in the permanent dentition rather than the deciduous dentition.^[5]

Boruchov and Green^[6] stated that, "much has been written about the cause and incidence of hypodontia. There have been many reports about the percentage of the population affected by hypodontia. Currently, no one is sure about the cause of hypodontia and the extent to which genetic and/or environmental factors are involved."

Earlier studies reported patients with oligodontia^[7,8] and hypodontia,^[9,10] and these authors mentioned a genetic predisposition. The present study describes a case of isolated and non-hereditary oligodontia of 9 and 10 permanent teeth in 9-year-old monozygotic twin sisters. Based on our literature search, we found that isolated oligodontia has not yet been reported.

CASE REPORT

Female twin patients, 9 years of age, with a complaint about the eruption of permanent teeth were referred to our orthodontics clinic because of delayed tooth eruption and malocclusion.

How to cite this article: Halicioglu K, Sahin H, Corekci B, Irgin C, Toptas O. Isolated oligodontia in monozygotic twins. *Eur J Dent* 2013;7:111-4.

Copyright © 2013 Dental Investigations Society.

DOI: 10.4103/1305-7456.119087

Upon extra-oral examination, the twins had identical features [Figure 1a and b], their skin and hair appeared normal and their height and weight was within the normal limits. Upon intra-oral examination using panoramic radiographs, both were found to have a bilateral posterior open bite because of the infraocclusion of the posterior deciduous teeth. There were also morphologically orderly shaped crowns of the maxillary and mandibular permanent incisors as well as the first and second molars. The oral mucosa of both appeared normal and they had bad oral hygiene.

Twin I (AAY) revealed the agenesis of the permanent maxillary canine, maxillary and mandibular first premolar and second premolar teeth (13, 14, 15, 23,

24, 25, 34, 35, 44, 45) and retained deciduous maxillary and mandibular canine, first molar and second molar teeth (53, 54, 55, 63, 65, 73, 74, 75, 83, 84, 85), except an extracted maxillary first molar tooth (64) [Figures 2a, 3a, 4a and 5a].

Twin II (IYY) revealed the agenesis of the permanent maxillary canine, maxillary and mandibular first premolar and second premolar teeth (13, 14, 15, 23, 24, 25, 35, 44, 45), except the left mandibular first premolar tooth (34) and retained deciduous maxillary and mandibular canine, first molar and second molar teeth (53, 54, 55, 63, 64, 65, 73, 74, 75, 83, 84, 85) [Figures 2b, 3b, 4b and 5b].

The panoramic radiographs [Figure 5a and b] of both of the cases revealed that the root formation of the permanent maxillary and mandibular second molars and the mandibular canines was not complete and that

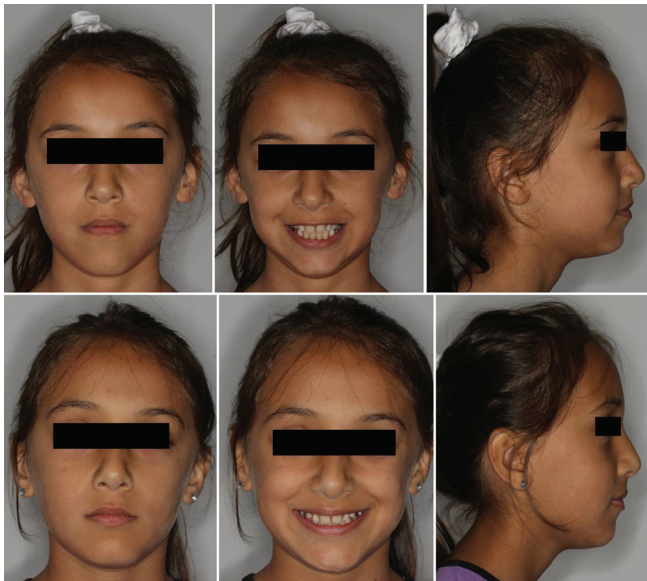

Figure 1: (a and b) Facial photographs of twins I and II showing identical features

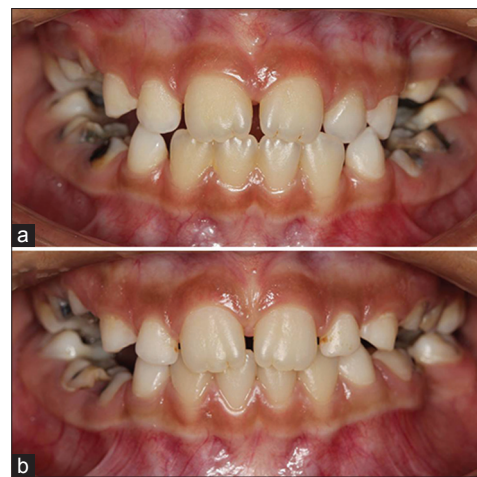

Figure 2: (a and b) Intraoral photograph showing frontal view of the dentition of twins I and II, respectively

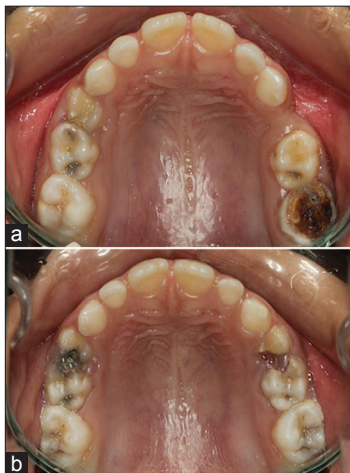


Figure 3: (a and b) Intraoral photograph showing occlusal view of the upper arch of twins I and II, respectively

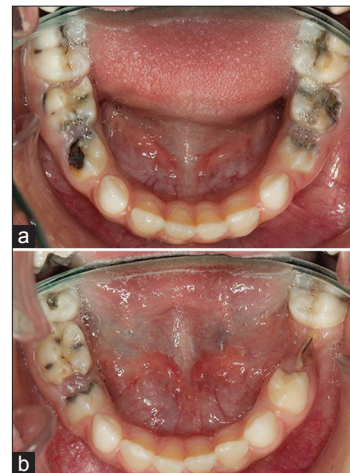


Figure 4: (a and b) Intraoral photograph showing occlusal view of the lower arch of twins I and II, respectively

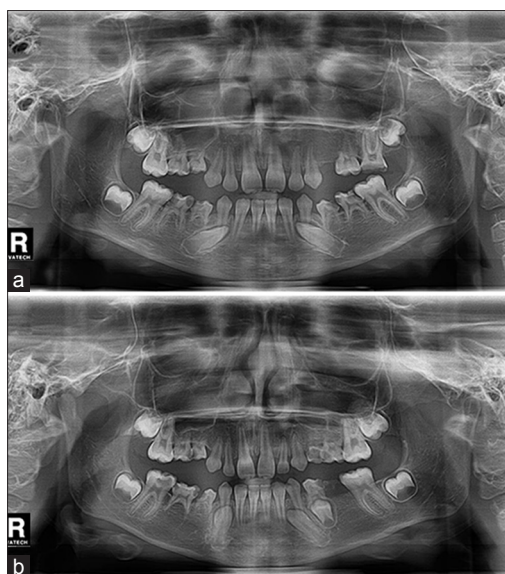


Figure 5: (a and b) Panoramic radiographs of twins I and II, respectively

the deciduous maxillary molars were infraoccluded. There was resorption of the roots and profound caries in the retained deciduous teeth.

The patients' parents, as well as the paternal and maternal relatives (grandmothers, grandfathers and cousins), had no history of missing teeth, except as a tooth extraction. In addition, the patients had no prenatal and natal histories and their mother was not exposed to radiation or drugs during pregnancy. Furthermore, no history of orofacial trauma or unusual childhood diseases was reported and no systemic disease or syndrome was determined.

Considering the history as well as the clinical and radiographic findings, a diagnosis of monozygotic twin sisters with nonsyndromic (isolated) oligodontia was determined.

Both twins were enrolled in orthodontic treatment after surgically removing the exhausted deciduous teeth and restoring the caries. Currently, the twins are under regular follow-up at our clinic and treatment will be instituted as and when required.

DISCUSSION

Twin studies give more valuable knowledge regarding the etiology of congenital abnormalities. Especially since the same genetic structure of monozygotic twins may only differ from one another due to environmental factors.^[6] The variable expressions of the hypodontia^[9,10] and oligodontia^[7,8] in monozygotic twins have been reported previously. Furthermore, in

our study, the monozygotic twins had the agenesis of 10 and 9 teeth (respectively) and their third molars were excluded, consistent with oligodontia. The similarities in the agenesis of the permanent teeth suggest the possibility of a genetic influence. Additionally, environmental factors may also play a role because minor differences in the dentitions of the twins were observed. Our patients had a negative family history of hypodontia or oligodontia and an associated syndrome was absent. This confirms the isolated and autosomal-recessive genetic etiology of hypodontia.

Many researchers have suggested a multifactorial etiology of oligodontia, combining multigenic and environmental influences.^[10-12] Developing teeth are influenced by endocrine, local and environmental factors such as radiotherapy, chemotherapy, jaw fractures, surgical procedures on the jaws, or the extraction of the preceding deciduous teeth.^[13,14] However, these environmental factors cannot be attributed to oligodontia in our patients.

Autosomally dominant inheritance with incomplete penetration and variable expressivity of hypodontia seems to be the majority in cases of familial hypodontia and our patients may have an autosomally recessive type of inheritance. The reason for autosomal oligodontia in families was found in mutations in the transcription factors *MSX1* and *PAX9* genes. If oligodontia is associated with the features of *MSX1*, the maxillary first premolars are absent, but if it is associated with the *PAX9*, it shows maxillary and mandibular second molars as being absent.^[4,15] Our cases showed the absence of maxillary premolars.

Hattab and Angmar-Månsson^[16] reported oligodontia in two sisters with polycystic ovarian syndrome. However, our patients were not evaluated for polycystic ovarian syndrome as they were younger and had not attained menarche. Lammi *et al.*^[17] reported a family with dominantly transmitted oligodontia and colorectal polyps, carrying a germline R656X mutation in the *AXIN2*. Thus, patients with oligodontia should be examined for colorectal neoplasia.

Patients with hypodontia and/or oligodontia show a disposition for delayed tooth formation.^[18-20] In our patients, the delayed root formation of permanent teeth was not assessed due to the high degree of tooth agenesis. Also, oligodontia might be associated with other dental anomalies, such as morphologic alterations and variations of tooth size.^[21] In our patients, such anomalies and variations were not observed.

Oligodontia affects the permanent dentition rather than the deciduous dentition,^[5] and females show a higher incidence of hypodontia than males,^[3] which is concordant with our present case report.

Because oligodontia causes poor esthetics, functional problems and malocclusion, a multidisciplinary treatment approach is needed for the oligodontic patient. In this way, the treatment approach contains the improvement of esthetics, function and oral-facial health and achieves stable outcomes. The age of the patient is the most important factor during treatment planning. In addition, the number and situation of the retained deciduous teeth, agenesis teeth and carious teeth and the condition of the periodontal tissue and occlusion should also be considered.^[21]

In our reported case, the twins were enrolled for orthodontic treatment after surgically removing the exhausted deciduous teeth and the restoration of the caries. Prosthetic rehabilitation of patients with oligodontia is likely to become more comprehensive. Our patients are under regular follow-up at our clinic and treatment will be instituted as and when required. Although pre-restorative orthodontics treatment was planned in these patients, we considered restoration with a removable partial denture and an implant retaining prosthesis as the treatment options.

CONCLUSION

The etiology of monozygotic twins may be explained by the influence of genetic and/or environmental factors because of the occurrence of similarly located tooth agenesis. Hereditarily related oligodontia could give an opportunity to estimate the possibility of its occurrence for clinicians. However, clinicians should consider oligodontia when it is not hereditary.

REFERENCES

1. McKusick VA. Mendelian Inheritance in Man. 11th ed. Baltimore: The Johns Hopkins University Press; 1994.
2. Graber LW. Congenital absence of teeth: A review with emphasis on inheritance patterns. J Am Dent Assoc 1978;96:266-75.

3. Polder BJ, Van't Hof MA, Van der Linden FP, Kuijpers-Jagtman AM. A meta-analysis of the prevalence of dental agenesis of permanent teeth. Community Dent Oral Epidemiol 2004;32:217-26.
4. Thesleff I. Genetic basis of tooth development and dental defects. Acta Odontol Scand 2000;58:191-4.
5. Gorlin RJ. Syndromes of the Head and Neck. New York: Oxford University Press; 2001.
6. Boruchov MJ, Green LJ. Hypodontia in human twins and families. Am J Orthod 1971;60:165-74.
7. Zengin AZ, Sumer AP, Karaarslan E. Impacted primary tooth and tooth agenesis: A case report of monozygotic twins. Eur J Dent 2008;2:299-302.
8. Gadda RB, Pai KM, Sholapurkar AA. Non-syndromic oligodontia in permanent dentition of monozygotic twins: Report of a rare case. J Contemp Dent Pract 2010;11:071-7.
9. Nik-Hussein NN, Salcedo AH. Double teeth with hypodontia in identical twins. ASDC J Dent Child 1987;54:179-81.
10. Kindelan JD, Rysiecki G, Childs WP. Hypodontia: Genotype or environment? A case report of monozygotic twins. Br J Orthod 1998;25:175-8.
11. Vastardis H. The genetics of human tooth agenesis: New discoveries for understanding dental anomalies. Am J Orthod Dentofacial Orthop 2000;117:650-6.
12. Matalova E, Fleischmannova J, Sharpe PT, Tucker AS. Tooth agenesis: From molecular genetics to molecular dentistry. J Dent Res 2008;87:617-23.
13. Cakur B, Dagistan S, Miloglu O, Bilge M. Nonsyndromic oligodontia in permanent dentition: Three siblings. Internet J Dent Sci 2006;3:2.
14. Güngörmüş M, Yolcu U, Aras MH, Halicioğlu K. Simultaneous occurrence of compound odontoma and arrested root formation as developmental disturbances after maxillofacial trauma: A case report. Med Oral Patol Oral Cir Bucal 2010;15:e398-400.
15. Kim JW, Simmer JP, Lin BP, Hu JC, Novel MSX1 frameshift causes autosomal-dominant oligodontia. J Dent Res 2006;85:267-71.
16. Hattab FN, Angmar-Månsson B. Oligodontia of the permanent dentition in two sisters with polycystic ovarian syndrome: Case reports. Oral Surg Oral Med Oral Pathol Oral Radiol Endod 1997;84:368-71.
17. Lammi L, Arte S, Somer M, Jarvinen H, Lahermo P, Thesleff I, *et al.* Mutations in AXIN2 cause familial tooth agenesis and predispose to colorectal cancer. Am J Hum Genet 2004;74:1043-50.
18. Schalk van der Weide Y, Prah Andersen B, Bosman F. Tooth formation in patients with oligodontia. Angle Orthod 1993;63:31-7.
19. Halicioğlu K. Dental age in patients with impacted maxillary canines related to the position of the impacted teeth. Eur J Orthod 2012;34:394.
20. Tuñç EŞ, Bayrak S, Koyutürk AE. Dental development in children with mild-to-moderate hypodontia. Am J Orthod Dentofacial Orthop 2011;139:334-8.
21. Akkaya N, Kiremitçi A, Kansu O. Treatment of a patient with oligodontia: A case report. J Contemp Dent Pract 2008;9:121-7.

| Access this article online | |
|---|---|
| Quick Response Code:  | Website: www.eurjdent.com |
| Source of Support: Nil. Conflict of Interest: None declared | |