

Repair of a fractured implant overdenture gold bar: A clinical and laboratory technique report

Fahim Vohra¹, Amani Al Fawaz¹

Correspondence: Dr. Fahim Ahmed Vohra
Email: fahimvohra@yahoo.com

¹Department of Prosthetic Science, SDS, College of Dentistry, King Saud University, Kingdom of Saudi Arabia

ABSTRACT

This clinical report explains a convenient, efficient, yet effective alternative for management of fractured substructure cast bars for implant-retained overdentures. The technique allows the fracture to be repaired at low cost and short time without remaking the substructure and the denture and further allowing the patient to keep their denture. The report sketches the clinical and laboratory procedures involved in the repair.

Key words: Dolder bar, implant-supported overdenture, soldering

INTRODUCTION

Improved predictability and better success rates^[1] for osseointegrated implant-retained restorations have resulted in acceptance^[2] of implant-retained overdentures (IOD) to facilitate improvement in denture support, stability, and retention.^[3-5] McGill consensus (McGill University, Montreal) stated in light of evidence that 2-implant retained overdenture should become the standard of care for treatment of the edentulous mandibles.^[6] Studies have evidently revealed improved masticatory efficiency, quality of life, patient satisfaction, implant and prosthesis survival rates for IOD's compared to conventional complete dentures.^[7-10] However, implant overdentures, particularly in the maxilla, require greater maintenance,^[11] and stomatitis,^[12] mechanical fractures,^[13] clip loosening, clip fracture and replacement,^[14] relining and rebasing^[15] are the common complications reported. Fractured substructure for overdenture prosthesis conventionally indicates remaking of the retainer and the prosthesis, needing three to four patient visits, additional financial cost and also leaving the patient without a functional and esthetic prosthesis. This short communication will present the clinical and laboratory steps for

an efficient yet accurate procedure for a maxillary implant overdenture fractured bar repair avoiding the prosthesis and the metal substructure to be remade.

CASE REPORT

A 59-year-old female presented at the prosthodontic department as an emergency. Patient reported looseness of the maxillary implant-retained tissue-supported overdenture (IOD) from four weeks and increased mobility specifically on chewing at the left side from last 72 hours. The removable maxillary prosthesis and the bar retainer have been in function from the last 50 months; during this period, the patient was seen for review of prosthesis retainer at 1, 6, 12, and 18 months postoperative. During the service of prosthesis, patient has had complains of repeated screw loosening and soft tissue inflammation and growth around the distal left maxillary implant.

The patient was wearing a loose implant-retained maxillary overdenture on a gold bar retainer splinting four implants, the bar retainer had no cantilever extensions. The implants (Straumann®, 4.1Ø, RN Standard) were positioned at tooth number 15, 13, 21, 24 in the maxilla and connected by three gold

How to cite this article: Vohra F, Al Fawaz A. Repair of a fractured implant overdenture gold bar: A clinical and laboratory technique report. *Eur J Dent* 2013;7:382-6.

Copyright © 2013 Dental Investigations Society.

DOI: 10.4103/1305-7456.115428

U-shaped Dolder bars (H 3.0 mm, regular, Elitor® Straumann®) soldered to gold copings, made to fit passively. The framework-reinforced overdenture prosthesis incorporated three corresponding riders/clips (Straumann®, Dolder matrix, regular) acting as matrices on the intaglio surface providing attachments to the bar retainer [Figure 1]. It was clear that the gold bar fractured mesial to the gold coping at implant 24 but was not displaced [Figure 2]. The maxillary implant overdenture prosthesis was found to be satisfactory with regards to fit, occlusion, aesthetics, and phonetics, however, was unstable due to the fracture in the supporting gold bar. The treatment plan suggested to the patient included the fabrication of a new bar retainer and maxillary IOD prosthesis. However, due to the patient's time restraint and after discussion of benefits and risks, an informed consent was developed and the decision was taken to retain the prosthesis and repair the gold bar using gold solder.

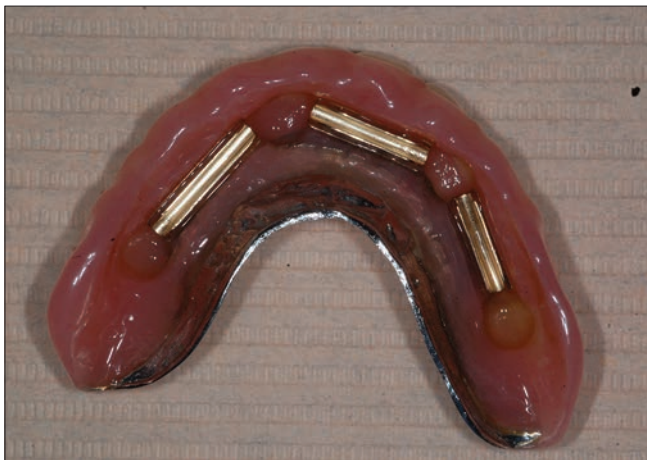

Figure 1: Intaglio surface of the metal framework reinforced maxillary implant overdenture with reduced palatal coverage showing three metal riders

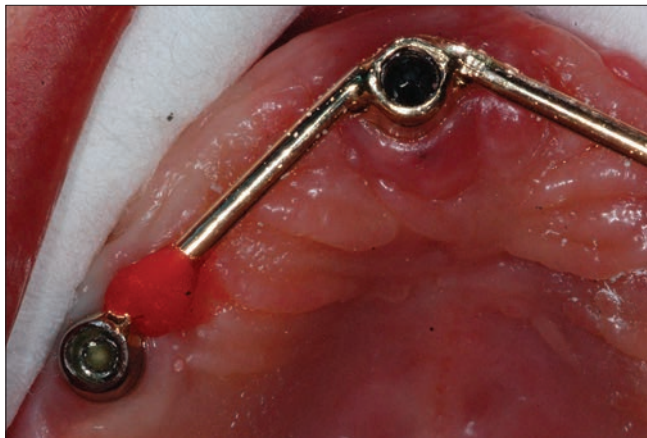


Figure 3: Intra-oral splinting of the fracture ends using chemical cured pattern resin (Duralay, Reliance Dental Mfg. Co.)

REPAIR PROCEDURE

Following were the procedural steps in the repair of the fractured implant overdenture gold bar:

1. Complete seating of the gold copings on the implant platform was verified using periapical radiographs after the screws were torqued at 30 Ncm. The fracture on the Dolder bar, which was approximately 4 mm mesial to the coping on the most distal left maxillary implant, was found to be undisplaced [Figure 2].
2. Intra-orally, the fracture was initially stabilized using sticky wax (Sticky wax, Ainsworth Dental Company, Marrickville, Australia) and fixated using chemically cured inlay pattern resin (Duralay, Reliance Dental Mfg. Co, Worth, Illinois, USA). Employing the bead-on method, both the ends of the fracture line and few millimeters beyond was covered by the pattern resin [Figure 3].
3. Once the pattern resin had completely polymerized (5-7 minutes), the Dolder bar retainer was unscrewed and removed from the mouth using a SCS screw driver (Straumann, Basel, Switzerland) [Figures 4 and 5]. Regular neck healing abutments (Straumann 4.5Ø, 2 mm height)

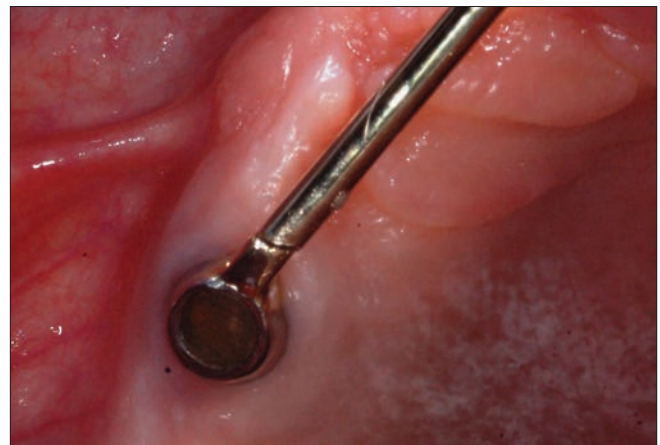


Figure 2: Gold bar fracture mesial to implant coping at tooth position no. 24, near the solder joint



Figure 4: Splinted gold bar and coping assembly removed from the mouth to undertake laboratory procedure

were placed on the top of implants to prevent the soft tissues from collapse.

4. Four implant analogs (Straumann RN syn Octa) were secured to the gold copings [Figure 6] on the overdenture Dolder bar, and the assembly was mounted in dental stone (Vel-Mix, Kerr Co, Orange, CA, USA) in the laboratory [Figure 7] to provide positioning stability.
5. Next, the complete assembly was embedded in the solder investment material (Heravest L, Heraeus Kulzer, Germany) excluding the resin-covered portion [Figure 8].
6. The pattern resin was removed and cleaned. It was ensured that the solder gap (0.05-0.2 mm, Heraeus Kulzer, Germany) and the edge surface dimension (Blasted with 50m Corundum, Al_2O_3 , Heraeus Kulzer, Germany) were optimally prepared and primed by application of a soldering flux (Hera UL 99- Universal flux, Heraeus Kulzer, Germany) prior to any heat treatment.
7. Flame soldering (gas/oxygen flame) was performed using precious metal solder strip (Hera solder 800, Heraeus Kulzer, Germany) at an elevated temperature (850-950°C).

8. After bench cooling, the assembly is divested [Figure 9] using sandblasting and the gold solder was adjusted using coarse rubber disc and polishing was completed using a burlew/gold lustre blue disc (Shofu Dental Corp, St Marcos, CA, USA) [Figure 10].
9. The repaired bar and coping assembly was removed from the implant analogs and placed intra-orally after adequate disinfection and were found to connect passively on all four implants.
10. The maxillary implant overdenture prosthesis was stable on fit, and the patient was delighted with the excellent result. The repaired Dolder bar/gold coping assembly was fitted the same day, and the patient was able to wear a stable overdenture within just four hours.

DISCUSSION

In the present report, a simple, efficient, yet accurate technique for the repair of fractured bar retainer for a maxillary implant-retained overdenture is described. These fractures can be

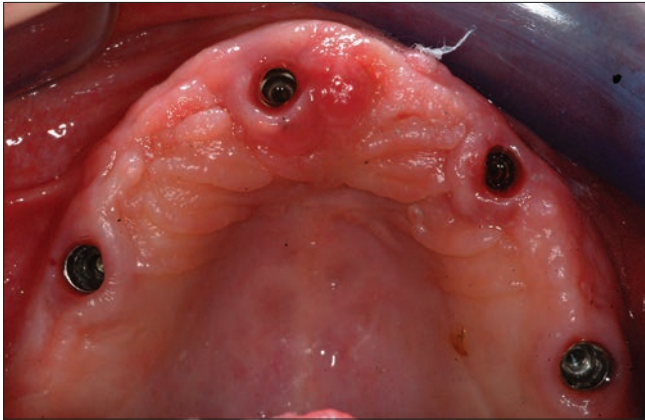

Figure 5: Intra-oral occlusal view of the maxilla after removal of the gold bar retainer



Figure 7: The gold bar retainer and implant analog assembly mounted in dental stone for positioning stability of fractured segments



Figure 6: Compatible implant analogs (replica) secured to the gold copings on the bar retainer prior to mounting

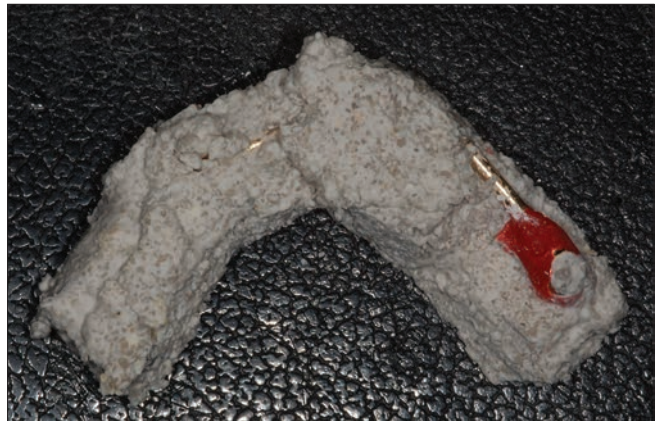

Figure 8: The mounted assembly of gold bar is invested (embedded in investment material), except the resin covered area around the fracture line for performing soldering



Figure 9: The soldered and divested gold bar assembly, prior to finishing and polishing

the outcome of inherent weakness of the metal alloy, inadequate dimensions and design of the bar retainer, magnitude of occlusal forces and the antagonist^[16] (fixed, removable prosthesis or natural dentition), inferior solder joints,^[17] and fatigue failure.^[18] The fracture was located at the solder joint mesial to the left distal maxillary implant coping. Repeated complain of loose bar retainer and soft tissue inflammation indicates incomplete seating of the coping on the implant platform,^[19,20] i.e., a non-passive implant coping connection. Also, a diagonal discrepancy in approximation of the fracture line was observed, reinforcing the potential for non-passive fit. The problem was compounded further by comparatively apical placement of left distal maxillary implant. The continuous stress at the implant/coping connection due to non-passive fit, apical position of implant, high occlusal forces, and inferior solder quality resulted in fatigue failure.

Initially, the patient was presented with an option of remake of both the bar retainer and the prosthesis, this would employ the conventional technique increasing the chairside time and overall cost. The alternative repair option involved re-soldering, which in order to give optimum results needs controlling several factors^[21] (solder method, surface preparation, levels of porosity, filler diffusion, and voids as crack initiators). On the contrary, the repair technique allowed for same day fit of the bar retainer and prosthesis, avoided any impressions, resulted in passively fitting retainer substructure (as splinted intra-orally and picked-up), current prosthesis was kept and used, and saved time and cost.

The passively fitting substructure, which was fabricated, resulted in reducing the risk of future

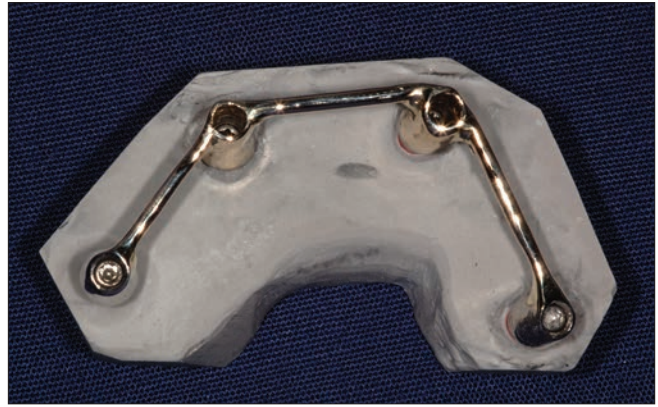

Figure 10: Repaired, finished, and polished gold bar retainer assembly, ready for intra-oral fit

fracture as it alleviated the consistent stress on both the solder joint and implant/coping interface. It further decreased the possibility of a loose retaining screw and incidence of soft tissue inflammation at the implant site.

CONCLUSION

In summary, the clinical and laboratory technique illustrates a simple, precise, and cost-effective way of repairing a fractured implant overdenture bar retainer on the same day using a gold solder and allowing the patient to keep the prosthesis during the repair. Furthermore, the procedure fabricated a passively fitting prosthesis reducing the stress in the overall implant overdenture-substructure assembly.

REFERENCES

1. Pjetursson BE, Bragger U, Lang NP, Zwahlen M. Comparison of survival and complication rates of tooth supported fixed dental prosthesis and implant supported FDP's and single crowns. *Clin Oral Implants Res* 2007;18:97-113.
2. Stellingsma C, Vissink A, Meijer HJ, Kuiper C, Raghoobar GM. Implantology and theseverely resorbed edentulous mandible. *Crit Rev Oral Biol Med* 2004;15:240-8.
3. Jemt T, Lindquist L, Hedegard B. Changes in chewing patterns of patients with complete dentures after placement of osseointegrated implants in the mandible. *J Prosthet Dent* 1985;53:578-83.
4. Davis DM. Implant-stabilized over dentures. *Dent Update* 1997;24:106-9.
5. Bergendal T, Engquist B: Implant-supported overdentures: A longitudinal prospective study. *Int J Oral Maxillofac Implants* 1998;13:253-62.
6. The McGill consensus statement on overdentures. *Int J Prosthodont* 2002;15:413-4.
7. Stellingsma K, Slagter AP, Stegenga B, Raghoobar GM, Meijer HJ. Masticatory function in patients with an extremely resorbed mandible restored with mandibular implant-retained overdentures: Comparison of three types of treatment protocols. *J Oral Rehab* 2005;32:403-10.
8. Feine JS, Dufresne E, Boudrias P, Lund JP. Outcome assessment of implant-supported prosthesis. *J Prosthet Dent* 1998;79:575-9.
9. Fueki K, Kimoto K, Ogawa T, Garrett NR. Effect of implant-supported or retained dentures on masticatory performance: A systematic review. *J Prosthet Dent* 2007;98:470-7.
10. Attard NJ, Zarb GA. Long-term treatment outcomes in edentulous

- patients with implant overdentures: The Toronto study. *Int J Prosthodont* 2004;17:425-33.
11. Widbom C, Soderfeldt B, Kronstrom M. A retrospective evaluation of treatments with implant-supported maxillary overdentures. *Clin Implant Dent Relat Res* 2005;7:166-72.
 12. Ekfeldt A, Johansson LA, Isaksson S. Implant-supported overdenture therapy: A retrospective study. *Int J Prosthodont* 1997;10:366-74.
 13. Watson RM, Jemt T, Chai J, Harnett J, Heath MR, Hutton JE, *et al.* Prosthodontic treatment, patient response, and the need for maintenance of complete implant-supported overdentures: An appraisal of 5 years of prospective study. *Int J Prosthodont* 1997;10:345-54.
 14. Allen PF, McMillan AS, Smith DG. Complications and maintenance requirements of implant-supported prosthesis provided in a UK dental hospital. *Br Dent J* 1997;182:298-302.
 15. Jemt T, Book K, Linden B, Urde G. Failures and complications in 92 consecutively inserted overdentures supported by Branemark implants in severely resorbed edentulous maxillae: A study from prosthetic treatment to first annual check-up. *Int J Oral Maxillofac Implants* 1992;7:162-7.
 16. Goodacre CJ, Kan JY, Rungcharassaeng K. Clinical complications of osseointegrated implants. *J Prosthet Dent* 1999;81:537-52.
 17. Jennings KJ, Lilly P. Bar-retained overdentures for implants-technical aspects. *J Prosthet Dent* 1992;68:380-4.
 18. Misch C. *Dental implant prosthetics*. St. Louis: Elsevier; 2004. p. 319-20.
 19. Salcetti JM, Moriarty JD, Cooper LF, Smith FW, Collins JG, Socransky SS, *et al.* The Clinical, Microbial and Host response characteristics of the failing implant. *Int J Oral Max Implants* 1997;12:32-42.
 20. Kreissl ME, Gerds T, Muehe R, Heydecke G, Strub JR. Technical complications of implant-supported fixed partial dentures in partially edentulous cases after an average observation period of 5 years. *Clin Oral Implants Res* 2007;18:720-6.
 21. Waddell JN, Payne AG, Swain MV. Physical and metallurgical considerations of failures of soldered bars in bar attachment systems for implant overdentures: A review of the literature. *J Prosthet Dent* 2006;96:283-8.

Access this article online	
<p>Quick Response Code:</p> 	<p>Website: www.eurjdent.com</p>
<p>Source of Support: The clinical case and write-up is self supported by the author. Conflict of Interest: None declared</p>	