

Galvanic gold plating for fixed dental prosthesis

Tuncer Burak Ozcelik¹, Burak Yilmaz²

Correspondence: Dr. Burak Yilmaz
Email: yilmaz.16@osu.edu

¹Department of Prosthodontics, Faculty of Dentistry, Baskent University, Ankara, Turkiye, ²Division of Restorative and Prosthetic Dentistry, College of Dentistry, The Ohio State University, Columbus, Ohio, USA

ABSTRACT

Metal ceramic partial fixed dental prostheses have been commonly used for the replacement of missing teeth for many years. Because of an increase in the price of gold, base metal alloys have been the choice of alloy for the fabrication of metal ceramic restorations in many dental clinics. Some major disadvantages of base metals are their corrosion and the dark coloration they may cause at the crown margins. This article describes a galvanic gold-plating technique, which is used to minimize corrosion and improve the esthetics of metal ceramic restorations fabricated with Cr-Co base metal alloys. This technique involves the deposition of a 6 µm to 8 µm 24 K gold layer directly onto the Cr-Co cast prosthesis framework. The technique improves metal surface properties, making them more biocompatible and usable, however, requires additional equipment and experienced laboratory technicians. Clinical studies should be performed to corroborate the long term success of this technique.

Key words: Base metal, fixed dental prosthesis, gold plating

INTRODUCTION

Gold and gold alloys, whose primary advantages are their resistance to corrosion and tarnishing and their biocompatibility, have long been used to fabricate dental prostheses. Despite these advantages, base metal alloys such as nickel-chromium (Ni-Cr) and cobalt-chromium (Co-Cr) are commonly used instead of high noble and noble alloys because of cost. In addition, although base metal alloys have some advantages over high noble or noble alloys, such as high hardness (exceeds 400 kg/mm² if carbon is present), low density, high elastic moduli, high tensile strength, and the possibility of electrochemical etching for resin bonding, they can corrode in accordance with their elemental composition.^[1-3]

All dental alloys have a tendency to corrode in under intraoral conditions because of exposure to substances such as saliva, food, and beverages. High noble and noble alloys are biocompatible because of

their resistance to oxidation and corrosion, while the corrosion resistance of base metal alloys depends on the integrity of their passive oxide layer, which may be destroyed mechanically and chemically by acidic changes. Typically, the corrosion process takes place locally, but over time, this local process transforms to a gap corrosion, which causes several problems, such as gray discoloration at the margins of the fixed restorations close to the gingival sulcus.^[1,4]

Recently, manufacturers have started adding some noble alloys to the composition of base metal alloys to improve their biocompatibility and minimize corrosion while still keeping their cost reasonably low.^[5] Another method, which is not commonly used, is the gold-hard-plating (GHP) of base metal alloys, also known as galvanic gold coating, layering application or gold plating-electrodeposition of gold.^[4,6]

Gold is a popular material, especially for jewelry and industry. The problem is that solid gold is expensive. To get the look of gold without the cost, a technique

How to cite this article: Ozcelik TB, Yilmaz B. Galvanic gold plating for fixed dental prosthesis. Eur J Dent 2013;7:373-6.

Copyright © 2013 Dental Investigations Society.

DOI: 10.4103/1305-7456.115426

called gold plating was developed. Gold plating has many applications, including uses in jewelry, scientific experiments, electronics, industry, and dentistry. It is a technique that has been around for centuries and continues because it is effective. The underlying metal is made negatively charged through chemical baths and/or electricity. Once the metal has a charge, it will seek to balance its charge. This is done by gold application. The two metals share electrons, which creates the bond. Gold does not oxidize when exposed to air, so its electrical conductivity won't diminish over time. This makes it ideal for electroplating. Gold plating acts as an anti-corrosive coating to the material to which it is applied. When bonded with cobalt, the result is a wear-resistant material.^[6]

The GHP technique used in dentistry involves the depositions of a 6 µm to 8 µm 24 K gold layer directly onto the Cr-Co cast prosthesis framework. This method prevents oxidation of the metal surface, alters its conductivity and resistance, provides a surface seal, reduces surface hardness, and improves color. The technique improves metal surface properties, making them more biocompatible and usable. According to the manufacturers' instructions, the GHP technique is used primarily to coat Cr-Co alloys for removable dental prosthesis frameworks.^[4]

Rogers^[7] studied Cr-Co alloy gold plating and reported of advantages of clasps and frameworks of removable partial dentures. It was also reported that the strength of the gold plating is determined by the hardness and thickness of the gold deposition on the surface.

In addition, electroplating of gold was used to enhance porcelain to metal bond strength^[8] and to minimize the discoloration of enamel, which is frequently associated with perforated and etched-metal resin-bonded retainers alike. Reflected light through the tooth causes gray or blue incisal discoloration, compromising esthetics.^[9]

This article describes the use of the GHP technique to gold-coat Cr-Co alloy used for the fabrication of a metal ceramic restoration (MCR) fabricated between mandibular right second premolar and second molar. The use of such a technique has not been reported for fixed restorations in the literature. The aim of the use of this technique for fixed partial dentures is to minimize gray discoloration at the margins of the restorations close to the gingival sulcus and enhance the esthetics.

TECHNIQUE

1. Fabricate the MCR with Cr-Co alloy (Heraenium P, Heraeus Kulzer GmbH, Hanau, Germany); finalize the clinical and laboratory procedures^[3] (glaze the porcelain and polish the metal) [Figure 1].
2. Airborne-particle abrade (Basic Classic; Renfert GmbH, Hilzingen, Germany) the intaglio surface with 110 µm aluminum oxide, when this surface is to be coated.
3. Clean the restoration in an ultrasonic cleaner (Emmevi SpA, Badia Polesine, Italy) and then with a steam cleaner (VAP 6-A; Emmevi SpA, Badia Polesine, Italy). Make sure that no debris is left on the restoration surfaces.
4. Attach contact ligature wire (0.25 mm) to the metal surface of the MCR to be gold-plated. Ensure all surfaces to be gold-plated have electric contact [Figure 2].
5. Use a ligature wire (0.25 mm) attached to the surfaces to be coated to hang and stabilize the MCR on the hanging device (Gramm technic GmbH, Ditzingen, Germany). Stabilize the MCR horizontally with the wire so that the intaglio is placed vertically and that gas bubbles will not be trapped inside the framework.
6. Hang the hanging device (Gramm technic GmbH, Ditzingen, Germany) in the gauging tool (Gramm technic GmbH, Ditzingen, Germany) to verify correct distance to the anode [Figure 3].
7. Use the contact check (Gramm technic GmbH, Ditzingen, Germany) to verify if all metal surfaces of the MCR are properly connected with ligature wire (0.25 mm) [Figure 4].
8. Use galvano-wax (Gramm technic GmbH, Ditzingen, Germany) or insulation lacquer (Protection lacquer, Gramm technic GmbH, Ditzingen, Germany) to isolate, and protect the surfaces which are not going to be coated with the GHP method [Figure 5].
9. Connect the MCR to the large plating head (Gramm technic GmbH, Ditzingen, Germany) with the hanging device (Gramm technic GmbH, Ditzingen, Germany).
10. Determine the amount of gold solution (Gramm technic GmbH, Ditzingen, Germany) required to gold-plate the surfaces, taking the manufacturer recommendations into consideration [Figure 6].
11. Perform the GHP procedures in the electrolysis device following the manufacturer's instructions (Gammat Optimo 2, Gramm technic GmbH, Ditzingen, Germany).

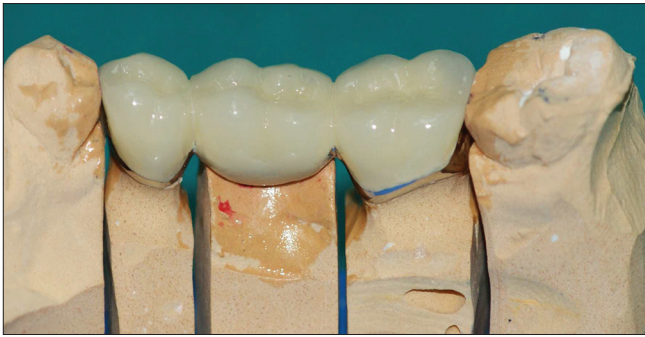

Figure 1: Definitive metal ceramic restoration



Figure 3: Measurement of distance between plate and restoration attached to hanging device with gauging tool

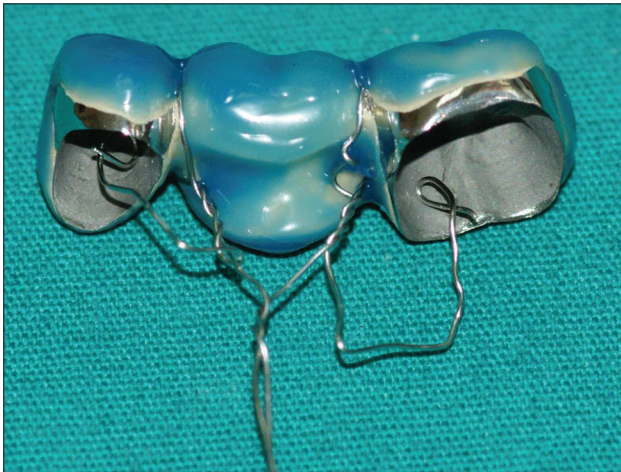


Figure 5: Restoration surfaces isolated with Galvano wax

DISCUSSION

There have been several studies reporting the long-term survival rates and success of MCRs. These reported restorations were mostly fabricated with noble alloys with the addition of base metal alloys for oxidation. Corrosion and the release of metal ions

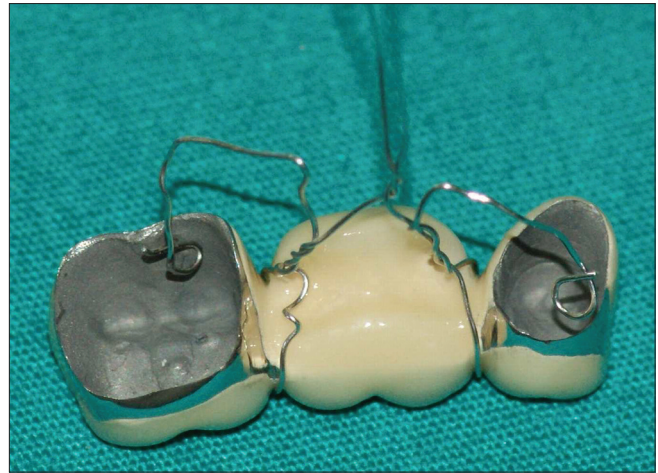


Figure 2: The ligature wire connections made on restoration. Note intaglio surfaces of the restoration are facing upwards to prevent trapping air bubbles



Figure 4: Evaluation of electrical contacts with contact check

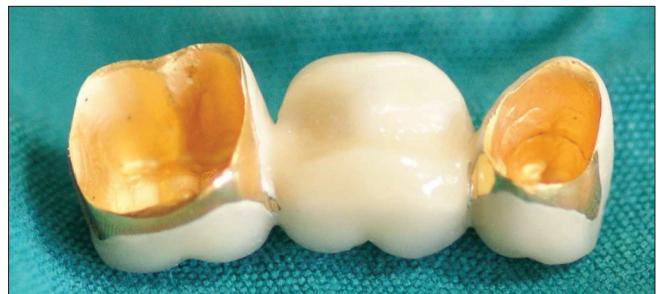

Figure 6: Restoration after gold-hard-plating

over time might have been responsible for reported discoloration and gingival problems.^[10-13]

This modified GHP technique for MCRs may minimize corrosion of base metals and the concomitant gray discoloration of the soft tissues. This technique can be modified in relation to the site to be coated. The outer, intaglio surfaces, as well as only metal bands of the MCRs can be coated with gold.

Livaditis and Tate investigated the effect of Gold-plating on cementation and esthetics of adhesive bridges. They recommended Gold-plating technique as a viable solution for reducing the discoloration problem that results from the framework in etched-metal resin-bonded prostheses.^[9]

It has been observed that the number of clinical studies related with long-term success of Gold-plating technique is limited. According to Rogers,^[7] the durability of the plating depends upon the hardness of the gold deposited and its thickness. The thickness of gold required clinically should be assessed. A thickness of up to 0.0005 inch when applied to castings does not appear to have any effect on their fit. Also, it was reported that Gold-plating technique is suitable for gold-plating cobalt-chromium castings and other chrome-containing alloys by surface activation.^[7]

Disadvantages of the technique include additional equipment, need for experienced laboratory technicians, cost and the need for future research for long term predictability of the technique. In addition, the long term efficacy of this technique should be established with clinical studies.

REFERENCES

1. Anusavice KJ. Philips Science of dental materials. 10th ed. Philadelphia: W.B. Saunders; 1996. p. 56-71, 580-620.
2. Wataha JC. Alloys for prosthodontic restorations. J Prosthet Dent 2002;87:351-633.
3. Rosenstiel SF, Land MF, Fujimoto J. Contemporary fixed prosthodontics. 4th ed. St Louis: Mosby Publisher; 2006. p. 589-615, 740-73.
4. Wirz J, Hoffmann A. Electroforming in restorative dentistry new dimensions in biologically based prostheses. Berlin: Quintessence Publishing Co., Inc., 2000. p. 13-42, 381-5.
5. Sarantopoulos DM, Beck KA, Holsen R, Berzins DW. Corrosion of CoCr and NiCr dental alloys alloyed with palladium. J Prosthet Dent 2011;105:35-43.
6. Mordechay Schlesinger and Milan Paunovic. Modern Electroplating. 5th ed. New York: John Wiley and Sons, Inc., 2010. p. 115-29.
7. Rogers OW. Gold-plating of cobalt-chromium. Aust Dent J 1969;14:79-81.
8. Daftary F, Donovan T. Effect of electrodeposition of gold on porcelain-to-metal bond strength. J Prosthet Dent 1987;57:41-6.
9. Livaditis GJ, Tate DL. Gold-plating etched-metal surfaces of resin-bonded retainers. J Prosthet Dent 1988;59:153-8.
10. Reitemeier B, Hansel K, Kastner C, Walter MH. Metal ceramic failure in noble metal crowns: 7-year results of a prospective clinical trial in private practices. Int J Prosthodont 2006;19:397-9.
11. Walton TR. A 10-year longitudinal study of fixed prosthodontics: Clinical characteristics and outcome of single-unit metalceramic crowns. Int J Prosthodont 1999;12:519-26.
12. Napankangas R, Raustia A. Twenty-year follow-up of metalceramic single crowns: A retrospective study. Int J Prosthodont 2008;21:307-11.
13. Reitemeier B, Hansel K, Walter MH, Kastner C, Toutenburg H. Effect of posterior crown margin placement on gingival health. J Prosthet Dent 2002;87:167-72.

Access this article online

Quick Response Code:



Website:

www.eurjdent.com

Source of Support: Nil.

Conflict of Interest: None declared