

# Effect of dietary boron on 5-fluorouracil induced oral mucositis in rats

Mutan Hamdi Aras<sup>1</sup>, Ufuk Sezer<sup>2</sup>, Suna Erkilic<sup>3</sup>, Tuncer Demir<sup>4</sup>, Seyda Nur Dagli<sup>4</sup>

**Correspondence:** Dr. Ufuk Sezer  
Email: ufuxezer@yahoo.com

<sup>1</sup>Department of Oral and Maxillofacial Surgery, Faculty of Dentistry, Gaziantep University, Gaziantep, Turkiye,  
<sup>2</sup>Department of Periodontology, Faculty of Dentistry, Gaziantep University, Gaziantep, Turkiye,  
<sup>3</sup>Department of Pathology, Faculty of Medicine, Gaziantep University, Gaziantep, Turkiye,  
<sup>4</sup>Department of Physiology, Faculty of Medicine, Gaziantep University, Gaziantep, Turkiye

## ABSTRACT

**Objective:** The aim of this study was to evaluate the effect of boron on 5-fluorouracil (5-FU)–induced oral mucositis in rats. **Materials and Methods:** Sixty-four male Wistar albino rats were injected with 5-FU on days 1 and 3. The right cheek pouch mucosa was scratched with the tip of an 18-G needle, dragged twice in a linear movement, on days 3 and 5. The animals were randomly divided into two groups of 32: boron group (BG) and control group (CG). Rats in the CG did not receive any treatment, whereas the others were fed boron (3 mg·kg<sup>-1</sup>·day<sup>-1</sup>) by gavage. The animals were sacrificed on day 3 (*n* = 8), 6 (*n* = 8), 9 (*n* = 8), and 12 (*n* = 8), and the cheek pouch was removed for histopathological analysis. **Results:** On day 3, both groups showed necrosis and active inflammation, but the inflammation was mild in CG and moderate in BG. On day 6, both BG and CG showed necrosis; in the CG, there was moderate inflammation, and in the BG, there was severe inflammation and granulation tissue around the necrotic area. On day 9, re-epithelization began in both groups, and there were no differences between groups. Re-epithelization was complete in both groups on day 12. **Conclusion:** We found no beneficial effect of boron in healing oral mucositis. Additional research is warranted to elucidate the pathogenic inflammatory mechanisms involved in mucositis and the prophylactic and therapeutic roles of antioxidants.

**Key words:** Antioxidant, boron, oncology, oral mucositis

## INTRODUCTION

Oral mucositis (OM) is a common complication of radiotherapy (RT) and chemotherapy (CT) in patients with cancer.<sup>[1]</sup> The incidence of OM varies according to the type of cancer and treatment modality. Use of 5-fluorouracil (5-FU) is one of the most common causes of OM. Grade 3-4 mucositis, which results in delay, dose reduction, or discontinuation of CT, occurs in more than 15% of cases during 5-FU administration.<sup>[2]</sup> OM is characterized by erythematous, erosive, and ulcerative lesions in the oral cavity. The severity of mucositis varies from lesions with few symptoms to severe ulcers and pain that result in lower quality of

life and/or death.<sup>[3]</sup> In addition, mucositis can have a significant economic impact because of increased hospitalization, use of opioids, and the requirement of parenteral or enteral nutrition.<sup>[4]</sup>

On the basis of recent evidence and an evolving understanding of molecular and cellular processes in mucositis, Sonis<sup>[5]</sup> proposed a theory for the pathogenesis of OM. This theory consists of multiple, interdependent biological processes involving multiple cell types and the extracellular matrix. According to this theory, the initial phase of mucositis consists of an inflammatory response to radiation and/or chemotherapy-induced generation of reactive oxygen species (ROS).

**How to cite this article:** Aras MH, Sezer U, Erkilic S, Demir T, Dagli SN. Effect of dietary boron on 5-fluorouracil induced oral mucositis in rats. *Eur J Dent* 2013;7:310-4.

Copyright © 2013 Dental Investigations Society.

DOI: 10.4103/1305-7456.115415

Many agents and strategies have been used to treat mucositis in patients receiving CT or RT. Treatment modalities have included oral mouthwashes, basic oral care, antibiotics, analgesics, local anesthetics, growth factors, cytokines, and biological mucosal protection.<sup>[6]</sup> However, none of these have proven highly effective, and there is no universally accepted protocol. Therefore, new treatment protocols are of great interest.

Boron is a mineral that is abundant in soil, air, and the surface water of oceans.<sup>[7]</sup> The most notable boron compounds are boric acid and borax. The major sources of human exposure to boron are diet (e.g., fruits, vegetables, and nuts) and water.<sup>[8]</sup> Dietary boron supplementation may have important effects on various metabolic and physiological systems. Some studies have demonstrated that boron compounds have nutritional benefits, such as increased vitamin D biosynthesis,<sup>[9]</sup> induction of hematopoiesis,<sup>[10]</sup> and stronger antioxidant defenses in animals and humans.<sup>[11]</sup> Boron limits oxidative damage by enhancing the body's store of glutathione and its derivatives, or by inducing other ROS-neutralizing agents.<sup>[12]</sup> The promising antioxidant effects displayed by boron in previous studies<sup>[13-15]</sup> suggest the potential for therapeutic benefit in chemotherapy-induced mucositis. Therefore, we hypothesized that boron would accelerate healing of mucositis induced by the chemotherapeutic drug 5-FU in a rat model.

## MATERIALS AND METHODS

Sixty-six male Wistar albino rats ranging 300-350 g were used. All animals were kept in individual stainless steel cages and acclimated for 5 days at a constant temperature and humidity. A 12-h light-dark cycle was maintained. The rats were pair-fed with standard chow and given free access to water. The Animal Ethics Committee of Gaziantep University School of Medicine approved the experimental procedure. At the beginning of the experiment, two of the rats were sacrificed to obtain excisional biopsies of normal cheek mucosa. All animals were intraperitoneally injected with 100 mg/kg of 5-FU on day 1 and 65 mg/kg of 5-FU on day 3. The right cheek pouch mucosa was scratched with the tip of an 18-G needle, dragged twice in a linear movement, on days 3 and 5. This technique has been used repeatedly to induce ulcerative mucositis, which is similar to human OM. The animals were anesthetized with xylazine hydrochloride (XylazineBio; 3 mg/kg) and ketamine

hydrochloride (Ketasol; 90 mg/kg) before these procedures were performed.<sup>[16]</sup> Rats were randomly divided into two groups of 32: boron group (BG) and control group (CG). The control rats did not receive any treatment. The others were fed 3 mg·kg<sup>-1</sup>·day<sup>-1</sup> boron (99.99% pure, in powder form; National Boron Institute of Turkey,) by gavage. The boron was prepared in distilled water. Boron dose was determined on the basis of a previous study<sup>[17]</sup> and constituted a supra-nutritional amount.

The beginning of the gavage was considered day 1 of the study after mucositis was induced. In the CG group, drinking water was administered by gavage. The animals were weighed daily and sacrificed on days 3 (*n* = 8), 6 (*n* = 8), 9 (*n* = 8), and 12 (*n* = 8), and the right cheek pouch was removed for histopathological analysis. All animals in the current study were sacrificed by cervical dislocation.

### Histological analysis

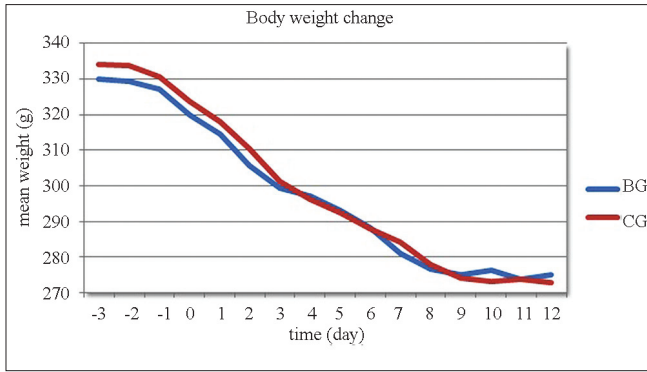
A single pathologist (S.E.) masked to group assignments performed histological analysis to determine the effect of boron on the course of mucositis. After the animals were sacrificed, mucosal specimens from wounds were collected and fixed by immersion in 10% formaldehyde for at least 24 h after these sections were obtained from the tissues. The specimens were placed in an automatic tissue processor and then embedded in paraffin to provide transverse sections of tissue. Five-micrometer sections were stained with hematoxylin and eosin. Stained sections were examined with an optical microscope. Histological evaluation was used to assess degree of inflammation, necrosis, granulation tissue, and re-epithelization. Healthy mucosa was also evaluated for comparison.

### Statistical analysis

Statistical analyses were conducted with SPSS 15.0.1 for Windows (SPSS, Inc., Chicago, IL, USA). Daily weight loss was analyzed with a 2-tailed *t* test. *P* < 0.05 were considered statistically significant.

## RESULTS

Before administration of 5-FU, all rats gained body weight, with no significant differences among groups (*P* > 0.05). After 5-FU administration, all rats, including those treated with boron, experienced significant weight loss (*P* > 0.05). This decrease in body weight continued over the remainder of the experimental period, with no significant differences between BG and CG [Figure 1].



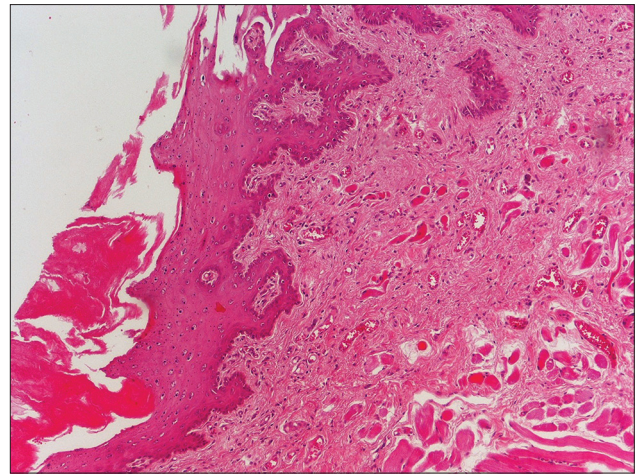
**Figure 1:** Distribution of the mean weight of animals throughout the experiment

As shown in Figure 2, the healthy rat mucosa had normal epithelium and connective tissue without inflammatory infiltration. On day 3, both groups showed necrosis and active inflammation, but inflammation was mild in CG and moderate in BG. On day 6, both BG and CG showed necrosis; in CG, there was moderate inflammation, and in the BG, there was severe inflammation and granulation tissue around the necrotic area. On day 9, re-epithelization began in both groups, and no difference was detected between groups. Re-epithelization was complete in both groups on day 12, and the histopathological appearance was similar [Figure 3].

## DISCUSSION

Chemotherapy-induced OM may lead to significant morbidity or discontinuation of treatment in cancer patients. An increasing number of studies are investigating different treatment modalities for mucositis, making this one of the most researched topics in the field of supportive cancer care. However, no effective intervention has been developed for the management of OM. In this study, we analyzed the effects of boron on wound healing in chemotherapy-induced OM in a rat model.

The experimental model used in the current study was the 5-FU-induced mucositis protocol developed by Sonis *et al.*,<sup>[18]</sup> which has been used by several investigators. This model has proven very useful in pre-clinical trials of new treatment options for mucositis. In the current study, abrasion of the buccal mucosa and 2 doses of 5-FU-induced mucositis and caused a reduction in body weight; this corroborates findings described in other studies.<sup>[19,20]</sup> Body weight reduction occurred in both groups, with no statistically significant differences between groups, as compared on days 3, 6, 9, and 12 ( $P > 0.05$ ). The similarity

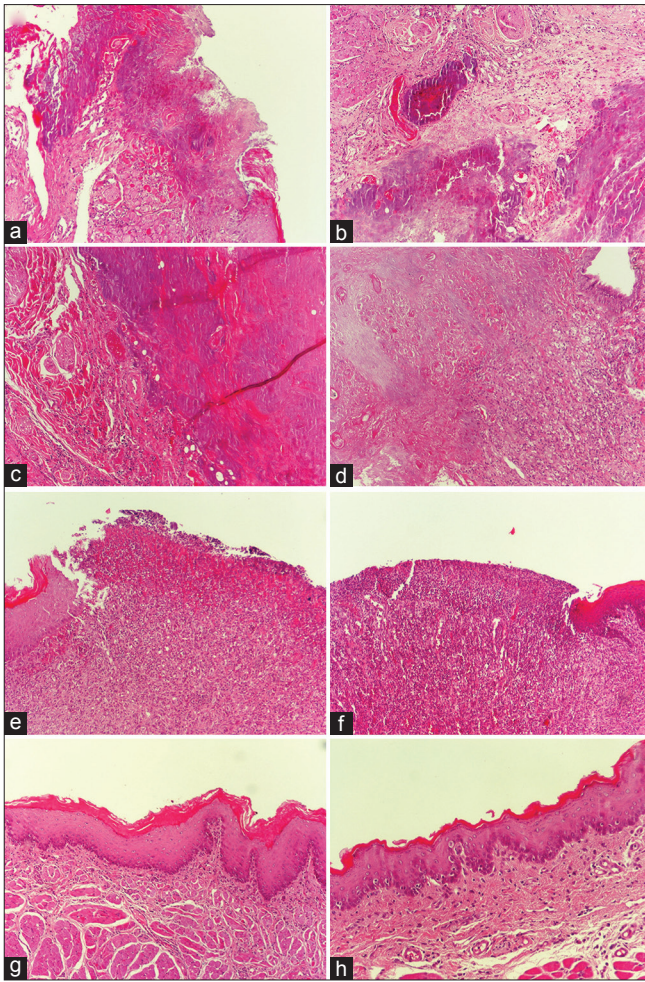


**Figure 2:** Histological view of healthy rat mucosa (H and E, x100)

between groups indicates that the boron dose we used in this study did not affect weight loss in rats. Doses of 5-FU used in different studies vary considerably. The present study used 100 mg/kg on day 1 and 65 mg/kg on day 3, following the protocol proposed by Franca *et al.*<sup>[20]</sup> The dose of boron used in the current study was determined based on the findings of Uysal *et al.*,<sup>[17]</sup> who reported a beneficial effect of boron on tissue regeneration. Apart from the boron, water and diet were not considered confounders, because both groups received the same water and diet. Therefore, the boron dose was supranutritional, meaning that our study evaluated the effect of supplementing a conventional diet with additional boron.

The pathogenesis of mucositis is not completely understood, but both direct and indirect mechanisms are known to be involved in mucositis. Agents used to treat cancer may cause epithelial atrophy, making tissue more susceptible to traumatic or spontaneous ulceration. Other factors, such as the endothelium, cytokines, and extracellular matrix, may also contribute to the pathogenesis of mucositis.<sup>[3,21]</sup> Therefore, mucositis appears to stem from a series of dynamic interactions as well as molecular and cellular events that involve all elements of the mucosa (epithelium and conjunctive tissue). The current classification describes five biological stages of mucositis: initiation, primary damage response, signal amplification, ulceration, and healing.<sup>[3]</sup> ROS are considered to play an important role in the inflammatory component of mucositis. 5-FU has been widely used to treat various types of cancer. It inhibits thymidylate synthase and both RNA and DNA synthesis, causing marked apoptosis.<sup>[22]</sup> Several anticancer agents, including 5-FU, have been shown to promote ROS generation in both normal tissue





**Figure 3:** Histopathological view of rat oral mucosa. (a) Control group on day 3; necrosis and mild inflammation. (b) Boron group on day 3; necrosis and moderate inflammation. (c) Control group on day 6; necrosis and moderate inflammation. (d) Boron group on day 6; severe inflammation and granulation tissue surrounding necrosis. (e) Control group and (f) boron group on day 9; re-epithelization has begun in both groups, and is no difference between groups. (g) Control group and (h) boron group on day 12; re-epithelization is complete in both groups and the histopathological appearance is similar (H and E, x100)

and cancer cells,<sup>[23,24]</sup> and overproduction of ROS is a major cause of mucosal injury.<sup>[25]</sup>

In the present study, boron had no significant effect on the healing process of mucositis. However, there were indications that the rate of recovery from mucositis could be improved. On day 3, inflammation was more intense in BG than in CG. On day 6, necrosis was observed in both BG and CG; CG had moderate inflammation, and BG had dense inflammation and granulation tissue around the necrotic area. However, on days 9 and 12, there was no difference between groups. It appears that the effect of boron declines as healing progresses and disappears by the time the mucosa has fully recovered. Antioxidants may affect the quantity of damaging ROS, which are generated in the first of five recognized

stages of mucositis.<sup>[2,3,26]</sup> Therefore, the effect of boron may not have been detected in the latter stages. In addition, antioxidants may play a protective role in the first stage of mucositis. Boron may be able to prevent rather than heal mucositis. In animal studies, boron has a more pronounced beneficial effect on bone<sup>[17,27,28]</sup> and mineral metabolism<sup>[9,29,30]</sup> than on soft tissues.<sup>[31,32]</sup> This may help explain the ineffectiveness of boron in healing mucositis.

## CONCLUSIONS

We found no beneficial effect of boron on the healing process of 5-FU-induced OM. Although a supranutritional dose of boron changed the nature of the healing process, it did not affect the eventual restoration of epithelial tissue. These findings should be interpreted with caution and in light of the limitations of the study. Indeed, the reason for publishing this limited study is not to provide a definitive conclusion, but to contribute to the knowledge of new therapeutic approaches for mucositis. Additional research is warranted to elucidate the pathogenic inflammatory mechanisms involved in mucositis and the prophylactic and therapeutic roles of antioxidants.

## REFERENCES

1. Sonis ST, Fey EG. Oral complications of cancer therapy. *Oncology (Williston Park)* 2002;16:680-6.
2. Sonis ST, Elting LS, Keefe D, Peterson DE, Schubert M, Hauer-Jensen M, *et al.* Perspectives on cancer therapy-induced mucosal injury: Pathogenesis, measurement, epidemiology, and consequences for patients. *Cancer* 2004;100:1995-2025.
3. Sonis ST. Pathobiology of mucositis. *Semin Oncol Nurs* 2004;20:11-5.
4. Elting LS, Cooksley C, Chambers M, Cantor SB, Manzullo E, Rubenstein EB. The burdens of cancer therapy. Clinical and economic outcomes of chemotherapy-induced mucositis. *Cancer* 2003;98:1531-9.
5. Sonis ST. The pathobiology of mucositis. *Nat Rev Cancer* 2004;4:277-84.
6. Worthington HV, Clarkson JE. Prevention of oral mucositis and oral candidiasis for patients with cancer treated with chemotherapy: Cochrane systematic review. *J Dent Educ* 2002;66:903-11.
7. Woods WG. An introduction to boron: History, sources, uses, and chemistry. *Environ Health Perspect* 1994;102 Suppl 7:5-11.
8. Rainey C, Nyquist L. Multicountry estimation of dietary boron intake. *Biol Trace Elem Res* 1998;66:79-86.
9. Hunt CD. The biochemical effects of physiologic amounts of dietary boron in animal nutrition models. *Environ Health Perspect* 1994;102 Suppl 7:35-43.
10. Nielsen FH, Hunt CD, Mullen LM, Hunt JR. Effect of dietary boron on mineral, estrogen, and testosterone metabolism in postmenopausal women. *FASEB J* 1987;1:394-7.
11. Pawa S, Ali S. Boron ameliorates fulminant hepatic failure by counteracting the changes associated with the oxidative stress. *Chem Biol Interact* 2006;160:89-98.
12. Cao J, Jiang L, Zhang X, Yao X, Geng C, Xue X, *et al.* Boric acid inhibits LPS-induced TNF-alpha formation through a thiol-dependent mechanism in THP-1 cells. *J Trace Elem Med Biol* 2008;22:189-95.
13. Scorei IR. Calcium fructoborate: plant-based dietary boron as potential medicine for cancer therapy. *Front Biosci (Schol Ed)* 2011;3:205-15.
14. Turkez H, Geyikoglu F, Tatar A, Keles MS, Kaplan I. The effects of some boron compounds against heavy metal toxicity in human blood. *Exp Toxicol Pathol* 2012;64:93-101.

15. Demirer S, Kara MI, Erciyas K, Ozdemir H, Ozer H, Ay S. Effects of boric acid on experimental periodontitis and alveolar bone loss in rats. *Arch Oral Biol* 2012;57:60-5.
16. Lara RN, da Guerra EN, de Melo NS. Macroscopic and microscopic effects of GaAIs diode laser and dexamethasone therapies on oral mucositis induced by fluorouracil in rats. *Oral Health Prev Dent* 2007;5:63-71.
17. Uysal T, Ustidal A, Sonmez MF, Ozturk F. Stimulation of bone formation by dietary boron in an orthopedically expanded suture in rabbits. *Angle Orthod* 2009;79:984-90.
18. Sonis ST, Tracey C, Shklar G, Jensen J, Florine D. An animal model for mucositis induced by cancer chemotherapy. *Oral Surg Oral Med Oral Pathol* 1990;69:437-43.
19. Leitao RF, Ribeiro RA, Bellaguarda EA, Macedo FD, Silva LR, Oria RB, *et al.* Role of nitric oxide on pathogenesis of 5-fluorouracil induced experimental oral mucositis in hamster. *Cancer Chemother Pharmacol* 2007;59:603-12.
20. Franca CM, Nunez SC, Prates RA, Noborikawa E, Faria MR, Ribeiro MS. Low-intensity red laser on the prevention and treatment of induced-oral mucositis in hamsters. *J Photochem Photobiol B* 2009;94:25-31.
21. Scully C, Epstein J, Sonis S. Oral mucositis: A challenging complication of radiotherapy, chemotherapy, and radiochemotherapy: Part 1, pathogenesis and prophylaxis of mucositis. *Head Neck* 2003;25:1057-70.
22. Pritchard DM, Watson AJ, Potten CS, Jackman AL, Hickman JA. Inhibition by uridine but not thymidine of p53-dependent intestinal apoptosis initiated by 5-fluorouracil: Evidence for the involvement of RNA perturbation. *Proc Natl Acad Sci U S A* 1997;94:1795-9.
23. Chen Y, Jungsuwadee P, Vore M, Butterfield DA, St Clair DK. Collateral damage in cancer chemotherapy: Oxidative stress in nontargeted tissues. *Mol Interv* 2007;7:147-56.
24. Alexandre J, Hu Y, Lu W, Pelicano H, Huang P. Novel action of paclitaxel against cancer cells: Bystander effect mediated by reactive oxygen species. *Cancer Res* 2007;67:3512-7.
25. Shiota A, Hada T, Baba T, Sato M, Yamanaka-Okumura H, Yamamoto H, *et al.* Protective effects of glycolipids extracted from spinach on 5-fluorouracil induced intestinal mucosal injury. *J Med Invest* 2010;57:314-20.
26. Logan RM, Stringer AM, Bowen JM, Yeoh AS, Gibson RJ, Sonis ST, *et al.* The role of pro-inflammatory cytokines in cancer treatment-induced alimentary tract mucositis: Pathobiology, animal models and cytotoxic drugs. *Cancer Treat Rev* 2007;33:448-60.
27. Ying X, Cheng S, Wang W, Lin Z, Chen Q, Zhang W, *et al.* Effect of boron on osteogenic differentiation of human bone marrow stromal cells. *Biol Trace Elem Res* 2011;144:306-15.
28. Gorustovich AA, Steimetz T, Nielsen FH, Guglielmotti MB. Histomorphometric study of alveolar bone healing in rats fed a boron-deficient diet. *Anat Rec (Hoboken)* 2008;291:441-7.
29. Hakki SS, Bozkurt BS, Hakki EE. Boron regulates mineralized tissue-associated proteins in osteoblasts (MC3T3-E1). *J Trace Elem Med Biol* 2010;24:243-50.
30. Nielsen FH, Penland JG. Boron deprivation alters rat behaviour and brain mineral composition differently when fish oil instead of safflower oil is the diet fat source. *Nutr Neurosci* 2006;9:105-12.
31. Benderdour M, Van Bui T, Hess K, Dicko A, Belleville F, Dousset B. Effects of boron derivatives on extracellular matrix formation. *J Trace Elem Med Biol* 2000;14:168-73.
32. Blech MF, Martin C, Borrelly J, Hartemann P. Treatment of deep wounds with loss of tissue. Value of a 3 percent boric acid solution. *Presse Med* 1990;19:1050-2.

Access this article online

Quick Response Code:



Website:

[www.eurjdent.com](http://www.eurjdent.com)

**Source of Support:** This study was supported by a grant 2010-Ç0277 from the Research Fund, National Boron Institute, Turkey.

**Conflict of Interest:** None declared