

Is the 810-nm diode laser the best choice in oral soft tissue therapy?

Nihat Akbulut¹, E. Sebnem Kursun², M. Kemal Tumer³, Kivanc Kamburoglu², Ugur Gulsen⁴

Correspondence: Dr. Nihat Akbulut
Email: drnihatakbulut@yahoo.com

¹Department of Oral and Maxillofacial Surgery, Faculty of Dentistry, University of Gaziosmanpasa, Tokat, Turkiye,

²Departments of Oral and Maxillofacial Radiology, Faculty of Dentistry, University of Ankara, Ankara, Turkiye,

³Department of Oral and Maxillofacial Surgery, Faculty of Dentistry, University of Gazi, Ankara, Turkiye,

⁴Department of Oral and Maxillofacial Surgery, Faculty of Dentistry, University of Ankara, Ankara, Turkiye

ABSTRACT

Objective: To evaluate the safety and efficacy of an 810-nm diode laser for treatment of benign oral soft tissue lesions. **Materials and Methods:** Treatment with the 810-nm diode laser was applied to a group of eighteen patients with pathological frenulum and epulis fissuratum; five patients with oral lichen planus, oral leukoplakia, and mucous membrane pemphigoid; and four patients with pyogenic granuloma. **Results:** Although the conventional surgery wound heals in a fairly short time, in the present study, the simple oral soft tissue lesions healed within two weeks, the white and vesiculobullous lesions healed completely within six weeks, and the pyogenic granuloma lesions healed within four weeks. Any complication was treated by using the 810-nm diode laser. **Conclusions:** Patient acceptance and satisfaction, without compromising health and function, have been found to be of a high degree in this present study. Thus, we can say that the use of the 810-nm diode laser may indeed be the best choice in oral soft tissue surgery.

Key words: Diode laser, oral soft tissue lesions, oral surgery, white lesions

INTRODUCTION

Innovative technologies, such as diode lasers, have provided considerable benefit to dental patients and dentists.^[1,2] In addition, the role of lasers in dentistry is well-established in both the conservative and surgical management of oral diseases.^[2-4]

The diode laser is a semiconductor that uses solid-state elements, such as gallium, arsenide, aluminum, and indium, to change electrical energy into light energy. The light energy from the diode is greatly absorbed by the soft tissue and poorly absorbed by the teeth and bones.^[5]

Diode lasers are useful for oral soft tissue surgical

procedures because their specific wavelength (810-980 nm) is absorbed not only by water (although less so than the carbon dioxide laser wavelength), but also by other chromophores, such as melanin, and in particular, oxyhemoglobin. Moreover, the exclusive use of this laser by contact or at an extremely close distance avoids damage, due to 'beam escape,' in an open field, which makes it much safer than other laser sources. In addition, diode lasers have the ability to cut the tissue to perform coagulation and hemostasis, and have a higher tissue ablation capacity and enough bleeding hemostatic properties compared to most laser systems.^[1,4,6]

Clinical experience suggests some advantages of the laser over scalpel surgical procedures on oral

How to cite this article: Akbulut N, Kursun ES, Tumer MK, Kamburoglu K, Gulsen U. Is the 810-nm diode laser the best choice in oral soft tissue therapy?. *Eur J Dent* 2013;7:207-11.

Copyright © 2013 Dental Investigations Society.

DOI: 10.4103/1305-7456.110174

tissues. These advantages include greater precision, a relatively bloodless surgical and postsurgical course, sterilization of the surgical area, minimal swelling and scarring, coagulation, vaporization, cutting, minimal or no suturing, and less or no postsurgical pain.^[7,8]

Studies have shown that laser surgery is widely used for oral lesions, such as, simple soft tissue surgery (frenectomy, epulis, gingival contouring plasty, etc.),^[1-3,5,7] vascular lesions (hemangiomas, telangiectasias, etc.),^[4,6] pigmented lesions (gingival pigmentations),^[1] white oral lesions (oral leukoplakia, oral lichen planus, etc.),^[9,10] and low-level laser therapy (LLLT) in vesiculobullous lesions (mucous membrane pemphigoid).^[7]

The purpose of this study is to determine the efficacy and safety of the 810-nm diode laser for treatment of oral soft tissue lesions or diseases, and to answer the question of whether the 810-nm diode laser is the best choice in oral soft tissue surgery.

MATERIALS AND METHODS

A total of 27 patients who had different benign oral lesions were treated with the 810-nm diode laser at the Oral and Maxillofacial Surgery Department, Faculty of Dentistry, Ankara University, between the years 2009 and 2011. An informed written consent form was obtained from all participating adults and from parents or legal guardians for minors or incapacitated adults (19 females and eight males, 10 smokers and 17 nonsmokers, 21 to 72 years of age) in accordance with the Declaration of Helsinki. All patients had previously taken conventional medical treatment procedures (local corticosteroid, beta carotene, vitamin E, fluocinonide, triamcinolone, LLLT, etc.) except the patients having epulis fissuratum or pathological frenulum. Unfortunately, the lesions in all patients reoccurred. Therefore, the diode laser treatment was selected as an alternative treatment option for these patients.

The cases have been studied retrospectively. Patients with any systemic diseases were excluded from the study, and all operations were performed by the same surgical team.

The diagnosis of all lesions or disorders was confirmed by histopathological examination, especially in patients who suffered from white, vesiculobullous, and pyogenic granuloma lesions. All treatments were performed with the patients under local anesthesia

and on an outpatient basis. Both the patients and the surgeons wore protective glasses.

Treatment was carried out using 12 different settings of the MedArt 426 Diode Laser System (Asah Medico A/S, Hvidovre, Denmark). The laser output power ranged from 0, 5-30 W, the pulse rate from 10-1000 msec in a pulsed mode, and the frequency from 0, 3-100 Hz. The laser could also be operated in a continuous wave (cw) mode, as was done during the procedure. The target beam was generated by an aluminum, arsenide, and gallium laser (810 - nm). The laser beam was delivered by ultrathin optical fibers of 400-1000 μm , enabling it to be moved easily and quickly during surgical procedures.

Simple oral soft tissue surgery

Eighteen patients (10 epulis fissuratum [Figure 1a] and eight labial frenectomy) were treated with the diode laser. The treatment was carried out by moving a slightly focused 810-nm diode laser. The laser had an output power of 5-10 W, high-power continuous wavelength, and a spot size of 2 mm. The surgical operation was performed using the excision method under local anesthesia [Figure 1b].

Treatment of oral white and vesiculobullous lesions

Five patients with histologically proven disorders, including two with leukoplakia [Figure 2a], two with oral lichen planus [Figure 3a], and one with oral mucous membrane pemphigoid, were selected for 810-nm diode laser treatment. They had been treated with different drugs (fluocinonide, triamcinolone, LLLT) or a wait-and-see policy before the 810-nm diode laser evaporation. All patients, who had had recurring lesions or bad results with their previous treatment options, were prepared for laser surgery treatment. A defocused 810-nm diode laser was chosen for evaporation of the superficial mucosal lesions [Figure 2b, 3b]. The laser had an output power of 10-15 W, high-power continuous wavelength and 2-mm spot size.

Pyogenic granuloma

Four patients with pyogenic granuloma, diagnosed

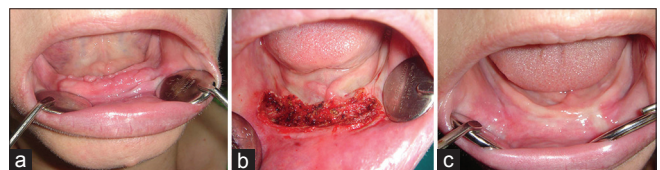

Figure 1: (a) Preoperative view of the epulis fissuratum lesion of a patient, (b) immediate postoperative view of the treated area, (c) view of the treated area two weeks after diode laser intervention

clinically, were treated with a diode laser, with an output power of 10-15 W, high-power continuous wavelength, and 2-mm spot size. First, the lesions were excised with a focused 810-nm diode laser under local anesthesia and then the surgical material was sent for histopathological study. Immediately, the surgical field was evaporated with a defocused 810 nm diode laser. The histopathological study confirmed the clinical diagnosis.

In all the 27 patients treated, the areas surrounding the treated tissue were cooled after the laser surgical procedure. All the patients were given suitable postoperative care such as 0.2% chlorhexidine mouthwash, and paracetamol analgesics were prescribed. All patients were seen on a regular basis for follow-up: At one, two, and six weeks, and two months after treatment.

RESULTS

The study included 27 patients treated with 810-nm diode laser settings [Table 1], including 10 with epulis fissuratum, eight with labial frenectomy, two with leukoplakia, two with oral lichen planus, one with mucous membrane pemphigoid lesion, and four with pyogenic granuloma.

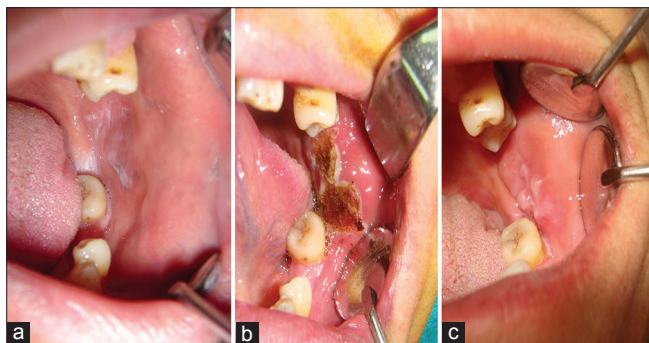


Figure 2: (a) Immediate preoperative view of the treated area of a leukoplakia patient, (b) immediate postoperative view of the treated area, (c) view of the treated area six weeks after diode laser intervention

At the two-week follow-up, the simple oral soft tissue surgery patients had healed without scarring or any other complications, such as hemorrhage [Figure 1c].

At the six-week follow-up, the patients with oral white and vesiculobullous lesions had healed without scarring [Figure 2c, 3c]. No charring or carbonization occurred during the procedure [Figure 2b, 3b]. Unfortunately, the patient with mucous membrane pemphigoid disorder had moderate bleeding intraoperatively and postoperatively, which was stopped by suturing the bleeding region.

At the four-week follow-up, the patients with pyogenic granuloma lesions had healed without scarring or any other complications, such as hemorrhage. No charring or carbonization occurred during the procedure.

In all cases, there were no incidents of infection in the days following the procedure. No sutures were required except for one patient. All the patients were satisfied with the treatment and the results obtained. They were comfortable and experienced no pain, either intraoperatively or postoperatively.

DISCUSSION

In our study, we have evaluated the effects of the 810-nm diode laser in the treatment of 27 patients with various benign oral soft tissue lesions. Diode,

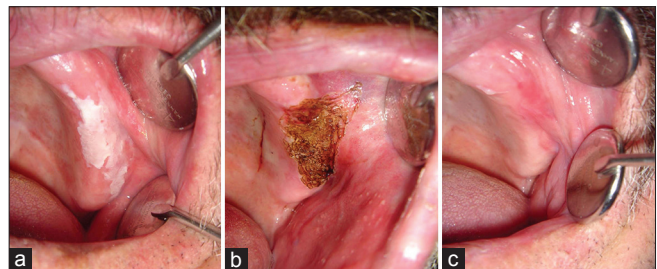


Figure 3: (a) Preoperative view of a lichen planus lesion, (b) postoperative view of the treated lesion, (c) view of the healed lesion after six weeks laser treatment

Table 1: Descriptive information on the 810-nm diode laser treatment							
Measure	Number of patients	Application from	Power output (W)	Diagnosis	Treatment option (Excision/Evaporation)	Bleeding (Yes/No)	Healing time (week)
Simple oral soft tissue surgery patients	18	Focused mode	5-10	Clinically	Excision	No	2
Oral white and vesiculobullous lesion treatment	5	Defocused mode	10-15	Clinical and histopathological confirmation	Evaporation	No, except one patient	6
Pyogenic granuloma patients	4	Focused and defocused mode	10-15	Clinical and histopathological confirmation	Excision and evaporation	No	4

neodymium, erbium, and CO₂ lasers are approved by the Food and Drug Administration (FDA) for use in oral surgery.^[11] The use of lasers in a variety of surgical procedures has been well documented. Diode lasers present a solid semiconductor as an active medium, by associating aluminum, gallium, and arsenate (with wavelengths varying between 800 and 980 nm) in the visible and invisible range of near infrared waves. As its wavelength is poorly absorbed by the hard dental tissue, the diode laser is safe and well indicated for soft oral tissue surgeries in regions near the dental structures and for cutting, vaporization, curettage, blood coagulation, and hemostasis in the oral region.^[11,12] Some authors, such as Goharkhay *et al.*^[7] and Gontijo *et al.*,^[11] have reported success in the treatment of oral soft tissue lesions using a diode laser.

In our study, an 810-nm diode laser was used surgically for safe elimination of soft oral tissue lesions; no complications occurred in the surrounding soft tissue or hard tissue. We adopted the 810-nm diode laser for our patients due to its availability, the convenience of its application, the ability for large areas to be treated in a single application, and the possibility of precise control of laser fluence in all areas of the mouth. This pattern, especially of producing precise surgical incisions, was in accordance with those observed by Genovese *et al.*^[4] and D'Arcangelo *et al.*^[13] Alongside all this, Aras *et al.*^[5] compared diode laser with the Er: YAG laser revealed that Er: YAG laser was more comfortable because of the lower local-anesthesia requirement.

Soft tissue procedures cause postsurgical pain and discomfort when chewing, eating, breathing, and speaking.^[5] Aras *et al.*^[5] has reported that on evaluating the patients for pain during the first three hours after surgery, those in the Er: YAG laser group had a higher degree of pain than those in the diode laser group. Kara^[14] has suggested that Ne: YAG laser frenulectomy provides better patient perception of success than that seen with conventional surgery. However, in our study, we have not encountered any reports of pain from the patients.

According to the literature, the mainstay treatment for oral lichen planus is topical steroids. In oral lichen planus cases where topical approaches have failed, systemic corticosteroids can be considered. Several studies^[10,15,16] have shown good results with this treatment, but side effects have also been reported. In our study the white lesions, especially oral lichen planus, were initially treated with the conventional

therapy mentioned above. When we did not obtain a definite result from this treatment option, we decided to apply the 810-nm diode laser to our patients in order to obtain acceptable results.

Initially, clinicians treated oral leukoplakia with vitamin A, vitamin E, and beta-carotene. However, because of the toxicity of vitamin A and the unsatisfactory response to vitamin E and beta-carotene, the use of these drugs for the treatment of oral leukoplakia has been discontinued.^[9,17] The other treatment modalities for oral leukoplakia are scalpel excision or electrocautery and cryosurgery, for which there is a recurrence rate of approximately 33%.^[9,18] Studies^[9,19] on the clinical usefulness of laser surgery in oral leukoplakia have shown that the laser surgery prevents not only recurrence and malignant transformation, but also postoperative dysfunction. In our study, we used 810-nm high-power laser surgery to treat these lesions and obtained excellent results.

Mucous membrane pemphigoid (MMP) is a rare chronic disorder of the mucosal tissue manifested largely by vesicubullous lesions of the oral cavity and eyes.^[20,21] Additionally, MMP most often involves the oral cavity followed by the conjunctiva and genitalia. The clinical manifestations of mucous membrane pemphigoid are varied, but the oral and conjunctival mucosae are most frequently involved. The condition is also commonly termed as cicatricial pemphigoid, but the term cicatricial later excluded patients without scarring.^[20] Conjunctival involvement occurs in up to 75% of the patients.^[21] However, one patient in our study had no lesion with conjunctival mucosa involvement. Immunosuppressive therapy is the mainstay treatment for MMP. Surgery has a diagnostic approach to the lesions, such as, stenosis and airway obstruction.

Whiteside *et al.*^[21] treated supraglottic airway stenosis with the CO₂ laser and had good results. First, our patient with an MMP lesion on the left side of her tongue had taken conventional therapy, such as, topical corticosteroids, tetracyclin, LLLT, and some immunosuppressive adjuvants; unfortunately, these did not yield good results. Thus, we chose diode laser excision as the treatment option. We had a moderate bleeding complication intraoperatively and postoperatively, but the lesion healed completely within six weeks. The patient was satisfied with this treatment option.

Pyogenic granuloma is a frequently diagnosed, benign vascular lesion. The possible treatment methods are excision, curettage, cryotherapy, chemical and electric cauterization, and the use of lasers.^[22-26] Surgical excision or electrocoagulation is considered the standard treatment for pyogenic granuloma. However, because of scarring, excision is a suboptimal form of therapy; bleeding can also complicate the operation process, especially in huge granulomas or if the excision is close to the lesion. Laser excision may be the ideal treatment option for these type of lesions.^[23,24] For our pyogenic granuloma patients, the selected treatment option of 810-nm diode laser excision resulted in completely healed lesions.

CONCLUSION

The use of lasers, especially diode lasers, in general dentistry is now an accepted treatment aid, with a wide range of applications in oral soft tissue surgery. We also see that the use of the 810-nm diode laser as the treatment of choice for oral soft tissue therapy is reliable because we obtained acceptable healing of the lesions with minimal adverse effect. Thus, in oral soft tissue surgery, the use of 810-nm diode lasers may be the best choice.

REFERENCES

- Desiate A, Cantore S, Tullo D, Profeta G, Grassi FR, Ballini A. 980 nm diode lasers in oral and facial practice: Current state of the science and art. *Int J Med Sci* 2009;6:358-64.
- Kafas P, Stavrianos C, Jerjes W, Upile T, Vourvachis M, Theodoridis M, et al. Upper-lip laser frenectomy without infiltrated anaesthesia in a paediatric patient: A case report. *Cases J* 2009;2:7138.
- Ishikawa I, Aoki A, Takasaki AA. Clinical application of erbium: YAG laser in periodontology. *J Int Acad Periodontol* 2008;10:22-30.
- Genovese WJ, dos Santos MT, Faloppa F, de Souza Merli LA. The use of surgical diode laser in oral hemangioma: A case report. *Photomed Laser Surg* 2010;28:147-51.
- Aras MH, Göregen M, Güngörmüş M, Akgül HM. Comparison of diode laser and Er: YAG lasers in the treatment of ankyloglossia. *Photomed Laser Surg* 2010;28:173-7.
- Saetti R, Silvestrini M, Cutrone C, Narne S. Treatment of congenital subglottic hemangiomas: Our experience compared with reports in the literature. *Arch Otolaryngol Head Neck Surg* 2008;134:848-51.
- Goharkhay K, Moritz A, Wilder-Smith P, Schoop U, Kluger W, Jakolitsch S, et al. Effects on oral soft tissue produced by a diode laser *in vitro*. *Lasers Surg Med* 1999;25:401-6.
- Pick RM, Colvard MD. Current status of lasers in soft tissue dental surgery. *J Periodontol* 1993;64:589-602.
- Vivek V, Jayasree RS, Balan A, Sreelatha KT, Gupta AK. Three-year follow-up of oral leukoplakia after neodymium: Yttrium aluminum garnet (Nd: YAG) laser surgery. *Lasers Med Sci* 2008;23:375-9.
- van der Hem PS, Egges M, van der Wal JE, Roodenburg JL. CO₂ laser evaporation of oral lichen planus. *Int J Oral Maxillofac Surg* 2008;37:630-3.
- Gontijo I, Navarro RS, Haypek P, Ciamponi AL, Haddad AE. The applications of diode and Er: YAG lasers in labial frenectomy in infant patients. *J Dent Child* 2005;72:10-5.
- Strauss RA, Fallon SD. Lasers in contemporary oral and maxillofacial surgery. *Dent Clin North Am* 2004;48:861-88.
- D'Arcangelo C, Di Nardo Di Maio F, Proserpi GD, Conte E, Baldi M, Caputi S. A preliminary study of healing of diode laser versus scalpel incisions in rat oral tissue: A comparison of clinical, histological, and immunohistochemical results. *Oral Surg Oral Med Oral Pathol Oral Radiol Endod* 2007;103:764-73.
- Kara C. Evaluation of patient perceptions of frenectomy: A comparison of Nd: YAG laser and conventional techniques. *Photomed Laser Surg* 2008;26:147-52.
- Carbone M, Gross E, Carozzo M, Castellano S, Conrotto D, Brocoletti R, et al. Systemic and topical corticosteroids treatment of oral lichen planus: A comparative study with long-term follow up. *J Oral Pathol Med* 2003;32:323-9.
- Buajeeb W, Poburksa C, Kraiva-Phan P. Efficacy of fluocinonide acetamide gel in the treatment of oral lichen planus. *Oral Surg Oral Med Oral Pathol* 2000;89:42-45.
- Epstein JB, Gorsky M. Topical application of vitamin A to oral leukoplakia: A clinical case series. *Cancer* 2000;86:921-7.
- Saito T, Sugiura C, Hirai A, Notani K, Totsuka Y, Shindoh M, et al. Development of squamous cell carcinoma from pre-existent oral leukoplakia: With respect to treatment modality. *Int J Oral Maxillofac Surg* 2001;30:49-53.
- Ishi J, Fujita K, Munemoto S, Komori T. Management of oral leukoplakia by laser surgery: Relation between recurrence and malignant transformation and clinicopathological features. *J Clin Laser Med Surg* 2004;22:27-33.
- Whiteside OJ, Martinez Devesa P, Ali I, Capper JW. Mucous membrane pemphigoid; nasal and laryngeal manifestations. *J Laryngol Otol* 2003;117:885-8.
- Silverman S Jr, Gorsky M, Lozada-Nur F, Liu A. Oral mucous membrane pemphigoid. A study of sixty-five patients. *Oral Surg Oral Med Oral Pathol* 1986;61:233-7.
- Chan LS, Ahmed AR, Anhalt GJ, Bernauer W, Cooper KD, Elder MJ, et al. The first international consensus on mucous membrane pemphigoid: Definition, diagnostic criteria, pathogenic factors, medical treatment, and prognostic indicators. *Arch Dermatol* 2000;138:370-9.
- Raulin C, Greve B, Hammes S. The combined continuous-wave/pulsed carbon dioxide laser for treatment of pyogenic granuloma. *Arch Dermatol* 2002;138:33-7.
- Powell JL, Bailey CL, Coopland AT, Otis CN, Frank JL, Meyer I. Nd: YAG laser excision of giant gingival pyogenic granuloma of pregnancy. *Lasers Surg Med* 1994;14:178-183.
- Glass AT, Milgraum S. Flashlamp-pumped pulsed dye laser treatment for pyogenic granuloma. *Cutis* 1992;49:351-353.
- Goldberg DJ, Sciales CW. Pyogenic granuloma in children: Treatment with the flashlamp-pumped pulsed dye laser. *J Dermatol Surg Oncol* 1991;17:960-962.

Access this article online	
Quick Response Code: 	Website: www.eurjdent.com
Source of Support: Nil. Conflict of Interest: None declared	